



A Second Case Report of Organizing Pneumonia following Ocrelizumab use in Patient with Multiple Sclerosis

Dr. Giuseppe La Mattina ¹, Dr. Giorgio La Spina ¹, Dr. Michele Gallo* ¹, Dr. Alessandro Migliore ²,
Dr. Giuseppe Adamo ², Dr. Valeria Greco ¹, Dr. Giuseppe Arcoleo ¹

1. Division of Interventional Pulmonology, AOOR Villa Sofia-Cervello, Villa Sofia Hospital, Palermo, Italy.

2. Division of Pulmonology, AOOR Villa Sofia-Cervello, V. Cervello Hospital, Palermo, Italy

***Correspondence to:** Dr. Michele Gallo, Division of Interventional Pulmonology, AOOR Villa Sofia-Cervello, Villa Sofia Hospital, Palermo, Italy.

Copyright

© 2023 **Dr. Michele Gallo**. This is an open access article distributed under the Creative Commons Attribution License, which permits unrestricted use, distribution, and reproduction in any medium, provided the original work is properly cited.

Received: 03 November 2023

Published: 16 November 2023

Abstract

Ocrelizumab is an intravenously administered, humanized anti-CD20 monoclonal antibody approved for the treatment of adults with relapsing forms of multiple sclerosis or primary progressive multiple sclerosis. In the literature there are lack of data on Ocrelizumab-associated lung involvement, a single case was published in 2023. [1] We present a second case of organizing pneumonia in a 50-years old female patient with multiple sclerosis during Ocrelizumab treatment.

Introduction

Ocrelizumab is a humanized anti-CD-20 monoclonal antibody used for relapsing and primary progressive forms of multiple sclerosis. [2] . It was approved by the Food and Drug Administration (FDA) in March 2017. Anti-CD-20 antibody such as rituximab has been reported to induce a heterogeneous spectrum of lung disorders [3]. Nevertheless, there is limited data concerning the impact of the relatively new anti-CD-20 agent, ocrelizumab, on the respiratory system. The first case was published this year. [4] We present a 50-years old female case of organizing pneumonia related to ocrelizumab use confirmed by histopathology with trans bronchial biopsy.

Case Report

A 50-year-old woman was admitted to the emergency department in September 2023 for persistent fever that had started approximately 10 days earlier (with a maximum body temperature of 39.5°C), unresponsive to antibiotic therapy with amoxicillin/clavulanate. In her past medical history, the patient had a history of smoking (former smoker for about 10 years), dyslipidemia being treated with rosuvastatin, and a diagnosis of multiple sclerosis since 2019, treated with Ocrelizumab administered every six months, with the last dose being given in the previous July 2023. During her stay in the Infectious Diseases department at the local hospital, a total body CT scan was performed, which showed the presence of multiple areas of lung consolidation, some of which appeared to be ground glass opacities, mixed with areas of parenchymal consolidation at the lung bases (figure 1). She was then administered antimicrobial therapy with intravenous Linezolid and liposomal amphotericin B. However, due to the persistence of symptoms, she was subsequently

transferred to our Department. Upon admission to the ward, the patient appeared in fair general condition, with fever (maximum body temperature of 39°C), chills and sweating. A blood gas analysis on room air (FiO₂ 0.21) was performed (pH 7.50, pCO₂ 40 mmHg, pO₂ 65 mmHg, lactate 1 mmol/l, HCO₃⁻ 31.2 mmol/l, SO₂ 94%). Laboratory tests revealed the following values: PCT 0.19 ng/ml, CRP 0.88 mg/dl, hemoglobin 10.3 g/dl, WBC 4000 cells/mm³, Neutrophils (Neu) 70.4%, Lymphocytes (Ly) 15.8%, Monocytes (Mono) 13.1%, Eosinophils (Eo) 0.3%, Basophils (Ba) 0.4%. During her hospitalization, a thorough evaluation was conducted to determine a possible infectious origin, including blood cultures, urinary antigen tests for *L. pneumophila* and *S. pneumoniae*, urine cultures, serum testing for atypical bacteria and major and minor hepatotropic viruses, Quantiferon TB Gold, and enzyme-linked immunosorbent assay (ELISA) for HIV, all of which returned negative results. Additionally, an echocardiogram was performed, which did not reveal any valvular vegetations. An autoantibody profile was also obtained, all results were negative.

During her hospital stay, the patient initially received empiric antibiotic therapy with intravenous Meropenem and Vancomycin. Subsequently, due to the isolation of *K. Pneumoniae* from a bronchoalveolar lavage sample, the therapy was changed to ceftazidime/avibactam. Due to lung consolidation, the patient developed partial acute respiratory failure, which was treated with low-flow oxygen therapy. Considering the clinical, laboratory, and radiological findings, as well as the poor response to the initiated antibiotic therapy, the patient underwent an ecoguided fibrobronchoscopy with radial probe (R-EBUS) and multiple transbronchial biopsies in the anterior segment of the left upper lobe (LB3). Histological examination of the biopsy specimen revealed a pattern of 'bronchial mucosa lined with pseudo-stratified respiratory epithelium with features of basal hyperplasia, lamina propria characterized by edema and fibrosis, with mild to moderate lympho-granulocytic inflammatory infiltrate. Lung parenchyma showed interstitial expansion due to increased cellularity consisting of lymphomonocytic elements, macrophages, and granulocytes; hyperplastic cuboidal pneumocytes and focal presence of Masson bodies with features of organizing pneumonia. Based on the histopathological findings, the patient was treated for organizing pneumonia with Prednisone 25 mg twice daily. Due to refractoriness to steroid therapy, Azathioprine was subsequently added, resulting in the patient's defervescence. A chest CT scan performed two weeks after admission showed improvement in the radiological findings, with a reduction in the extent of the known lung consolidations (figure 2). The patient was finally discharged on October 2023 with complete resolution of clinical symptoms, afebrile, and no longer experiencing respiratory failure.

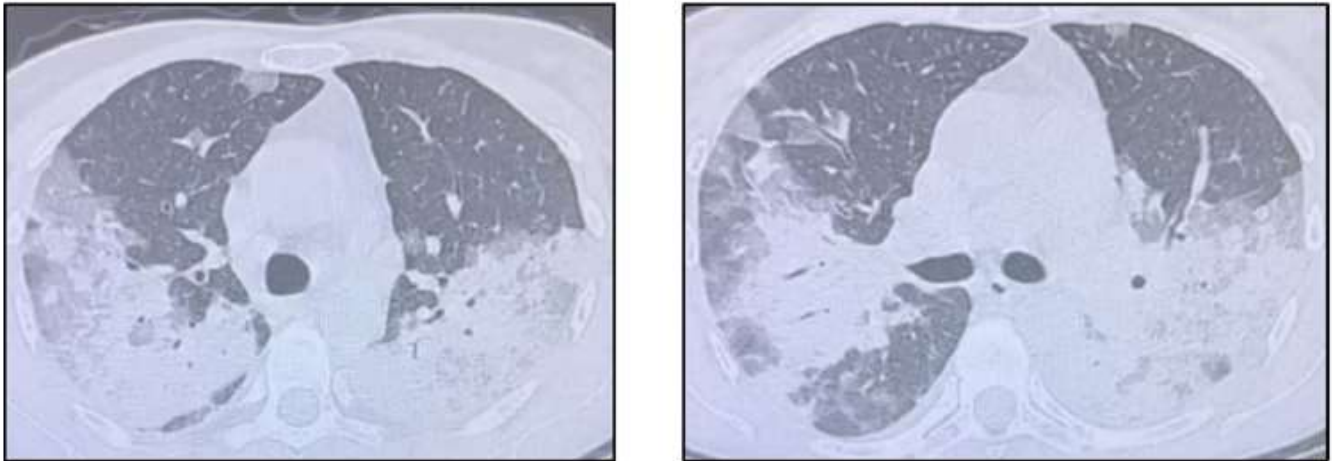


Figure 1: CT-scan at hospital admission: presence of multiple areas of ground glass opacity mixed with areas of parenchymal consolidation at the lung bases

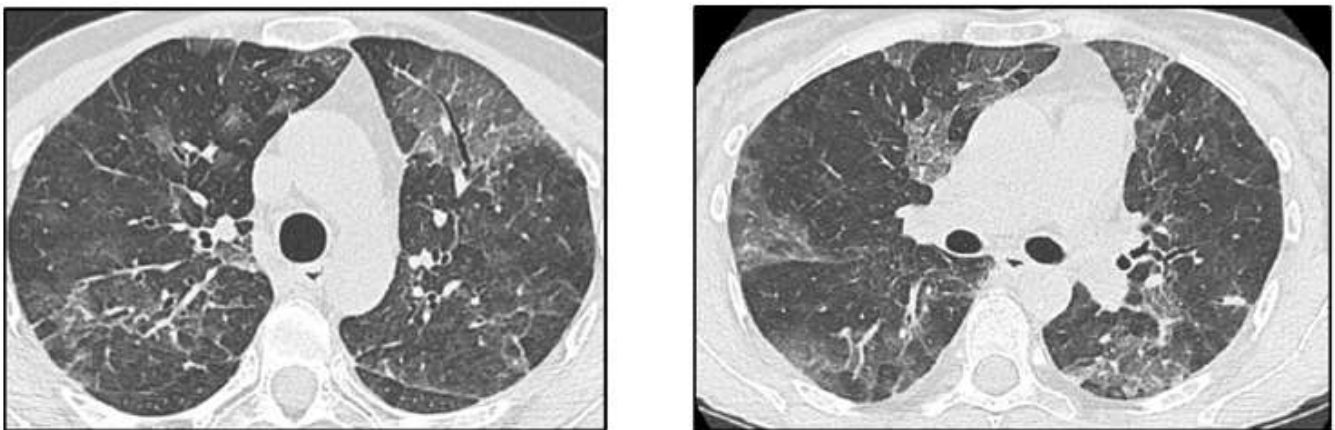


Figure 2: CT-scan performed after oral steroid plus azathioprine administration

Discussion

Organizing pneumonia represents a distinct lung tissue repair pattern following injury. It can manifest as cryptogenic or as a response to various specific lung injuries, including infections, drug exposure, connective tissue diseases, hematologic cancers, transplantation, radiation injury, immunodeficiency, inflammatory bowel disease, inhalation injury, or in association with other interstitial lung diseases. The pathogenesis of organizing pneumonia remains poorly elucidated. Lung injury seems to occur abruptly, without significant disruption of lung architecture. It is characterized by an inflammatory and fibroproliferative process, marked by intra-alveolar fibroproliferation, which is often reversible with immunosuppressive or anti-inflammatory

therapy, although spontaneous resolution can also occur. [5,6,7,8] OP is frequently suspected when patients initially diagnosed with infectious pneumonia fail to respond to antibiotic treatment. [9] Common symptoms include a dry cough (reported in 71% of cases), mild to moderate dyspnea (in 62% of cases, worsened by exertion), and fever (present in 44% of cases). On physical examination, inspiratory crackles are the most commonly noted finding (observed in 60% of cases). [5]

Radiological findings in organizing pneumonia (OP) exhibit a wide range of characteristics. Chest radiographs typically show distinctive features, including bilateral opacities that appear patchy or diffuse, often presenting as consolidative or hazy. The extent and severity of these abnormalities become more apparent on high-resolution computed tomography (CT) scans of the lungs. The prevailing pattern observed on high-resolution CT scans is peripheral and multifocal consolidation, which may or may not exhibit air bronchograms. These findings can manifest unilaterally or bilaterally and are distributed throughout all lung zones, with a slight predilection for subpleural and lower-lung-zone areas. Other radiological signs may include ground-glass opacities and approximately 8 mm nodules. Radiological abnormalities may also present as migratory opacities with areas of spontaneous regression and new consolidation zones. In rare cases, small pleural effusions have been reported. [5]

In our case the patient presented with fever, chills and sweating. The initial diagnosis was infectious pneumonia, for which she was treated with broad-spectrum antibiotics without benefit. The radiological picture was mostly characterized by ground glass and bilateral multifocal consolidations with the presence of an air bronchogram in the context. In consideration of the clinical worsening, transbronchial biopsies were performed detecting a pattern of organizing pneumonia. All secondary causes of OP were excluded. A therapy with Prednisone 25 mg 2 times a day was therefore performed and after about a week a re-evaluation chest CT scan was repeated with evident radiological improvement. Despite the radiological improvement, the patient continued to have fever with a temperature of 40°C, for this reason she was placed on azathioprine therapy at a dosage of 25 mg q12h with violent resolution of the fever after 24 hours of treatment. In conclusion: We presented a case with clinical, radiology, pathology, and violent radiological response to steroid compatible with OP. The patient was being treated with Ocrelizumab; compared to the only case report reported in which there was a temporal cause-effect relationship since the patient began to feel ill a few days after the first dose, in this case the patient had been on treatment for 4 years and the last dose was administered 2 months before the onset of symptoms. Since there are cases reported in the literature of

rituximab-induced organizing pneumonia in which the cause was the seriality of administration [10,11,12], it would therefore be stimulating to understand whether even in the case of therapy with Ocrelizumab there could be long-term pulmonary side effects.

The various adverse effects of Ocrelizumab require a more detailed and well-established studies as the use of the drug is becoming increasingly more widespread in clinical settings. Physicians should be aware of the association between organizing pneumonia and the repetitive administration of Ocrelizumab. As well as any pulmonary event.

References

- [1] Aysan N, Köybaşı G, Satıcı C, Demirkol MA, Arpınar Yiğitbaş B, Arpaçağ Koşar AF. Organizing pneumonia following ocrelizumab use in a patient with multiple sclerosis: A case report. *Tuberk Toraks*. 2023 Mar;71(1):107-111. English. doi: 10.5578/tt.20239913. PMID: 36912415.
- [2] Mulero P, Midaglia L, Montalban X. Ocrelizumab: a new milestone in multiple sclerosis therapy. *Ther Adv Neurol Disord*. 2018 May 10;11:1756286418773025. doi: 10.1177/1756286418773025. PMID: 29774057; PMCID: PMC5952271.
- [3] Lioté H, Lioté F, Séroussi B, Mayaud C, Cadranet J. Rituximab-induced lung disease: A systematic literature review. *Eur Respir J*. 2010 Mar;35(3):681-7. doi: 10.1183/09031936.00080209. Epub 2009 Jul 16. PMID: 19608586.
- [4] Aysan N, Köybaşı G, Satıcı C, Demirkol MA, Arpınar Yiğitbaş B, Arpaçağ Koşar AF. Organizing pneumonia following ocrelizumab use in a patient with multiple sclerosis: A case report. *Tuberk Toraks*. 2023 Mar;71(1):107-111. English. doi: 10.5578/tt.20239913. PMID: 36912415.
- [5] King TE Jr, Lee JS. Cryptogenic Organizing Pneumonia. *N Engl J Med*. 2022 Mar 17;386(11):1058-1069. doi: 10.1056/NEJMra2116777. PMID: 35294814.
- [6] American Thoracic Society; European Respiratory Society. American Thoracic Society/European Respiratory Society International Multidisciplinary Consensus Classification of the Idiopathic Interstitial Pneumonias. This joint statement of the American Thoracic Society (ATS), and the European Respiratory Society (ERS) was adopted by the ATS board of directors, June 2001 and by the ERS Executive Committee, June 2001. *Am J Respir Crit Care Med*. 2002 Jan 15;165(2):277-304. doi: 10.1164/ajrccm.165.2.ats01. Erratum in: *Am J Respir Crit Care Med* 2002 Aug 1;166(3):426. PMID: 11790668.

- [7] Travis WD, Costabel U, Hansell DM, King TE Jr, Lynch DA, Nicholson AG, Ryerson CJ, Ryu JH, Selman M, Wells AU, Behr J, Bouros D, Brown KK, Colby TV, Collard HR, Cordeiro CR, Cottin V, Crestani B, Drent M, Dudden RF, Egan J, Flaherty K, Hogaboam C, Inoue Y, Johkoh T, Kim DS, Kitaichi M, Loyd J, Martinez FJ, Myers J, Protzko S, Raghu G, Richeldi L, Sverzellati N, Swigris J, Valeyre D; ATS/ERS Committee on Idiopathic Interstitial Pneumonias. An official American Thoracic Society/European Respiratory Society statement: Update of the international multidisciplinary classification of the idiopathic interstitial pneumonias. *Am J Respir Crit Care Med*. 2013 Sep 15;188(6):733-48. doi: 10.1164/rccm.201308-1483ST. PMID: 24032382; PMCID: PMC5803655.
- [8] Cottin V, Cordier JF. Cryptogenic organizing pneumonia. *Semin Respir Crit Care Med*. 2012 Oct;33(5):462-75. doi: 10.1055/s-0032-1325157. Epub 2012 Sep 21. PMID: 23001801.
- [9] Drakopanagiotakis F, Paschalaki K, Abu-Hijleh M, Aswad B, Karagianidis N, Kastanakis E, Braman SS, Polychronopoulos V. Cryptogenic and secondary organizing pneumonia: clinical presentation, radiographic findings, treatment response, and prognosis. *Chest*. 2011 Apr;139(4):893–900. doi: 10.1378/chest.10-0883. Epub 2010 Aug 19. PMID: 20724743.
- [10] Biehn SE, Kirk D, Rivera MP, Martinez AE, Khandani AH, Orłowski RZ. Bronchiolitis obliterans with organizing pneumonia after rituximab therapy for non-Hodgkin's lymphoma. *Hematol Oncol*. 2006 Dec;24(4):234-7. doi: 10.1002/hon.799. PMID: 16948177.
- [11] Macartney C, Burke E, Elborn S, Magee N, Noone P, Gleadhill I, Allen D, Kettle P, Drake M. Bronchiolitis obliterans organizing pneumonia in a patient with non-Hodgkin's lymphoma following R-CHOP and pegylated filgrastim. *Leuk Lymphoma*. 2005 Oct;46(10):1523-6. doi: 10.1080/10428190500144615. PMID: 16194900.
- [12] Burton C, Kaczmarski R, Jan-Mohamed R. Interstitial pneumonitis related to rituximab therapy. *N Engl J Med*. 2003 Jun 26;348(26):2690-1; discussion 2690-1. doi: 10.1056/NEJM200306263482619. PMID: 12826649.

