



## **Infrazygomatic Crest and Buccal Shelf Screws- A Revolution for Treatment of Complex Cases in Orthodontics**

Dr. Bhavya M Jain <sup>\*1</sup>, Dr. Aparna P <sup>2</sup>

1. Senior Lecturer, Department of Orthodontics, College of Dental Sciences, Davanagere.

2. Professor, Department of Orthodontics, College of Dental Sciences, Davanagere.

**\*Correspondence to:** Dr. Bhavya M Jain, Professor, Department of Orthodontics, College of Dental Sciences, Davanagere.

### **Copyright**

© 2023 **Dr. Bhavya M Jain**. This is an open access article distributed under the Creative Commons Attribution License, which permits unrestricted use, distribution, and reproduction in any medium, provided the original work is properly cited.

Received: 31 July 2023

Published: 01 December 2023

## **Abstract**

*Infrazygomatic crest and buccal shelf bone screws have gained significance in orthodontics as auxiliary tools for achieving optimal orthodontic outcomes. This abstract provides an overview of the clinical applications, techniques, and advantages associated with the use of these bone screws in orthodontic treatment. They can serve as a reliable anchor for various orthodontic mechanics, such as intrusion, extrusion, or distalization of teeth, allowing precise control over tooth positioning and alignment.*

**Keywords:** *TADS, IZC, Buccal Shelf, Complex cases, Extraalveolar bone screws.*

## **Introduction**

The movement of teeth within the scope of orthodontic treatment occurs through the application of forces. Anchorage control is one of the most important aspects of orthodontic treatment. In order for these forces to affect a change in tooth position, adequate support i.e anchorage must be available from which forces are applied. These forces act reciprocally on the teeth that are intended for movement, and upon those structures used for support via Newton's Third Law. If other teeth are used to support tooth movement, then the equal and opposite forces are applied to the teeth intended for movement and also to the anchor teeth. This may result in unintentional changes in anchorage support [1].

One of the ways to minimize anchorage loss is the use of auxiliary appliances to the posterior anchor unit, including headgear or fixed auxiliaries, transpalatal arch or Nance button. The use of multiple teeth at the anchorage segment to form a large counterbalancing unit and the application of differential moments have also been described as methods to stabilize molar position. However, even with excellent cooperation, space loss due to anchor units moving is almost inevitable [2].

Extra-radicular bone screws and micro implants both are classified under temporary anchorage devices. Micro-implants are placed in between the roots of teeth (mostly) – intra-radicular, while bone screws are placed away from the roots in the infra-zygomatic areas of the maxilla and the buccal shelf areas of the mandible (extra-radicular) [3].

The IZC and BS region are considered as the safer zone as these areas are devoid of important anatomical structures like a tooth root, nerves, etc. The absence of hindrance to the roots of teeth allows for more versatility of Orthodontic tooth movement. IZC/BS regions have good quality and quantity of the bone to provide good primary stability with bone density of  $D1 > 1250$  HU [4, 5, 6].

## History

Clinicians and researchers have tried to use implants as orthodontic anchorage units for over a half century.

Gainsforth and Higley (1945) used implants to attain orthodontic anchorage. They placed vitallium screws and wires in the dog ramus, and applied elastics that extend from screw to the hook of maxillary archwire for distalization. All screws failed within 16 to 31 days.

Linkow (1969) published case reports of attempts to use endosseous implants to move teeth. He used mandibular blade-vent implants in a patient to apply class II elastics for retraction of maxillary incisors.

Branemark and co-workers (1970) reported successful osseointegration of implants in bone, after which many orthodontists began taking an interest in using implants for orthodontic anchorage.

Sherman (1978) placed six vitreous carbon dental implants into extraction sites of mandibular third premolars of dogs and applied orthodontic forces. Two of the implants were firm and considered successful.

Smith (1979) studied the effects of loading bioglass-coated aluminium oxide implants in monkeys and reported no significant movement of the implants during force application. He described the interface between the bio-glass implants and the surrounding tissue as fusion or ankylosis, despite the observation that intervening areas of connective tissue were present.

Creekmore and Eklund (1983) attempted to determine if a small sized vitallium bone screw could withstand a constant force of adequate magnitude over a long period of time to depress entire anterior maxillary dentition without becoming loose, infected, painful or pathologic. The screw was inserted

just below anterior nasal spine. Ten days after placement, a light elastic thread was tied from the head of the screw to the archwire. During treatment, the maxillary central incisors were elevated a total of about 6mm. The bone screw did not move during treatment and was not mobile at the time it was removed.

Roberts and colleagues (1984) investigated osseous adaptations of rigid endosseous implants to continuous loading. Titanium implants with and acid etched surface were screwed into the femur of three- to six-month-old rabbits. They reported that a healing time of six weeks prior to loading, which they said was equivalent to four to five months in humans, was adequate to obtain rigid stability. They concluded that endosseous implants had potential to be used as a source of firm osseous anchorage for Orthodontics and Dentofacial Orthopedics.

Shapiro and Kokich (1988) described the possibility of using dental implants for anchorage during orthodontics treatment prior to being used for prosthodontic purposes. They emphasized the importance of the position of implants as well as the proper case selection and implant requirements during diagnosis and treatment planning. They also emphasized the need for adequate oral hygiene for maintenance of the implant

Roberts and co- workers (1994) reported the clinical application of a 3.75mm x 7.0 mm standard Branemark fixture as anchorage in retromolar area for closing a mandibular first molar extraction site. An anchorage wire attached to the implant was extended to the vertical tube of the premolar bracket. Stabilizing the premolar anterior to the extraction site allowed mesial movement of molars without distal movement of more anterior teeth.

Block and Hoffman (1995) introduced the onplant to provide orthodontic anchorage. The onplant is a thin titanium alloy disk (2mm high and 10mm in diameter), textured and coated with a hydroxyapatite (HA) on one side and with an internal thread on the other side. Using dogs and monkeys as their experimental models, they placed an onplant on the palatal bone to provide anchorage for orthodontic tooth movement. In the *Canis lupus* study, onplants did not move, but the premolars attached to the onplants were moved toward the onplant. In the macaca study, the non-anchored molars moved more than the molars anchored to the onplant. The onplant was anchored sufficiently to the underlying bone to withstand 14 ounces of continuous force.

The HA-bone biointegrated interface of the onplant resisted up to 160 pounds of shear force. Thus the onplant provided absolute anchorage for tooth movement without reciprocal movement of the onplant.

Kanomi (1997) reported that 1.2mm diameter titanium mini-implants provided sufficient anchorage for intruding lower anterior teeth. After four months, the mandibular incisors were intruded 6mm. Kanomi applied an orthodontic force on the mini-implant several months after implantation, anticipating osseointegration between the mini-implant and the bone. They found that the possibility of mini-implants being used for horizontal traction, for molar distalization and distraction osteogenesis.

Melsen and co-workers(1998) introduced the use of zygomatic ligatures as anchorage in partially edentulous patients. Under local anesthesia, two holes were made in superior portion of infrazygomatic crest. A double twisted 0.012” stainless steel wire was ligated between the two holes and inserted into the oral cavity. After surgery. NiTi coil springs were attached from zygomatic ligatures to the anterior fixed appliance for intrusion and retraction of maxillary incisors. Treatment time to retract and intrude incisors usually was three to six months. Patient compliance was satisfactory and the results remained stable.

Costa and colleagues (1998) used 2mm titanium miniscrews for orthodontic anchorage. The screws were inserted manually with a screw driver directly through the mucosa without making a flap and were loaded immediately. Of the 16 miniscrews used during the clinical trial, two became loose and subsequently were lost before treatment was finished. They suggested that miniscrews could be place into the inferior surface of anterior nasal spine, the midpalatal suture, the infrazygomatic crest, the retromolar area, the mandibular symphysis area and between premolar and molar regions

Majzoub and colleagues (1999) investigated the bone response of endosseous implants to orthodontic loading. Twenty-four short-threaded titanium implants were inserted into calvarial midpalatal suture of 10 rabbits. Two weeks following insertion, a continuous distalizing force of 150gm was applied for a period of eight weeks. All but one test implant remained stable, exhibiting no mobility or displacement throughout the experimental loading period.

Suguwara (1999) and Umemori and co-workers (1999) used surgical miniplates for orthodontic anchorage. They treated open bite cases by molar intrusion using a miniplate skeletal anchorage system. L-shaped miniplates were implanted in the buccal vestibule and intrusive forces were generated in the molar area by an elastic thread that was tied between the archwire and the miniplate. Adequate molar intrusion was obtained after approximately six to nine months of treatment.

Ohmae and colleagues (2001) reported the results of a clinical and histological evaluation of titanium mini-implants used as anchors for orthodontic intrusion in beagle dogs. Six weeks after insertion of implants, an intrusive force of 150gm was applied. After 12-18 weeks of orthodontic intrusion, all mini-implants remained stable without any mobility or displacement.

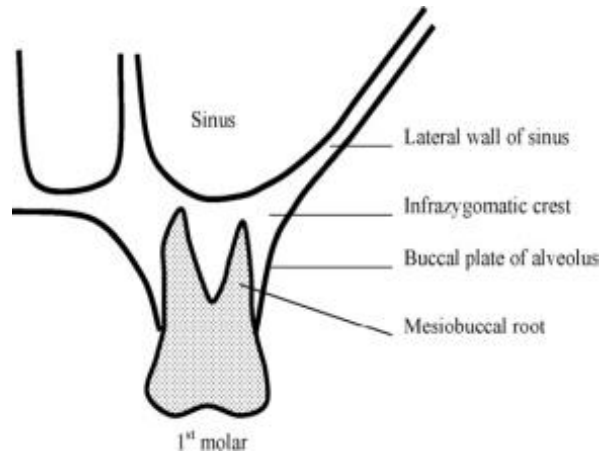
Lee and colleagues (2001) reported on the use of micro implants for lingual orthodontic treatment. They were placed in palatal alveolar bone between first and second molar roots. The micro implants were used for retracting six maxillary anterior teeth en masse using NiTi coil springs in a patient with Class II skeletal pattern. Lee and co-workers showed that micro implants can provide reliable and absolute anchorage for lingual orthodontic treatment as well as conventional labial treatment [7].

Chang (2004), Park (2005), Almeida (2016) recommended sites in the infrazygomatic crest (IZC) and the buccal shelf (BS) regions for many orthodontic therapies that require an efficient and secure anchorage system [8,9,10].

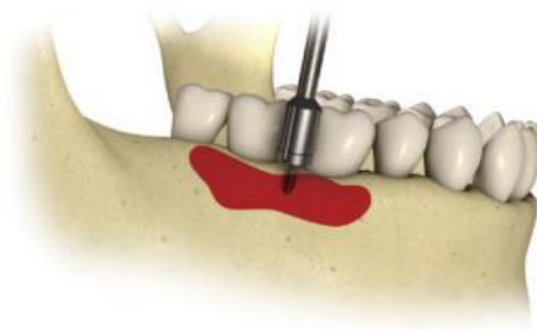
### **Anatomy Of Infrazygomatic and Buccal Shelf Area**

Anatomically the Infrazygomatic crest or IZC is a reinforced bone area with greater thickening of the cortical layer, which extends along the maxilla from the zygoma towards the molars, a palpable bony protuberance is located anteriorly to the maxillary tuberosity<sup>9</sup>. It is the cortical bone between the zygomatic process of maxilla and the alveolar process. In young patients, the IZ crest is between the maxillary second premolar and the first molar. In adults, it is above the maxillary first molar. According to Liou et al (2007), thickness ranges from 5.5 to 8.8mm in adults. The IZC consist of two cortical plates –

- The buccal cortical plate
- The floor of lateral wall of maxillary sinus



The mandibular buccal shelf area is an extra alveolar site for the placement of mini-screws. The buccal shelf region corresponds to the bone plateau that lies between the buccal face of the lower molars and the mandibular external oblique line. This plateau widens, as it approaches the second and third molar. The ideal area for the positioning of a mini-implant is between the first and second lower molars because of the thickness of the cortical bone and the reasonable amount of attached gingiva (which decreases toward the distal teeth). To be specific in the placement of the buccal shelf screw, it is placed lower and lateral to the second molar region<sup>3</sup>. These considerations are valid for the placement of mini-implants both at an angle and perpendicularly to the bone, that is, almost parallel to the long axis of the molars[8].



• **Fig. 14.3** Buccal shelf area (red area), with the ideal site for the positioning of a mini-implant between the first and second lower molars.

## Indications

Extra-alveolar screws allow greater anchorage, immediately after placement (primary stability) when introduced into maxillary and mandibular reinforced bone areas.

- According to Chang et al mini-implants in the IZCs are recommended for the following cases-
- En masse anterior teeth retraction
- En masse retraction of the dentoalveolar arch of the maxilla,
- Intrusion of the posterior teeth
- Individual canine, premolar and molar retraction in patients with bimaxillary protrusion, distalization of canines and premolars to obtain anterior space
- Patients requiring correction of the midline with en masse distalization of the teeth
- Correction of asymmetries of the occlusal plane
- Anchorage for the use of a cantilever in traction of impacted canines
- Early treatment of class III and for class III orthognathic surgical planning.

According to Park et al, The indications for the use of mini-implants placed in the BS region are similar to those for mini-implants in IZC i.e,

- Used in Class III conservative treatment (camouflage)
- For retraction and/or distalization of molars, in treatment of cases with excessive crowding of the lower teeth,
- Mesialization of molars
- Anchorage for retraction of the anterior segment.

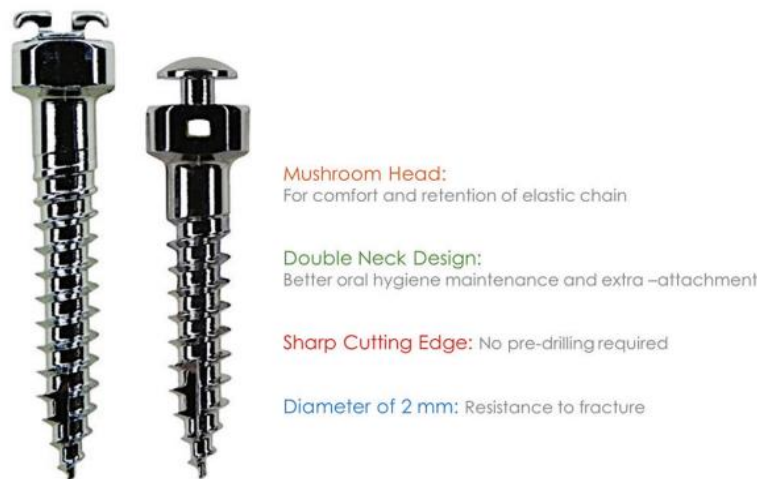

- In cases requiring intrusion of posterior teeth
- Corrections of asymmetries of the occlusal plane and deviations from the midline
- Anchorage for the use of a cantilever in traction of impacted lower canines, and in preparation for orthognathic surgery.

Cases of bimaxillary protrusion can be treated using mini-implants placed in the BS and IZC region [1, 2, 3].

### Specification of Bone Screws

While the regular size of a micro-implant ranges between 6 and 11 mm in length and 1.3–2 mm in diameter depending on the clinical situation in which they are used, Bones screws are comparatively larger in size ranging from 10 to 14 mm in length and a minimum diameter of 2 mm. Just like a micro-implant may be available as a short or a long head one, bone screws are also available as a short or a long collar depending on the anatomic site and the clinical situation it needs to be used for. Their head shapes may also vary just as micro-implants, the common being mushroom shaped.



BONE SCREW SPECIFICATIONS : IZC, BSS

Almost every micro-implant available in the market is made with an alloy of – titanium, aluminum and vanadium (Ti6 Al4 Va) and bone screws are also available with similar compositions but the choice of material is pure stainless steel [9].

Bone screws are generally placed in areas of DI (>1250 HU) quality bone (IZC and BS areas) and therefore requires greater fracture resistance. Stainless steel provides greater fracture resistance than Ti alloy and is therefore the preferred material of choice [3, 9].

The use of surgical stainless steel is indicated because of its greater modulus of elasticity providing resistance to fracture [9, 10].

extra alveolar mini-implants are larger both in length (10, 12, 14, 17 mm) and diameter (1.5–2 mm) [3, 10].

Placement torque is influenced by the diameter of the mini-implant i.e the larger the diameter the greater the torque required for placement and consequently the greater the primary stability 10.

Mini-implants with longer lengths allow excellent anchorage[11]. However, they are associated with an increased risk of damage to neighboring structures, especially maxillary sinus perforation. The depth of fit and bone density at the mini-implants placement site are the best predictors of primary stability. Using an 8-mm instead of 6-mm mini-implants increases the success rate from 72% to 90% [12].

The resistance to torsional fracture of the mini-implants is directly related to their diameter, i.e. the larger the diameter, the greater the fracture torque. Thus, it seems to be advantageous to use mini-implants with a larger diameter and longer length.

The extra alveolar mini-implants are placed in a site with high bone density (cortical bone), initial perforation with a spear-tip or clinical probe is indicated in certain cases, even when using self-drilling orthodontic steel mini-implants. The aim of this procedure is to minimize the risk of fracture during placement.

## Placement Technique

The mini-implant placement techniques in IZC and BS region depend on the material out of which the implants are made (steel or titanium), to increase the success rate (stability).

Three key factors are:

1. Bone Quality
2. Mini-Implants Design
3. Placement Technique [13].

The principles of biosafety must be strictly observed before the placement of the mini-implants. The angle of placement of the mini-implant in the IZC is fundamental. The ideal technique is placing it almost parallel to the long root axis of the molars, increasing its contact surface with the cortical bone, guaranteeing greater stability. An upright position of the mini-implant reduces the chance of reaching the root.

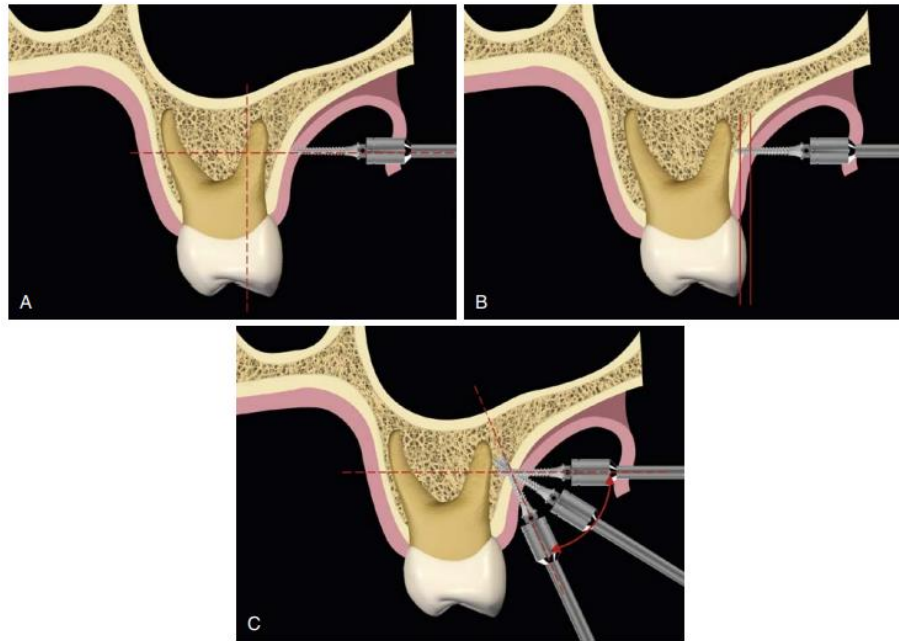
Steps for secure placement in the IZC are as follows- Anesthetize the surgical area.

Initially, place the tip of the mini-implants at a 90-degree angle to the bone surface at the region of the IZC, after piercing the cortical bone at the mucogingival junction, using an endodontic explorer.

Penetrate the tip 1 mm into the cortical bone, at the height of the buccal roots, between the first and second upper molars in adults and in the region between the second premolar and the first molar in young people, since the zygomatic-maxillary crest in these individuals is located more anteriorly, as can be determined by local palpation. Then, turn the hand wrench between 60 and 70 degrees to the occlusal plane, while rotating it clockwise threading the mini-implants.

The patient's age, bone morphology, and the type of biomechanics to be performed should be considered.

In the sagittal plane, that is, in the anteroposterior direction, position the head of the mini-implants, with a slight incline to the mesial direction<sup>10</sup>



• Fig. 14.10 (A to C) Steps for secure placement of mini-implants in the infrazygomatic crest area.

Careful evaluation of the Buccal Shelf area should be performed before the placement of a mini implant.

The amount of bone present and the extent of gingiva, through which the mini-implants needs to be inserted, should be considered.

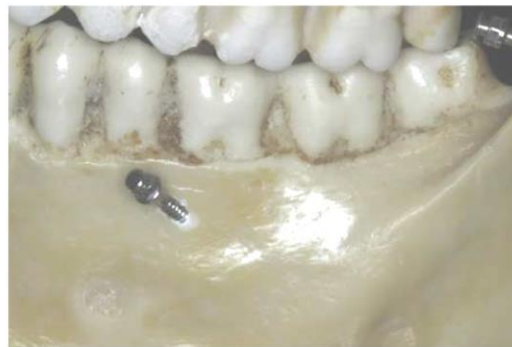The topography of the mandibular canal through which the inferior alveolar nerve travels. Because of its more lingual position relative to the apex of the roots of the lower molars, the chance of reaching such a canal is remote, even with  $2 \times 12$  mm mini-implants [15, 16].

For patients with a well-defined plateau and well-attached gingiva, placement of the mini-implant is much simpler; a sizeable buccal shelf allows the positioning of the mini implants in a nearly vertical position, almost parallel to the root of the lower molars.

The placement becomes more difficult, if the buccal shelf area is less favorable to placement, as the mini-implants should be placed at a higher angle and in a free mucosal site[17].

Authors have argued for the use of the mini-implants in the BS, both in the attached gingiva and in free gingiva, depending, in the latter case, more careful hygiene, to avoid possible inflammation and peri-implant mucositis, with consequent anchorage instability. It should be emphasized that the attached gingiva range is larger in the region of the first lower molar, and decreases to the distal ends of the dental arch[18].

The placement technique follows the same procedures i.e after following the principles of biosafety, it is necessary to perform local anesthesia and drill the cortical bone. Then the mini-implant is placed at the desired angle (70 degrees) relative to the occlusal plane<sup>3</sup>, as mentioned for the mini-implants placed in the IZC.



### **Biomechanics**

Biomechanics include basic information that are necessary for understanding the physics principles that are common to every orthodontic equipment.

Mini-implants in the IZC generate a retraction force system during distalization of the entire maxillary arch. The retraction force in the entire maxillary arch generates intrusive force in the molars and extrusive force in the incisors, caused by clockwise rotation around the center of resistance (Cr) of the entire maxilla, which is located between the premolars. The force line of action passes below (occlusal) the maxillary Center of resistance and consequently, causes this rotation. For this reason, incisor extrusion occurs which may be unfavorable for patients with deep bite.

On the other hand, this occlusal plane clockwise rotation favors simultaneous open bite closure and Class II correction. Retraction biomechanics can be modified through changes in the height of hooks

in the anterior area and in the force line of action.

Biomechanics is crucial for treatments that utilize extra-alveolar mini-implants. As mentioned before, each particular case requires correct force application (direction and anchoring point). For this reason, there are two important factors to be taken into account when studying correct force design, in which different types of dental movements can be obtained-

1. Height of hooks in the anterior area
2. Height modification in extra-alveolar mini-implants insertion

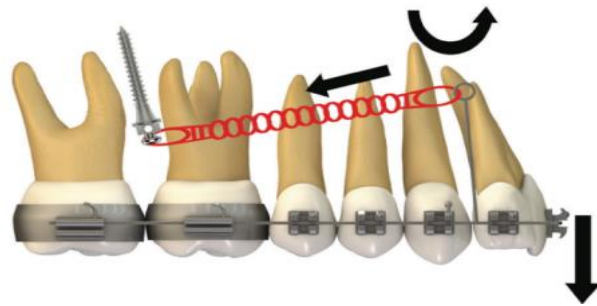
It is not always possible to change mini-implants installation height because there are numerous factors that influence the choice of the ideal place. However, given the force direction that is required for each case, it is known that the type of anterior hook/power arm, regarding its height and location, will be a decisive factor for the expected type of movement.

Changes in force geometry through different hooks or power arm in the anterior area of the arch can influence incisor torque control, as well as vertical changes occurring in the area (open bite or deep bite). Furthermore, the use of asymmetrical forces to correct Class II subdivision, by means of mini-implants in the IZC, must take into consideration the possible occlusal plane inclination. In a similar manner, asymmetrical treatments of midline deviations must be extremely well planned, regarding the correct application of the forces line of action.

Clinically, when utilizing mechanics with extra-alveolar mini-implants, such differential movements can be reproduced on the anterior teeth by modifying the force line of action, through changes in hooks/power arm length[19].

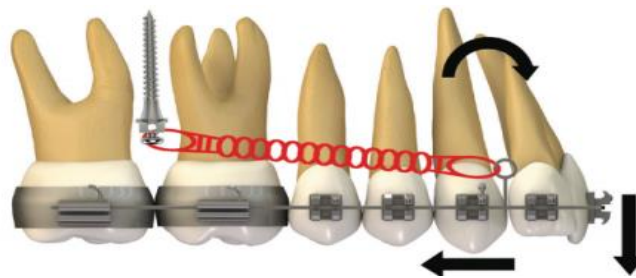
#### **Use of Short Hook:**

Anterior teeth have a tendency to rotate clockwise when retraction force is applied by means of a force that passes below the Cr, which leads to torque loss, and a vertical extrusion force on the incisors.



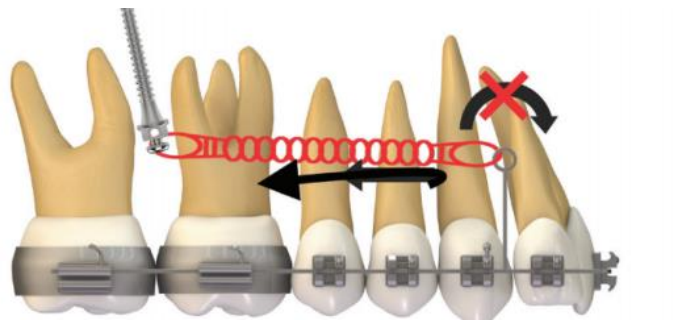
### Use of Middle Length Hook

When retracting the entire dental arch, if there is intention of preserving the anterior torque, a change in the geometry of force direction must be made. Height of the hook mesial to the canine was increased, allowing the force action line to pass close to the incisor's center of resistance. Anterior moment is likely to be cancelled out because of this procedure and during retraction; incisor torque can be maintained, with less change in the occlusal plane.



### Use of Long Hook.

In order to provide proper lingual root torque to the incisors, during distalization of the entire arch, hook/power arm length must be extended, in order to make the force pass above the center of resistance, generating a counterclockwise moment on these teeth. It is important to point out that, during clinical practice, such situation may be more complicated due to the possibility of injuring the patient's oral mucosa.

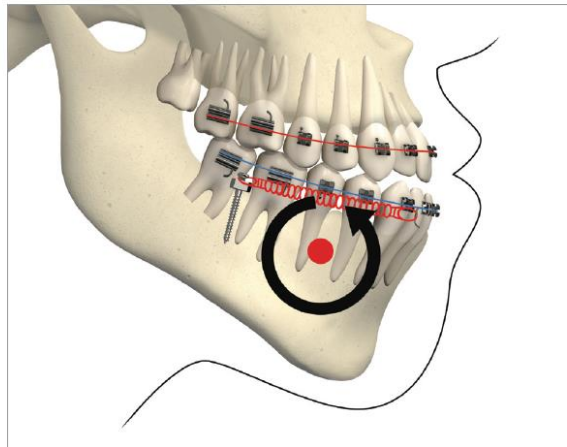




Biomechanics of mini-implants in the Buccal Shelf area.

With the exception of the need for third molar extraction, this mechanics is considered non-extraction and non-surgical, and allows the entire mandibular dentition to be retracted in one block, since the mini-implants are located outside the roots' line of action and, therefore, do not interfere with the movement of the entire arch.

Through finite elements (3D) and CBCT analysis a robust system considered “statically determinate”, which stems from the mechanics for retraction of the entire mandibular dentition, produced by the use of two mini-implants in the BS and a full size rectangular archwire, with NiTi springs applying constant force of 200 g [21].



Roberts et al<sup>57</sup> consider this system for mandibular teeth retraction anchored on two mini-implants in the BS to be an excellent resource for a conservative and nonextraction treatment of Class III malocclusion with anterior open bite, since the retraction force in the entire arch generates an intrusive force in the molars and an extrusive force in the incisors, caused by the rotation of the mandibular arch. This counterclockwise rotation of the mandibular plane observed through finite elements analysis, resulted in a 3-mm molar intrusion and 2-mm incisor extrusion, favouring open bite closure and simultaneous Class III correction. In the superimposition of mean effects, during finite elements analysis, an axis of rotation of the entire arch was observed close to the mandibular canine area.



The mechanics with mini-implants in the BS used for single-block retraction of the entire mandibular dentition demonstrated mandibular occlusal plane rotation during mandibular teeth retraction with BS mini-implants and traction force from the archwire to the mini-implant. This counterclockwise rotation occurs because the force action line is located occlusal to the center of resistance of the arch consequently, generates a moment that causes incisor extrusion and molar intrusion. Arch rotation associated with retraction manifests with clear distal inclination of the molars. A decrease in mandibular plane angle can also be noted [19].

### **Force Magnitude**

The force magnitude used in extra-alveolar mini-implants mechanics is an important factor for the therapy's success, due to its influence on anchorage stability. The recommended magnitude varies from 220 to 340g (8 to 12 oz) for mechanics with mini-implants in the IZC area for en masse retraction. For cases in which a partial retraction is needed. for example, to retract canines and premolars force must be adjusted between 150 and 200 g .The recommendation for buccal shelf mini-implants ranges from 340 to 450-g [3,21].

### **Advantages**

Contemporary orthodontics has used E-A mini-implants, located in areas far from the insertion points of the roots of the teeth, to extend the limits of this treatment, in view of the benefits of this approach, such as:

- Reduced risk of traumatizing roots.
- Larger amount of cortical bone at the points of placement, which allows the use of more flexible mini-implants (2 mm).
- Lack of interference with the mesiodistal movement of the teeth.
- Adequate anchorage for the retraction of the dental arch as a whole, reducing protrusion.

- Low percentage of failure.
- Use of fewer mini-implants in complex cases[3].

## Complications

The problems associated with mini-implant during placement or after the placement are-

- Maxillary sinus perforation commonly seen in the first molar region or in case of the missing posterior teeth as the sinus wall is lower. The penetration of 2mm heal themselves, hence orthodontic treatment can be continued in such cases
- Check mucosa irritation
- Ulceration
- Soft tissue irritation is a common problem faced with IZC, so to avoid this a clearance of 2.5mm has to be given between screw head and soft tissue.
- Further anatomy of the IZC site has to be taken into consideration for the proper selection of the screw length.
- Other complications associated with mini-screws like mini-screws bending, failure or fracture, stationary anchorage loss is also seen, but to a lesser extent. In the case of early loosening of the screw -replacement is advisable in the different sites.
- Apart from minor bleeding on insertion, gingival overgrowth on the screw and and early loosening of the screw are common complications. Breakage of tip of the screw is seldom seen if pure stainless steel good quality screws are used. To avoid problems related to gingival overgrowth – oral hygiene maintenance is of utmost importance. The incidence of gingival overgrowth is far less with screws having larger heads. In case of early loosening of the screw–re-placement of the screw is advisable in a different site.

- Failure rate of IZC is 7%. The reason for failure was poor bone quality, immediate loading, low sinus floor, movable mucosa [20].

### **Precautions**

- Preferably place the mini-implants in the attached gingiva.
- Respect general principles of biosafety.
- Maintain strict hygiene at the site of implantation, especially in cases where the mini-implants are placed, in the area of transition, from attached gingiva towards movable mucosa.
- Maintain the correct angle when placing the mini-implant, to avoid injuring the roots, in both the upper and lower teeth.
- When the implanted region is that of the zygomatic–alveolar crest, avoid the possibility of reaching the maxillary sinus (although this seems not to be a problem).
- In cases of distalization of lower second molars, use panoramic x-ray or CBCT to verify that there is sufficient space for this movement.
- In young people, mini-implants are placed more anteriorly (in the region of the first molar, IZC 6) and higher (vertical), to prevent the possibility of lesioning the root of the tooth. Often the positioning is done in the free gingiva (mobile mucosa), taking the above-mentioned precautions.
- Clinically, in cases of doubt, pre-evaluate the placement of the mini-implant, both in the IZC region, using CBCT [2, 3].

## Conclusion

In the world of orthodontics, the development of the IZC/BS screw represents a miraculous breakthrough. By transforming borderline surgical cases to non-surgical cases and extraction instances to non-extraction, they have truly revolutionized the perspective of anchoring conservation and the paradigm of orthodontic biomechanics. They even purchased a visual effect, which was tough to produce using conventional biomechanics. Finally, appropriate case selection and precise screw placement with good biomechanics will contribute in attaining the best results in patients.

## References

1. Graber, T., Vanarsdall, R., Vig, K. and Xubair, A.,2012. Orthodontics: Current Principles and Techniques. 5th ed. St. Louis: Elsevier Mosby.
2. Ludwig B, Baumgaertel S, Bowman SJ. Mini-implants in orthodontics: innovative anchorage concepts.London, UnitedKingdom: Quintessence;2008.
3. Ravindra Nanda, Flavio Uribe, Sumit Yadav,Temporary Anchorage Devices in Orthodontics (Second Edition),Elsevier,2020,
4. Almeida MR, Almeida PR, Nanda R: Biomecânica dos miniimplantes inseridos na região de crista infrazigomática para correção de má-oclusão de Classe II subdivisão, Rev Clin Ortod Dental Press 15(6):90–105, 2017
5. Almeida MR: Biomecânica de distalização dentoalveolar com mini-implantes extra-alveolares em paciente Classe I com biprotrusão, Rev Clin Ortod Dental Press 16(6):61–76
6. Costa A, Raffainl M, Melsen B: Mini-screws as orthodontic anchorage: a preliminary report, Int J Adult Orthodon Orthognath Surg 13(3):201–209, 1998. 7. Chang CH: Clinical applications of orthodontic bone screw in Beethoven orthodontic center, Int J Orthod Implantol 23:50–51, 2011.

7. Sung, J.H., Kyung, H.M., Bae, S.M., Park, H.S., Kwon, O.W. & McNamara, J.A. (2006) *Microimplants in Orthodontics*. Daegu, Korea: Dentos
8. Chang C, Huang C, Roberts E: 3D cortical bone anatomy of the mandibular buccal shelf: a CBCT study to define sites for extraalveolar bone screws to treat Class III malocclusion, *Int J Orthod Implantol* 41(1):74–82, 2016.
9. Almeida MR: *Mini-implantes extra-alveolares em Orrtodontia*, ed 1, Maringá, 2018, Dental Press.
10. Park HS, Jeong SH, Kwon OW: Factors affecting the clinical success of screw implants used as orthodontic anchorage, *Am J Orthod Dentofacial Orthop* 130(1):18–25, 2006
11. Lemieux G, et al.: Computed tomographic characterization of mini-implant placement pattern and maximum anchorage force in human cadavers, *Am J Orthod Dentofacial Orthop* 140(3):356– 365, 2011.
12. Chen CH, Chang CS, Hsieh CH, Tseng YC, Shen YS, Huang IY, et al.: The use of microimplants in orthodontic anchorage, *J Oral Maxillofac Surg* 64(8):1209–1213, 2006.
13. Chang CH, Roberts WE: A retrospective study of the extra-alveolar screw placement on buccal shelves, *Int J Orthod Implantol* 32:80–89, 2013.
14. Nucera R, Lo Giudice A, Bellocchio AM, Spinuzza P, Caprioglio A, Perillo L, et al.: Bone and cortical bone thickness of mandibular buccal shelf for mini-screw insertion in adults, *Angle Orthod* 87(5):745–751, 2017.
15. Elshebiny T, Palomo JM, Baumgaertel S: Anatomic assessment of the mandibular buccal shelf for mini-screw and insertion in white patients, *Am J Orthod Dentofacial Orthop* 153:505–511, 2018.
16. Chang CH: Clinical applications of orthodontic bone screw in Beethoven orthodontic center, *Int J Orthod Implantol* 23:50–51, 2011

17. Hsu E, Lin JSY, Yeh HY, Chang C, Robert E: Comparison of the failure rate for infra-zygomatic bone screws placed in movable mucosa or attached gingiva, *Int J Orthod Implantol* 47(1):96– 106, 2017.
18. Melsen B, Pedersen J K, Costa A. Zygoma ligatures – an alternative anchorage in the upper jaw. *J Clin Orthod* 1998; 32:154–8.
19. Roberts WE, Viecilli RF, Chang C, Katona TR, Paydar NH. Biology of biomechanics: finite element analysis of a statically determinate system to rotate the occlusal plane for correction of a skeletal Class III open bite malocclusion. *Am J Orthod Dentofacial Orthop*. 2015 Dec;148(6):943-55.
20. Sreenivasagan S, Sivakumar A. CBCT comparison of buccal shelf bone thickness in adult Dravidian population at various sites, depths and angulation - A retrospective study. *Int Orthod*. 2021 Sep;19(3):471-479
21. Almeida, M. R. (2019). Biomechanics of extra-alveolar mini-implants. *Dental Press Journal of Orthodontics*, 24(4), 93–109.

