



## **Giant Rhinophyma Complicated by Bilateral Ectropion: A Case Report**

Dr Basma Ouidani <sup>\*1</sup>, F. Elbenkadri <sup>2</sup>, Z. Elgouti <sup>3</sup>, Pr Hussein Ait Ihaj <sup>4</sup>, Pr Fouad Elasri <sup>5</sup>

*1. Military Hospital of Marrakech, Ophthalmology Department.*

**\*Correspondence to:** Dr Basma Ouidani, Military Hospital of Marrakech, Ophthalmology Department.

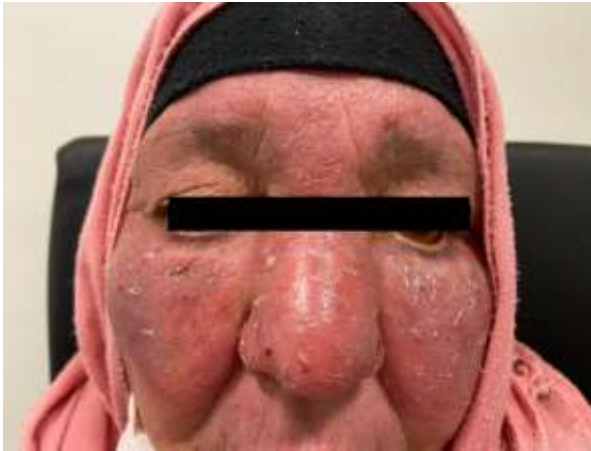### **Copyright**

© 2023 **Dr Basma Ouidani**. This is an open access article distributed under the Creative Commons Attribution License, which permits unrestricted use, distribution, and reproduction in any medium, provided the original work is properly cited.

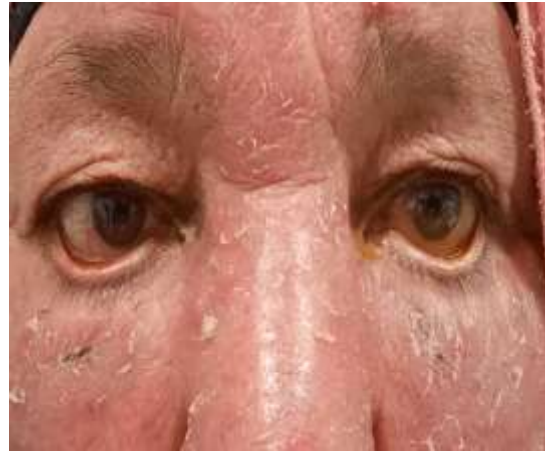Received: 22 August 2023

Published: 01 September 2023

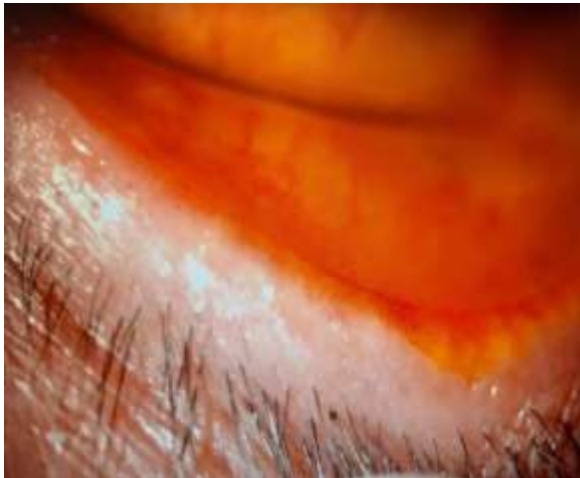A 63-year-old woman who suffered from rosacea which was complicated by rhinophyma (figure 1). She consulted for bilateral redness without a context of trauma persistent for 3 months and resistant to symptomatic treatment. Clinical findings included bilateral ectropion (figure 2) with chronic free edge telangiectasia and severe dry eye disease shown as inferior superficial punctate keratitis (figure 3 and 4). The therapeutic approach in this case was difficult and combined dermatological and ophthalmic treatments before considering any surgical intervention.



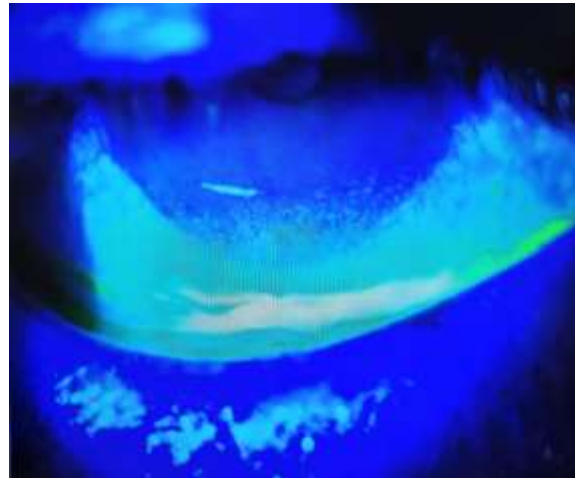
**Figure 1 :** rhinophyma



**Figure 2 :** ectropion



**Figure 3:** Free edge telangiectasia



**Figure 4:** Superficial punctate keratitis

