



Upside-down Hypopyon

A. eladrari¹, F. benelkadri ²; M. Kriet³; F.elasri⁴

1,2,3,4. University Cadi Ayad ,Department of Ophthalmology, Avicenne Hospital, Marrakech, Morocco.

***Correspondence to:** Dr. Farah Kadri, University Cadi Ayad , Department of Ophthalmology, Avicenne Hospital, Marrakech, Morocco.

Copyright

© 2024 **Dr. Farah Kadri**. This is an open access article distributed under the Creative Commons Attribution License, which permits unrestricted use, distribution, and reproduction in any medium, provided the original work is properly cited.

Received: 17 September 2024

Published: 25 September 2024

The upside-down hypopyon is sometimes seen after posterior vitrectomy with tamponade with silicone oil, when the oil emulsifies, it passes into the anterior chamber and settles at the top of the anterior chamber. Compare to the hypopyon where the leukocytes rush to the bottom of the anterior chamber; and this is due to the effect of gravity.

We report a case of upside-down hypopyon.

A 75-year-old man presents to our office 1 month after having retinal detachment surgery in her left eye. Examination reveals an upside-down hypopyon. The treatment is based on washing the anterior chamber and aspiration of silicone oil.

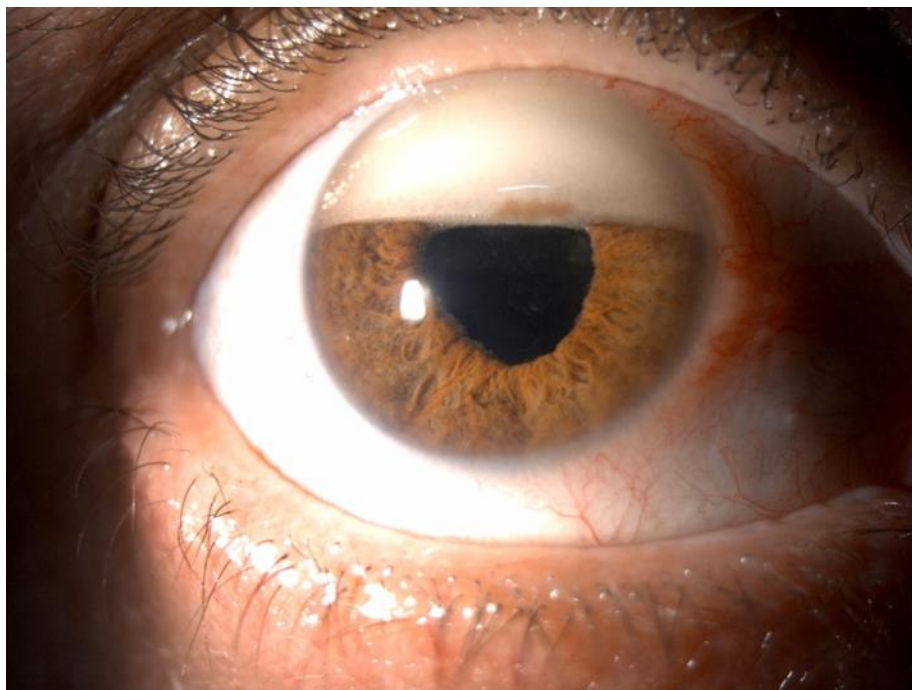


Figure 1. Front view image of the anterior segment showing the dislocated cataract lens in the anterior chamber.



Medtronic