



## Monostotic Fibrous Dysplasia in the Mandible of a 10 Years Old Male Child: A Case Report

Mohamed Said Hamed <sup>1</sup>, Osama Antar <sup>2</sup>, Wafaa Elhossary <sup>3</sup>, Mohamed Mohsen Elbanna <sup>4</sup>, Sarah Arafat <sup>5</sup>, Merhan Nabil Elmansy <sup>6</sup>, Mona Saad Hassanein <sup>7</sup>.

1. Professor of Oral and Maxillofacial Surgery, Faculty of Dentistry, Suez Canal University, Egypt.
2. Professor of Plastic Surgery, Faculty of Medicine, Suez Canal University, Egypt.
3. Associate Professor of Oral Pathology, Faculty of Dentistry, Suez Canal University, Egypt.
4. Assistant Lecturer of Oral and Maxillofacial Surgery, Faculty of Dental Medicine, Sinai University, Egypt.
5. Assistant Lecturer of Oral and Maxillofacial Surgery, Faculty of Dental Medicine, MUST University, Egypt.
6. Associate Professor of Oral Pathology, Faculty of Dentistry, Suez Canal University, Egypt.
7. Lecturer of Oral Pathology, Faculty of Dentistry, Suez Canal University, Egypt.

**Corresponding Author: Mohamed Said Hamed**, Dept of Urology and Kidney Transplant, Pakistan Kidney and Liver Institute Lahore, Pakistan

**Copy Right:** © 2022 Mohamed Said Hamed, This is an open access article distributed under the Creative Commons Attribution License, which permits unrestricted use, distribution, and reproduction in any medium, provided the original work is properly cited.

**Received Date: April 30, 2022**

**Published Date: May 10, 2022**

**Abstract**

**Introduction:** *Fibrous dysplasia developmental anomaly in which normal bone is replaced by fibro-osseous tissue. Early diagnosis in children is based on a history of painless progressive bony swelling*

**Methods:**

*A ten years old boy presented to the outpatient clinic in Faculty of Dentistry, Suez Canal University, suffering from a painless hard swelling the left side of the mandible. Enucleation of the lesion under general anaesthesia for excisional biopsy*

**Results:** *histopathologic examination revealed fibrous dysplasia*

**Key Word:** *Fibrous dysplasia, mandible, child*

**Introduction**

Fibrous dysplasia (FD) is an uncommon developmental disorder in which normal bone is replaced by fibro-osseous tissue. [1]

It arises from mutations in GNAS and proliferation of undifferentiated progenitor cells. FD may occur alone, or with skin pigmentation and hyper-functioning endocrinal disorders, termed McCune-Albright syndrome (MAS). FD may involve any part of the skeleton, ranging from an isolated monostotic lesion affecting one bone, to severe polyostotic disease affecting multiple bones, resulting in bone fractures, deformity, and functional impairment. [2]

Early diagnosis of FD in children is based on a history and clinical presentation of painless progressive bony swelling in patients with polyostotic disease and MAS; however, biopsy is required for diagnosis of monostotic disease. [3]

In this manuscript, we report a case of monostotic FD in the mandible of a 10-year-old male patient. The diagnosis is established based on clinical presentation, panoramic radiograph, CT and confirmed with excisional biopsy. Enucleation for excisional biopsy was the treatment of choice.

## Case Presentation

A ten years old male child presented to the outpatient clinic in Faculty of Dentistry, Suez Canal University, suffering from a painless swelling on the left side of the face; appeared since two months ago and increased in size and became apparent. **(Figure 1)**

Extra-oral examination revealed facial asymmetry and well-defined hard swelling in the left side of the mandible. On intra-oral examination, there was expansion of buccal plate of bone from permanent first mandibular molar reaching the ramus, no signs of mucosal irritation, and no paraesthesia. Aspiration biopsy was negative.

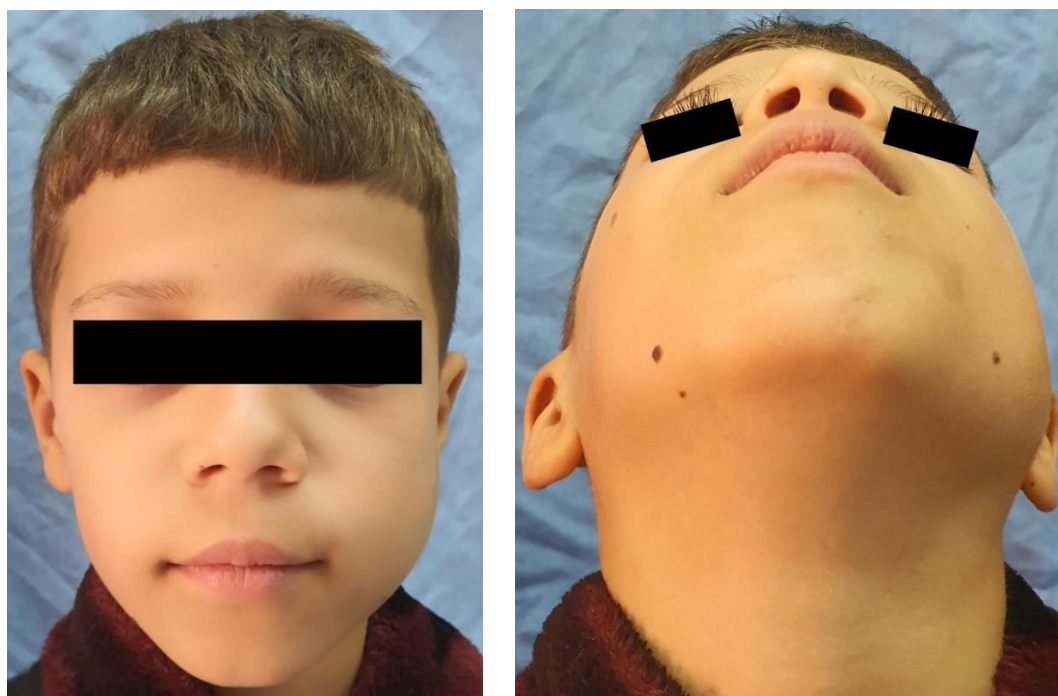Panoramic radiograph showed large expansile, unilateral, well defined with sclerotic border, mixed lesion [alternating radiolucent and radiopaque areas] along the left ramus of the mandible including the tooth follicle of third mandibular molar, at the left side of the mandible, extending from mandibular first molar along the ramus of the mandible, but not reaching the mandibular condyle, causing displacement of the tooth follicle of left 8 towards the coronoid process [dislodged follicle] and displacement of the tooth follicle of the lower left 7 mesially **(Figure 2)**.

CT coronal and axial cuts revealed well-defined mixed lesion, enclosing radio-opaque tooth follicle, with expansion and thinning of buccal and lingual cortical plates **(Figure 3)**.

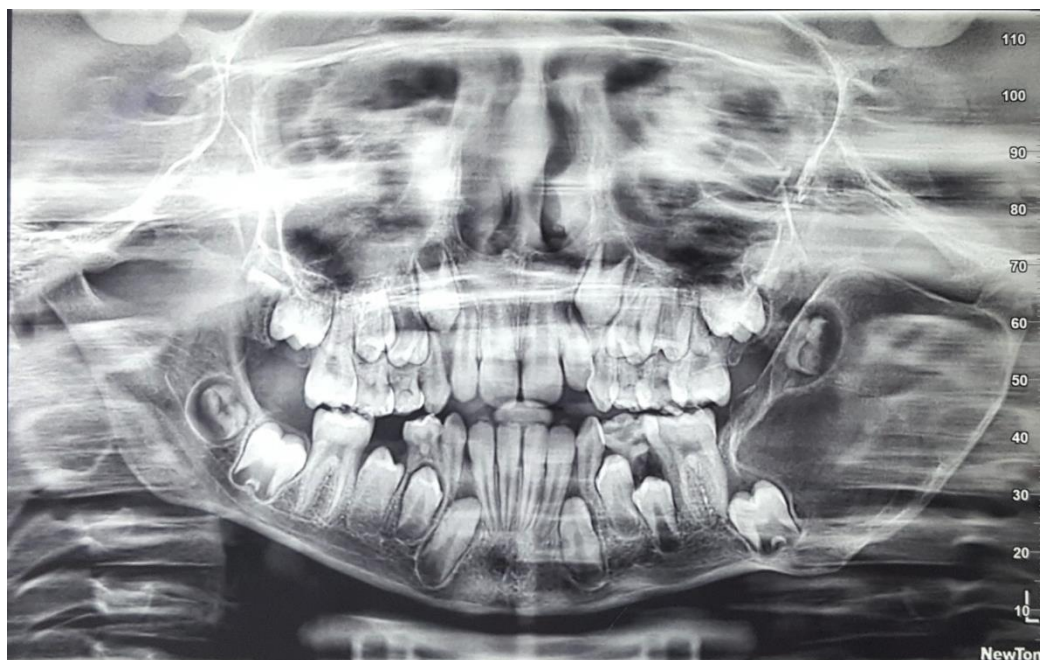
The decision was made to do enucleation of the lesion with dental germ for excisional biopsy under general anaesthesia. Parents of the child signed an informed written consent that included all details of the treatment, its benefits and potential risks, explained in a simple clear language to the parents, and also to the child in an appropriate manner.

The lesion was surgically exposed by extra-oral submandibular incision; bone of buccal cortical plate of posterior mandible was removed to expose the lesion, which was carefully removed as one piece with the tooth follicle. The inferior border of the mandible and the lingual plate of bone were preserved. Clinically, the excised lesion was well-defined rubbery to firm yellowish mass that measured 10× 10 cm **(Figure 4)**.

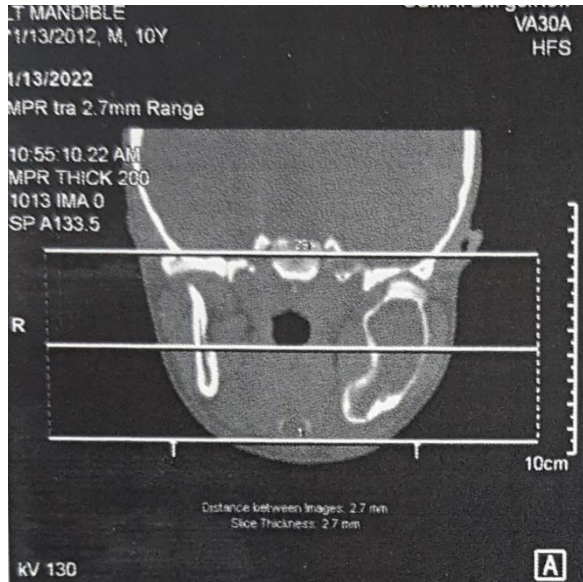
Histopathologic examination with Hematoxylin-eosin (H & E) staining showed proliferating fibroblastic cells with collagen stroma containing irregular foci of immature bony trabeculae **(Figure 5)**



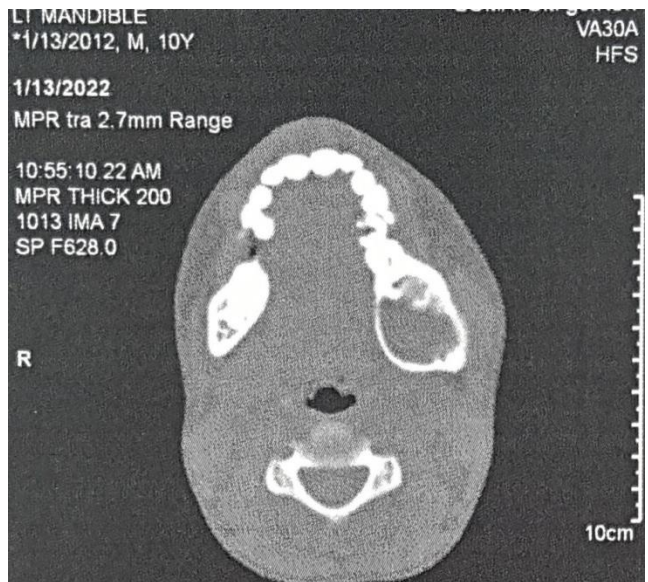
**Figure. 1:** A 10-years old boy with facial asymmetry on the left side



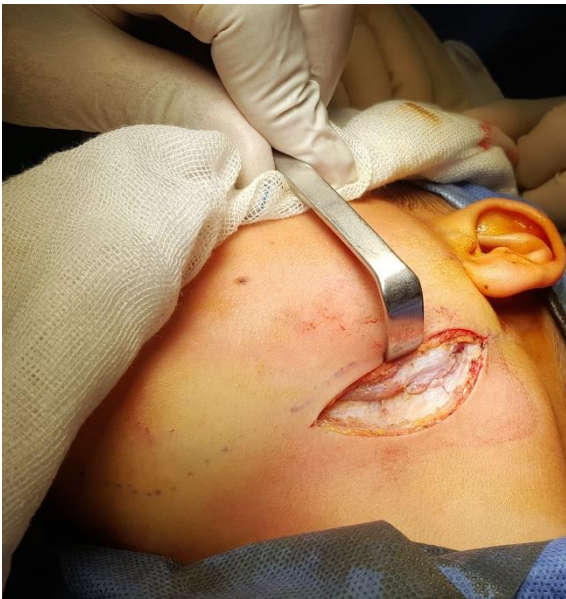**Figure. 2:** Preoperative panoramic image showing large expansile unilateral well defined corticated mixed lesion causing displacement of the tooth follicle of left 8 towards the coronoid process and displacement of the tooth follicle of the lower left 7 mesially.



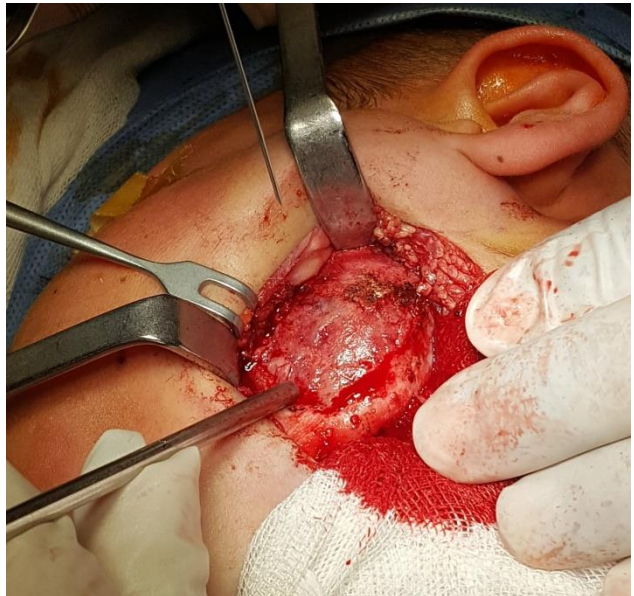
**Figure. 3- A:** Coronal CT



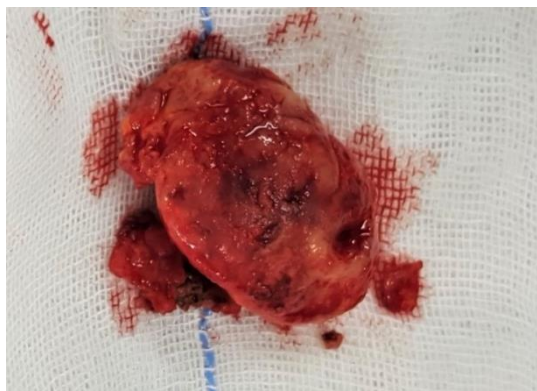**Figure. 3-B:** Axial CT



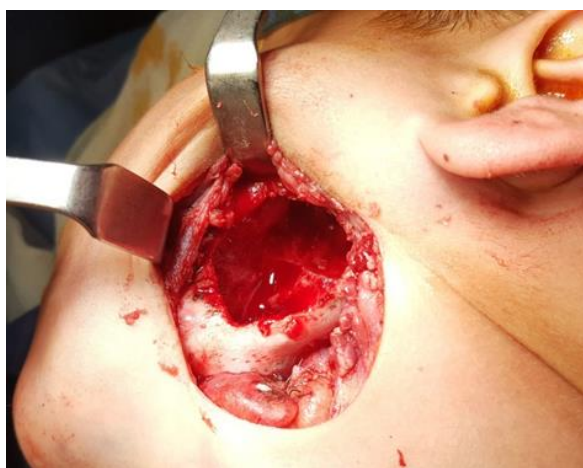**Figure. 4-A:** Surgical approach: Extra-oral Submandibular incision



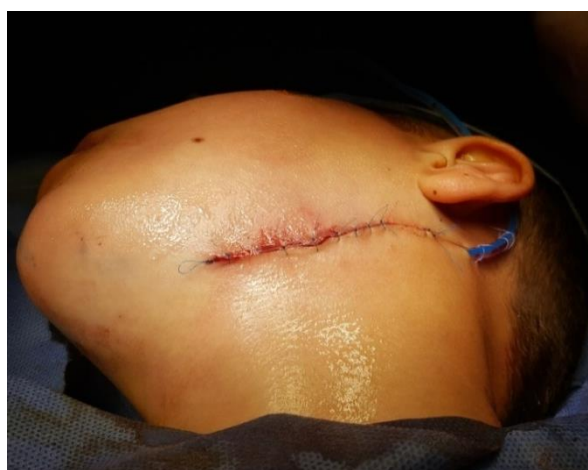**Figure. 4-B:** Lesion exposed after flap reflection and removal of buccal cortical plate of bone



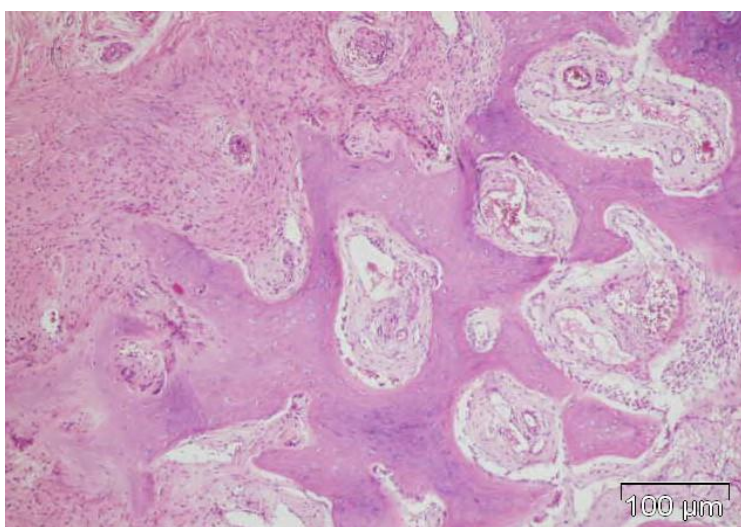
**Figure. 4-C:** Excised lesion with tooth germ



**Figure. 4-D:** After lesion removal



**Figure. 4-E:** Closure of Extra-oral Incision



**#Figure. 5:** H & E section showing proliferating fibroblastic cells with collagen stroma containing irregular immature bony trabeculae

## Discussion

Differential diagnosis for this lesion included dentigerous cyst, odontogenic keratocyst, central giant cell granuloma, fibrous dysplasia, odontogenic myxoma, odontogenic fibroma.

In the presented case, the patient is a child, and the diagnosis is based on clinical, radiological, and histological examination. Facial asymmetry was alarming to the parent.

Treatment modalities of FD include conservative surgery, radical excision and immediate reconstruction [4], and medical treatment with bisphosphonates [5].

Conservative surgical treatment was performed; the inferior border of the mandible and the lingual plate of bone were preserved, this, because the child is 10 years old; the mandible is still in a growth period. At this pediatric age, radical surgical excision will definitely affect the facial growth of the child. This coincides with Kruse et al [6], who recommended that FD should be treated as conservatively as possible.

## Conclusion

Conservative treatment for FD in children should be performed. Localized surgical excision of the lesion, followed by re-contouring is the most conservative approaches for the treatment of facial asymmetry. Follow-up should be maintained closely.

## Reference

1. Di Rocco C, Marchese E, Velardi F. Fibrous dysplasia of the skull in children. *Pediatr Neurosurg.* 1992; 18(3):117-26. doi: 10.1159/000120649. PMID: 1457370.
2. Delilbasi C, Deniz E, Ekici ID. Monostotic fibrous dysplasia of the mandible. *Oral Health Dent Manag.* 2014 Jun; 13(2):326-9. PMID: 24984642.
3. Fattah A, Khechoyan D, Phillips JH, Forrest CR. Paediatric craniofacial fibrous dysplasia: the Hospital for Sick Children experience and treatment philosophy. *J Plast Reconstr Aesthet Surg.* 2013 Oct; 66(10):1346-55. Doi: 10.1016/j.bjps.2013.05.031. Epub 2013 Jul 3. PMID: 23829958.
4. Chen M, Yang C, Fang B, Zhang S, Xu K. Treatment of hemimandibular fibrous dysplasia with radical excision and immediate reconstruction with free double costochondral graft. *J Oral Maxillofac Surg.* 2010 Aug; 68(8):2000-4. doi: 10.1016/j.joms.2009.09.035. Epub 2010 May 20. PMID: 20493608.

5. Becelli R, Perugini M, Cerulli G, Carboni A, Renzi G. Surgical treatment of fibrous dysplasia of the cranio-maxillo-facial area. Review of the literature and personal experience form 1984 to 1999. *Minerva Stomatol.* 2002 Jul-Aug; 51(7-8):293-300. PMID: 12434124.
6. Kruse A, Pieles U, Riener MO, Zunker Ch, Bredell MG, Grätz KW. Craniomaxillofacial fibrous dysplasia: a 10-year database 1996-2006. *Br J Oral Maxillofac Surg.* 2009 Jun; 47(4):302-5. Doi: 10.1016/j.bjoms.2009.01.008. Epub 2009 Mar 17. PMID: 19282072.