



## **Elimination of Post-Burn Deforming Scars of the Forearm by the Radial Musculocutaneous Flap or "Chinese Flap"**

Sahakyan Artavazd Bagrat, PhD <sup>1</sup>, Navoyan Artyom Gagik <sup>2</sup>, Mkhitarian Gayane Ashot <sup>\*3</sup>,  
Avagyan Svetlana Arthur <sup>4</sup>

1. Chief of Department of Plastic and Reconstructive Surgery, Heratsi Hospital Complex.
2. Plastic and Reconstructive Surgeon, Heratsi Hospital Complex.
3. Plastic and Reconstructive Surgery resident, Heratsi Hospital Complex, Yerevan State Medical University after Mkhitar Heratsi.
4. Plastic and Reconstructive Surgery resident, Heratsi Hospital Complex, Yerevan State Medical University after Mkhitar Heratsi.

**Corresponding Author: Mkhitarian Gayane Ashot**, Plastic and Reconstructive Surgery resident, Heratsi Hospital Complex, Yerevan State Medical University after Mkhitar Heratsi.

**Copy Right:** © 2022 Mkhitarian Gayane Ashot, This is an open access article distributed under the Creative Commons Attribution License, which permits unrestricted use, distribution, and reproduction in any medium, provided the original work is properly cited.

**Received Date: June 30, 2022**

**Published Date: July 10, 2022**

**Abstract**

*The submitted article on a clinical example, presents a variant of application of the “Chinese flap” on a nutritional pedicle from the radial artery pool, for reconstructive purpose of eliminating cicatricial deformities of the forearm, which led to extensor contracture.*

**Key words:** Musculocutaneous flap, "Chinese flap", deforming scars.

**Introduction**

In our Center for Plastic & Reconstructive Surgery and Microsurgery at the University Clinical Hospital No. 1, reconstructive and restorative operations were performed for various cicatricial deformities, followed by restoration of function and skin. In most cases, there were patients with post-burn soft tissue deformities. In order to replace the scar tissues of a defect, autologous tissues were used in the form of various flaps (ulnar flap, radial flap, sural flap, etc.). The above-mentioned flap is successfully used in complicated forms of cicatricial deformities, as a result of which contracture of this area develops. Each method of restoring of tissue defects is characterized by advantages and disadvantages. One of the main advantages of the chosen method, is the vascular pedicle, which is fed from the pool of the radial artery and the transposition method. Based on our experience and scientifically approved international literature data, the presented method can be considered more favorable in terms of flap volume preservation (minimization of marginal necrosis). However, this method also has its drawbacks, and research is ongoing in our department.

The human hand is the most active part of the upper limb and, therefore, is most often injured.

The problem of treatment of open injuries of the hand is relevant today.

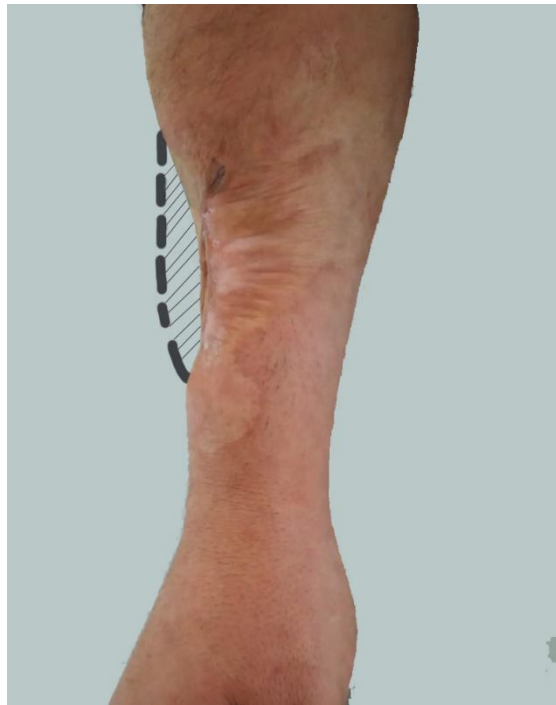**History reference:** For the first time, a free musculoskeletal flap of the volar surface of the forearm on the vascular pedicle from the radial artery was performed in China in 1978. As a consequence, this so-called "Chinese flap" was described by Yang et al. in 1981 and Song et al. 1982. Soon this method was adopted by European colleagues who visited China.

## Case

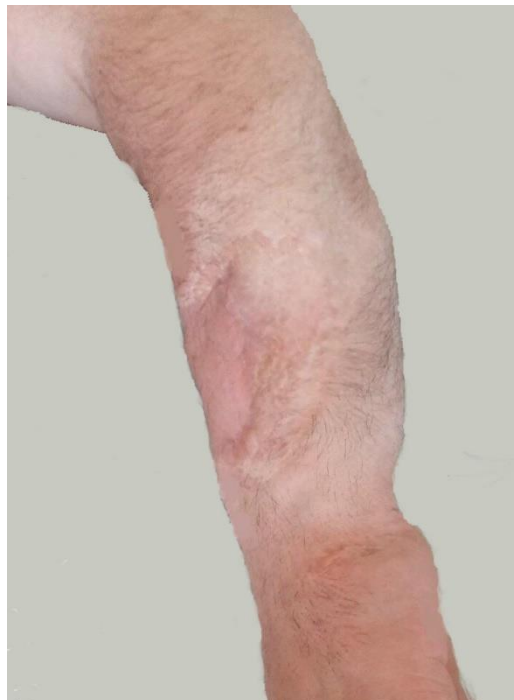A 35-year-old patient, a carpenter by profession, applied to the Center for Plastic & Reconstructive Surgery and Microsurgery at the University Clinical Hospital No. 1, with complaints of a deforming scar on the dorsal surface of the forearm, which arose as a result of an electrical burn during work about 5 years ago. The patient received primary treatment at the burn center. According to the patient, over the past 6 months, he drew attention to incomplete flexion of the hand due to gross cicatricial changes in the forearm.

When examining the patient, deforming scars 15 x 25 cm in size were found on the border of the middle and lower 1/3 of the dorsal surface of the forearm, which stretch to the radial side. The appearance of scars is in the form of strands of pale pink color, dense and immovable to the touch. During the preoperative preparation, preliminary clinical and laboratory studies were carried out, including duplex scanning of the vessels of the forearm. The patient was prepared for a planned operation.

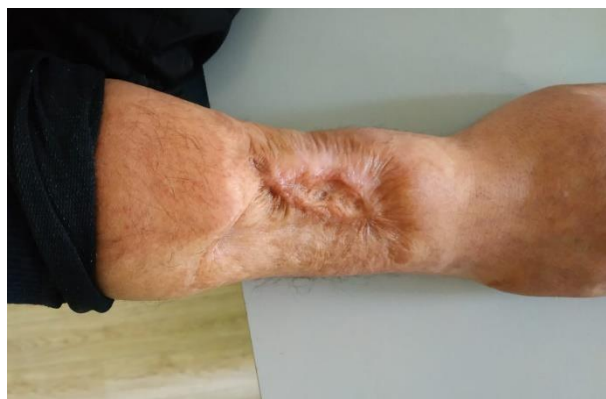Under general anesthesia, a tourniquet was placed on the border of the upper and middle 1/3 of the arm. After pre-treatment of the skin with an antiseptic solution, an incision was made along the edges of the scars, which were removed by an acute method. Afterwards, multiple adhesions were found between the extensors of the fingers and hand and skin changes were identified. All pathological tissues were carefully excised in the acute way and freed from adhesions. Instrumental excursion is positive. The resulting soft tissue defect in the posterior surface of the forearm was 4.3 x 7.5 cm. Intraoperatively, it was decided to close the defect with a musculocutaneous flap. In the region of the posterior surface of the right hand, proximal to the defect, a preliminary marking of the forthcoming flap was made, the dimensions of which correspond to the dimensions of the defect. An incision was made along the marking zones with blunt and sharp ways, soft tissues (skin, subcutaneous tissue, muscles) were separated, the radial artery was identified and mobilized, on which ligatures were placed (2 on the proximal and 1 on the distal side) and cut in the area of the upper 1/3 of the flap. The blood supply of the flap was carried out on the distal pedicle of the radial artery. Within 10 minutes, the blood supply to the flap remained satisfactory and it was decided to continue the planned operation. The composition of the flap also included a part of the brachioradialis muscle, the blood supply of which was also satisfactory. The formed musculocutaneous flap, which is approximately 8 x 5 cm in size, was rotated around the vascular pedicle by 165 degrees in the region of the recipient zone. The edges of the flap were sutured to the edges of the wound, the vascular pedicle was checked, there was no torsion. The donor area was closed by primary tension with interrupted sutures. The edges of the flap were compared and sutured with rare skin sutures. During the entire operation, the blood supply to the flap was stable. In the postoperative period, the wound healed by primary intention, the sutures were removed on the 13th day. Active movement of the fingers and hand was launched on the 7th day after the operation. A month after the operation, active flexion of the fingers and hand was fully restored; there were no adhesions in the area of the flap.



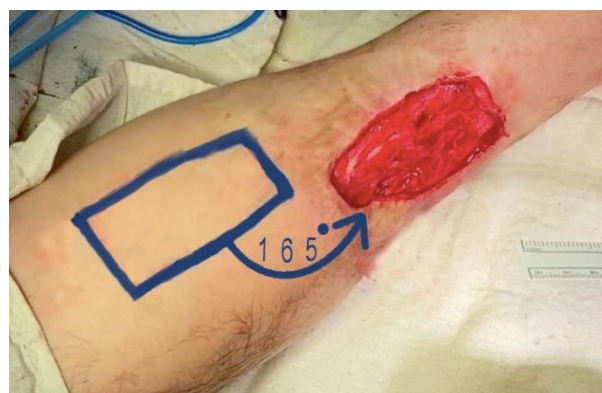
**Fig. 1:** Schematic marking of the defect



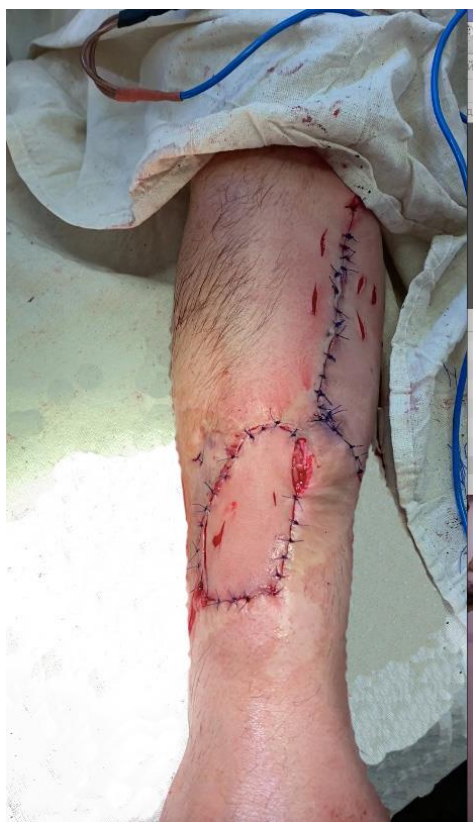**Fig. 2:** Visual result of the defect area



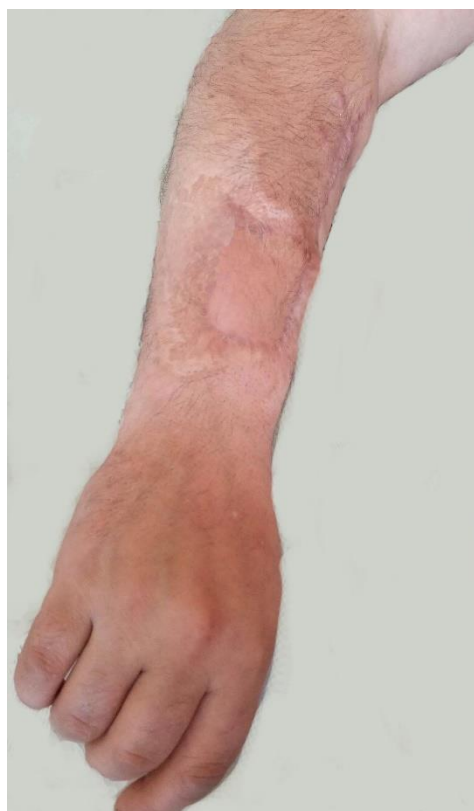**Fig. 3:** Preoperative picture



**Fig. 4:** Marking of the future flap



**Fig. 5:** Result immediately on the operating room



**Fig. 6:** Flap after 2 months

## Discussion

In the reconstructive ladder, split-thickness skin graft (STSG) or full-thickness skin graft (FTSG) are mentioned as a primary approach for contracture release. However, based on the data from our practice and experience, in those cases when the priority was given to STSG or FTSG, the probability of contracture relapse was significantly high.

The application of flaps with sufficient size, durability, flexibility and vascularity are considered as an essential and smart decision for contracture relapse prevention.

Autologous tissue transfer surgery can be performed during a single- stage operation, however it required special surgical skills, availability of well-organized team and professional postoperative care.

In the above mentioned case we give our priority on the application of radial musculocutaneous flap, based on the provides abundant tissue, with a vigorous vascularity and the distance of the donor area from recipient defect zone, so that it give as an opportunity to use the flap in a pedicled form. Due to sacrifice of the radial artery, the drawback of this flap is the potential vascular morbidity in the forearm.

In our reviewed case we skip the other common shortcoming of radial flap, related to the donor side closure, as in our case the donor side was primarily closed with interrupted sutures.

## Conclusion

The described case proves the need for complex diagnostics and treatment at different stages of development of scars and contractures. We have performed observation, in which the correct diagnosis, as well as a consistent combination of correct surgical and conservative treatment, together with specially designed procedures, made it possible to obtain a proper aesthetic and functional outcome in a young patient with a subsequent return to professional activity.

## References

1. УДК: 617.576:616.74-001.4:617-089.843 Бадюл П.А., Слесаренко С.В. Стаття опублікована в журнале: Хірургія України.- 2014.- №3.- С. 25-32
2. FLAPS AND RECONSTRUCTIVE SURGERY 2nd Edition, Fu-Chan Wei MD, FACS, Samir Mardini MD,2017, p.525
3. Я. ЗОЛТАН ОПЕРАЦИОННАЯ ТЕХНИКА И УСЛОВИЯ ОПТИМАЛЬНОГО ЗАЖИВЛЕНИЯ РАН ТРЕТЬЕ ИЗДАНИЕ НА РУССКОМ ЯЗЫКЕ. Направление линий разрезв и швов в области предплечья и на верхней конечности.

4. Ahmad Andourah, New Pedicle for the Chinese Flap, Plastic, Reconstructive and Aesthetic Surgery Transactions of the 11th congress of the International Confederation / International Confederation for Plastic, Reconstructive and Aesthetic Surgery, 1995, p.372-373
5. Chinese forearm flap technique in thumb injury: a case report Zainarda\*, A. A. Gde Yuda Asmara, Putu Suehandika Caksana, International Journal of Research in Medical Sciences Zainarda et al. Int J Res Med Sci. 2018 May;6(5): p.1782.
6. Uygur F, Sever C, Evinç R, Ulkür E, Duman H. Reverse flow flap use in upper extremity burn contractures. Burns. 2008 Dec;34(8):1196-204. doi: 10.1016/j.burns.2008.05.019. Epub 2008 Sep 19. PMID: 18804917.