



CRS and HIPEC in peritoneal metastasis from cervical cancer. Preliminary data from a retrospective study.

Spiliotis John ^{*1,2}, Kopanakis Nikolaos ³, Iavazzo Christos ³, Raptis Apostolos ¹, Gianniri Mairy ¹,
Karachalios Dimitrios ², Margari Harris ¹

1. Department of Surgical Oncology and HIPEC, Athens Medical Centre, Athens, Greece.
2. Department of Surgical Oncology and HIPEC, European Interbalkan Medical Centre, Thessaloniki, Greece.
Kopanakis Nikolaos, Department of Surgical Oncology, Metaxa Cancer Hospital, Piraeus, Greece.
3. Department of Surgical Oncology, Metaxa Cancer Hospital, Pireus, Greece

Corresponding Author: Spiliotis John, MD, PhD, Director Surgical Oncologist

Copy Right: © 2022 Spiliotis John, This is an open access article distributed under the Creative Commons Attribution License, which permits unrestricted use, distribution, and reproduction in any medium, provided the original work is properly cited.

Received Date: August 22, 2022

Published Date: September 01, 2022

Abstract

Introduction: Peritoneal spread of gastrointestinal and gynecological malignancies such as ovarian and endometrial cancer is a well-known final stage of the above-mentioned diseases. Peritoneal metastasis from cervical cancer is rare and has its prevalence has ranged in autopsies series from 5% to 27%. Cytoreductive surgery followed by HIPEC, has gained ground recently in the treatment of peritoneal carcinomatosis from gynecologic malignancies but there is no data on their efficiency in the treatment of peritoneal disease from cervical cancer.

Patients and Methods: A retrospective study was performed in our medical records, of all patients with cervical cancer and peritoneal metastasis treated with CRS and HIPEC since 2006. Survival and Disease Free survival were studied in a total of 30 patients.

Results: Cytoreductive surgery followed by HIPEC offered an overall survival benefit in women with cervical cancer and peritoneal metastasis.

Conclusions: Preliminary data from our retrospective study showed that CRS and HIPEC might be a useful weapon in the treatment of peritoneal metastasis from cervical cancer. Prospective studies are required to validate our results.

Keywords: *Cervical cancer, Peritoneal carcinomatosis, HIPEC.*

Introduction

The combination of cytoreductive surgery (CRS) and HIPEC, is already the standard care for selected patients with pseudomyxoma peritonei and peritoneal mesothelioma¹. It also seems to improve survival in selected patients with gastrointestinal malignancies². In the recent years the use of CRS and HIPEC has emerged as an important tool in the hands of surgeons that treat peritoneal metastasis from gynecologic malignancies. Patients with peritoneal carcinomatosis from ovarian and endometrial cancer are offered a prolonged overall and disease free survival³⁻⁵.

Cervical carcinoma is the fourth most common cancer among women worldwide⁶. The predominant histological type is squamous cell carcinoma meanwhile adenocarcinoma and adenosquamous cell carcinoma represent 10-15%. Other or unspecified histology represent the remaining 10-15%.

In high-income countries, incidence and mortality of cervical cancer have dropped over the last years since the introduction of formal screening programmes⁸. Early-stage disease carries a favorable prognosis due to advances in surgical techniques, radiotherapy and chemotherapy. Nevertheless, for women with metastatic or recurrent disease, the overall prognosis remains poor. Typical metastatic or recurrent sites are the pelvis and lymph nodes, but peritoneal metastasis have also been described with a very low prevalence, about 5%⁹. A large population study in Netherlands confirmed that 1% of the patients with cervical cancer, presented with peritoneal metastasis. The mean age at diagnosis of only advanced stage patients was 51.4 years. Thirty-eight percent had an adenocarcinoma and 44% had a squamous cell carcinoma. Fifth-five percent of patients had PM without other distant metastases¹⁰.

Radical surgery and chemoradiotherapy are the treatments of choice in advanced recurrent or metastatic disease though still median survival time is only 8 to 13 months¹¹. To the best of our knowledge, there is no data in literature for the treatment of peritoneal metastasis from cervical cancer with the use of cytoreductive surgery (CRS) and HIPEC.

Patients and Methods

A retrospective analysis of our data was performed. The research was conducted on patient's medical record and a meticulous follow up. From 2006 to 2019 a total of 30 patients were treated for peritoneal carcinomatosis from cervical cancer. Their mean age was 54 years (table 1).

Synchronous onset of peritoneal carcinomatosis with cervical cancer was diagnosed in 8 patients (26%). Squamous cell carcinoma (SCC) was the predominant histological type accounting for 60% of our cases (18pt), meanwhile adenocarcinoma and adenosquamous cell carcinoma was the histological diagnosis in 10 patients.

Patients were divided in 2 distinctive groups in relation to the treatment strategy. The groups were randomized in time of surgery. In the first group patients were treated with cytoreductive surgery plus HIPEC, with carboplatinum and paclitaxel, meanwhile the second group was offered cytoreductive surgery alone. Multi-viscerectomies were performed in cases of extended peritoneal disease and the peritoneal cancer index (PCI) was calculated with a maximum score of 15.

Results

The median overall survival of all patients in our study was 30 months. The CRS+HIPEC group presented a median overall survival of 50 months mean while survival in the CRS group was 24 months (Tab 2). The long-rank test demonstrated a statistically significant difference in overall between these 2 groups (fig 1).

		CRS + HIPEC	CRS	Total
Age	N	12	18	30
	Mean	54.6	53.8	54.1
	Standard Deviation	11.1	7.8	9.1
	Minimum	29	44	29
	Maximum	70	67	70

Table 1. Patients Mean Age

Group	Disease Free Survival in months (95% confidence interval)
CRS + HIPEC	38,00±4,817 (28,559-47,441)
CRS	12,00±1,571 (8,920-15,080)
Overall	34,00±12,402 (9,691-58,309)

Table 2. Disease Free Survival

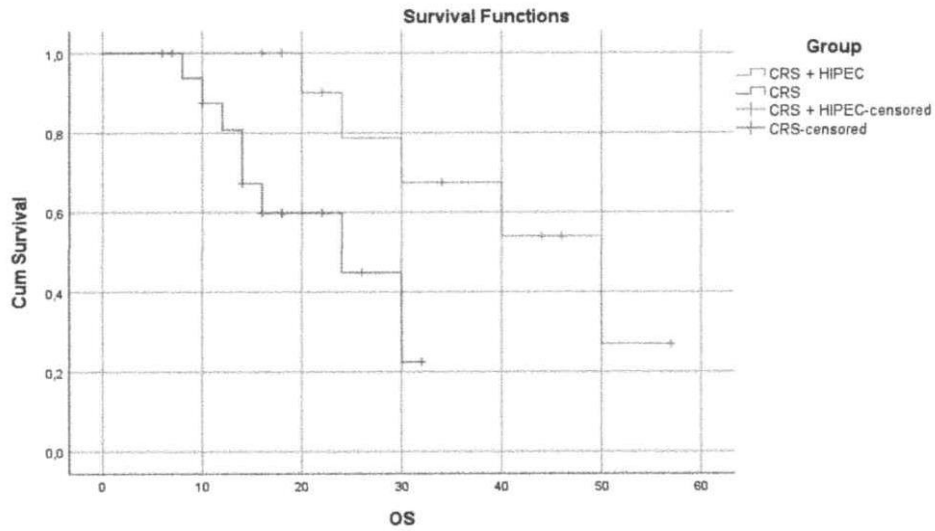


Figure 1. Overall survival in groups

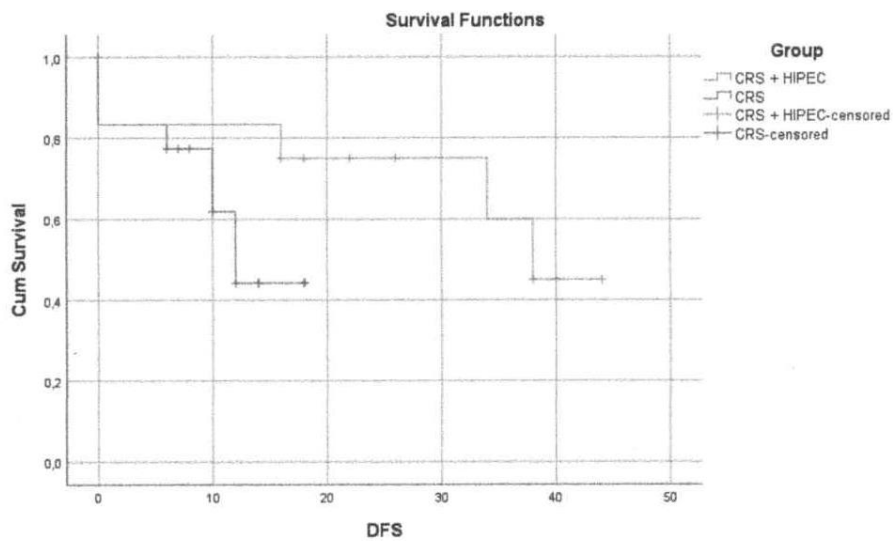


Figure 2. Disease Free Survival in groups

Discussion

Cervical cancer was the leading cause of cancer death for women in the United States before the regular use of Pap tests that changed the natural history of the disease the last 40 years. The average age of diagnosis is 50 and the 5-year survival rate is 66%¹². In metastatic cervical cancer survival rates drops to 16,5%¹³. Two types of metastasis, hematogenous and lymphatic, relate to different survival rates and treatment options.

Conventional treatment, for patients with early or locally advanced cervical cancer includes surgery, chemotherapy and radiotherapy. From the other hand, there is no standard treatment for metastatic disease due to its heterogeneous manifestations¹¹. Typical manifestations of recurrent cervical cancer are pelvic masses and lymphadenopathy. Peritoneal carcinomatosis and solid organ metastasis are less common but can occur in a small percent of patients¹⁴.

A large retrospective population study conducted in Netherlands between 1989 and 2015, identified all female patients diagnosed with ovarian, endometrial and cervical cancer¹⁰. One percent of cervical cancer patients presented with peritoneal metastasis (PM). Thirty-eight percent had an adenocarcinoma and 44% had a squamous cell carcinoma. Fifty-five percent of patients had PM without other distant metastases. Authors concluded that the risk of peritoneal metastasis was higher in adenocarcinoma compared to squamous cell carcinoma¹⁰.

Patients treated with cytoreductive surgery (CRS) and HIPEC, in our study, presented a better overall survival but not a statistical different disease-free survival time in comparison with the CRS group. We used carboplatinum and paclitaxel for HIPEC that is the same protocol used for PM from ovarian cancer. HIPEC duration was one hour, and all patients had a meticulous follow up after being discharged from the hospital.

Conclusion

Peritoneal carcinomatosis from cervical cancer is a rare and fatal manifestation of the disease. Treatment is no standardized and there is no data in literature about the use of cytoreductive surgery and HIPEC. Based on our experience¹⁵⁻¹⁷ on the use of HIPEC in peritoneal carcinomatosis from gastrointestinal malignancies, ovarian and endometrial cancer, we treated carcimomatosis from gastrointestinal malignancies, ovarian and endometrial cancer, we treated patients with peritoneal spread of cervical cancer, with extended cytoreductive procedures. When complete macroscopic elimination of the disease was feasible (R0), we performed HIPEC with carboplatinum and paclitaxel

for an hour. Elaboration of the first data, demonstrated an overall survival benefit for patients treated with CRS and HIPEC.

Weak points of our study include the small number of patients, patient's randomization process and chemotherapeutic drugs choice. Prospective future studies randomization process and chemotherapeutic drugs choice. Prospective future studies are necessary in order to consolidate the value of this therapeutic choice in the treatment of peritoneal metastases from cervical cancer.

References

1. Li Y, Yu Y, Liu Y. Report on the 9th International Congress on peritoneal surface malignancies. *Cancer Biol Med*. 2014;11:281-4.
2. Sugarbaker PH. The seven best from PSOGI 2016. *Ann Surg Oncol*. 2017;24:870-4.
3. Spiliotis J, Halkia E, Lianos E, et al. Cytoreductive surgery and HIPEC in recurrent epithelial ovarian cancer: a prospective randomized phase III study. *Ann Surg Oncol* 2015;22:1570-5.
4. W.J. van Driel, S.N. Koole, K. Sikorska et al. Hyperthermic Intraperitoneal Chemotherapy in Ovarian Cancer. *N Engl J Med* 2018;378:230-40.
5. Cornali T, Sammartino P, Kopanakis N et.al. Cytoreductive Surgery Plus Hyperthermic Intraperitoneal Chemotherapy for Patients with Peritoneal metastasis from Endometrial Cancer. *Ann Surg Oncol*. 2018 Mar;25(3):679-687.
6. Parkin DM, Bray FI, Devesa SS: Cancer burden in the year 2000. The global picture. *Eur J Cancer* 2001;37 Suppl 8:S4-66.
7. Vizcaino AP, Moreno V, Bosch FX et al. International trends in incidence of cervical cancer: II. Squamous-cell carcinoma. *Int J Cancer* 2000;86:429-435.
8. Paul A Cohen, Anjua Jhingran, Ana Oaknin et al. Cervical Cancer. *Lancet* 20019 Jan 12;393(10167):169-182.
9. Drescher CW, Hopkins MP, Roberts JA. Comparison of the pattern of metastatic spread of squamous cell cancer and adenocarcinoma of the uterine cervix. *Gynecol Oncol* 1989;33:340-343.

10. Lara Burg, Maite Timmermans, Maaïke van der Aa et al. Incidence and predictors of peritoneal metastases of gynecological origin: a population-based study in the Netherlands. *J Gynecol Oncol.* 2020;31(5):258.
11. Haoran Li, Xiaohua Wu, Xi Cheng. Advances in diagnosis and treatment of metastatic cervical cancer. *J Gynecol Oncol*, 2016;27(4):e43.
12. National Institutes of Health. Cervical Cancer. NIH Consensus Statement. 1996;14(1):1-38.
13. Ferlay J, Steliarova-Foucher E, Lortet-Tieulent J et al. Cancer incidence and mortality patterns in Europe: estimates for 40 countries in 2012. *Eur J Cancer* 2013;49:1374-403.
14. Fulcher A, O'Sullivan S, Segreti E et al. Recurrent cervical carcinoma: Typical and Atypical manifestations. *Radiographics* 1999;19:S103-S116.
15. Spiliotis J, Iavazzo C, Fotiou A et al. Upfront or intermediate treatment of advanced ovarian cancer patients with cytoreduction plus HIPEC: Results of a retrospective study. *J Surg Oncol.* 2021;123(2):630-637.
16. Spiliotis J, Kalles V, Kyriazanos I et al. CRS and HIPEC in patients with peritoneal metastasis secondary to colorectal cancer: The small-bowel PCI score as a predictor of survival. *Pleura Peritoneum.* 2019;30:4(4):20190018.
17. Spiliotis J, Kopanakis N, Terra A et al. Cytoreductive surgery and HIPEC for peritoneal metastasis. Justified hope or desperate illusion? Fifteen years of experience from a Greek Peritoneal Surface Malignancy cancer. ID: 1025170 (In press).