



## **Tracheal Schwannoma Presenting as Acute Respiratory Distress**

Dr Ranjith Kumar. MD\*, Dr B Anirudh Kumar MD <sup>1</sup>, Dr Venkateswara Reddy T MD <sup>2</sup>

- 1. Interventional Pulmonologist, Dr A&N Lung Speciality Clinic.*
- 2. Interventional Pulmonologist, SVS Medical college and Hospital.*

**\*Correspondence to:** Dr Ranjith Kumar, Internal Medicine, Ozone Hospitals.

### **Copyright**

© 2023 **Dr Ranjith Kumar**. This is an open access article distributed under the Creative Commons Attribution License, which permits unrestricted use, distribution, and reproduction in any medium, provided the original work is properly cited.

Received: 23 June 2023

Published: 01 July 2023

### ***Abstract***

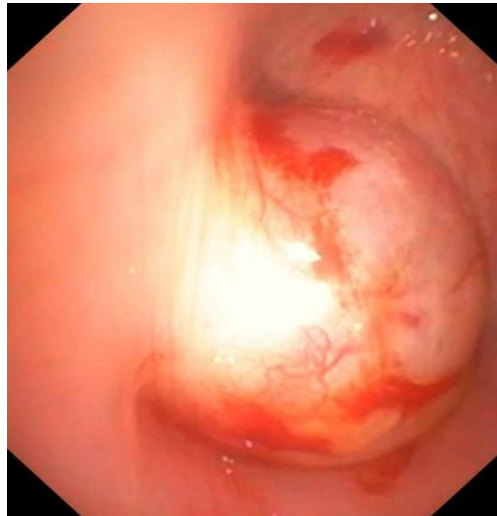
*Abstract: Tracheal schwannomas are rare, benign tumors of the trachea that can present with a variety of symptoms depending on the location and size of the tumor. Here we report a case of a 29-year-old female who presented with acute onset of breathlessness and wheezing. CT chest revealed an intra-tracheal mass lesion causing narrowing of airway lumen, and bronchoscopy revealed a smooth vascular dumbbell-shaped tumor in the subglottic region completely occluding the tracheal lumen. The tumor was resected using a combination of electrocautery snare and cryoprobe, with mild bleeding that was controlled with APC. Histopathological examination confirmed the diagnosis of tracheal schwannoma. This case highlights the importance of considering tracheal schwannoma in the differential diagnosis of patients presenting with acute respiratory distress.*

### **Introduction**

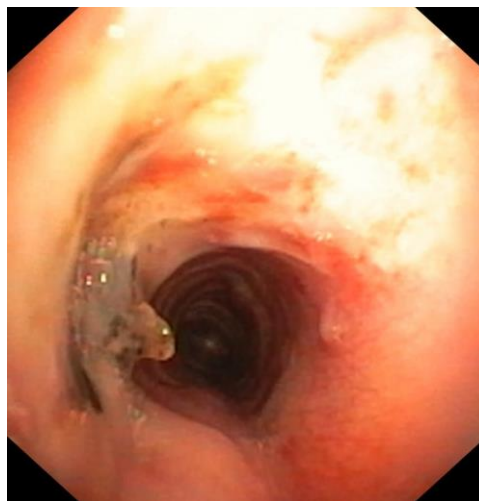
Tracheal schwannomas are rare tumors that originate from Schwann cells in the nerve sheath of the trachea. They account for less than 5% of all primary tracheal tumors. Tracheal schwannomas are mostly benign and slow-growing, and they can remain asymptomatic for several years. However, symptoms may arise when the tumor grows large enough to compress the tracheal lumen, causing respiratory distress.

### **Case Presentation**

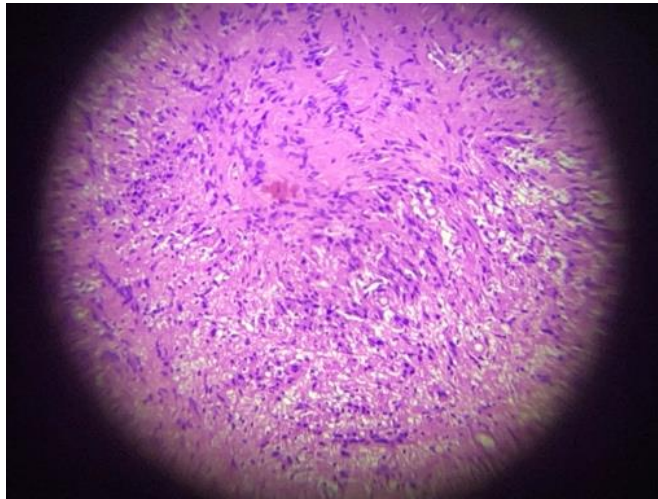
A 29-year-old female presented to the emergency department with complaints of breathlessness and wheeze since one week. Her breathlessness worsened on lying down posture. On examination, she had severe wheeze bilaterally, and her sats at room air were 85%. A CT chest was performed immediately which showed an intra-tracheal mass lesion causing narrowing of the airway lumen. She was then subjected to bronchoscopy, which revealed a smooth vascular dumbbell-shaped tumor in the subglottic region completely occluding the tracheal lumen. The tumor was resected using a combination of electrocautery snare and cryoprobe, with mild bleeding that was controlled with APC. Histopathological examination confirmed the diagnosis of tracheal schwannoma.



**Fig 1** – Bronchoscopic view of the tumor



**Fig 2** – Post Tumor removal – showing tracheal lumen patency



**Fig 3** - HPE - has shown polypoidal tissue bit comprising of spindle shaped cells arranged in hypocellular and hypercellular areas. Few areas have shown verocay bodies. These cells have blunted to pointed nucleus and moderate cytoplasm. The above features are s/o Spindle cell Lesion-Schwannoma

## Discussion

Tracheal schwannomas are rare tumors that can present with a variety of symptoms depending on the location and size of the tumor<sup>1</sup>. They are usually benign and slow-growing, and symptoms may not appear until the tumor has grown large enough to compress the tracheal lumen. The definitive diagnosis of tracheal schwannoma is made by histopathological examination, which confirms the presence of Schwann cells in the tumor<sup>1</sup>. Treatment options for tracheal schwannomas include surgical resection, endoscopic removal, and radiation therapy<sup>2</sup>. In the present case, the tumor was successfully removed using a combination of electrocautery snare and cryoprobe, with mild bleeding that was controlled with APC.

## Conclusion

Tracheal schwannomas are rare tumors that should be considered in the differential diagnosis of patients presenting with acute respiratory distress. Prompt diagnosis and treatment are essential to prevent further complications and improve patient outcomes. Surgical resection is the preferred treatment modality for tracheal schwannomas, and endoscopic removal can be considered in select cases.

## References

1. Isaac BT, Christopher DJ, Thangakunam B, Gupta M. Tracheal schwannoma: Completely resected with therapeutic bronchoscopic techniques. *Lung India*. 2015 May-Jun;32(3):271-3. doi: 10.4103/0970-2113.156252. PMID: 25983416; PMCID: PMC4429392.
2. Hamouri S, Novotny NM. Primary tracheal schwannoma a review of a rare entity: current understanding of management and followup. *J Cardiothorac Surg*. 2017 Nov 28;12(1):105. doi: 10.1186/s13019-017-0677-2. PMID: 29183345; PMCID: PMC5706167.

