



Case Report- Rare case of very high procalcitonin levels without bacterial infection secondary to immune reconstitution inflammatory syndrome (IRIS) in non-HIV Tuberculosis patient

Dr Imliwati aier ^{*1}, Dr Puneet Tyagi ², Dr Deepen Sharma ³, Dr Rohit Kumar ⁴

1. *Consultant, critical care medicine, graphic era institute of medical sciences, Dehradun.*
2. *Consultant, Pulmonary Medicine, Graphic Era institute of medical sciences.*

***Correspondence to:** Dr Imliwati aier, Consultant, critical care medicine, graphic era institute of medical sciences, Dehradun.

Copyright

© 2023 **Dr Imliwati aier**. This is an open access article distributed under the Creative Commons Attribution License, which permits unrestricted use, distribution, and reproduction in any medium, provided the original work is properly cited.

Received: 11 July 2023

Published: 01 August 2023

Abstract

A case of 35-year-old seronegative woman with disseminated Koch's (pulmonary and central nervous system) who developed immune reconstitution inflammatory syndrome on treatment with anti-tuberculosis therapy presenting with very high procalcitonin (PCT) levels is reported. The clinical presentation and laboratory tests were suggestive of sepsis, but no infectious etiology was found. Clinical suspicion of IRIS was confirmed after marked improvement with corticosteroids. This case may help us to consider biomarkers like procalcitonin in diagnosis of IRIS. This case also strengthens the fact that very high procalcitonin does not always indicate infection.

Keywords: *Raised procalcitonin, false high procalcitonin causes, immune reconstitution inflammatory syndrome (IRIS), presentation of IRIS.*

Introduction

Procalcitonin is a serum biomarker that helps distinguish bacterial infection from other causes of infection. It can serve as a helpful adjunct to clinical judgment for guiding antibiotic therapy and resolving diagnostic uncertainty whose results can be obtained in hours or less (1). Procalcitonin is more specific for bacterial infections than other inflammatory markers, such as white blood cell count, erythrocyte sedimentation rate and C-reactive protein (2).

However, false positives can still occur in cases of severe trauma, cardiac arrest or circulatory shock, surgery, burns, pancreatitis, and intracranial hemorrhage, possibly due to gut translocation of lipopolysaccharide or other bacterial products (3), (4). Other etiologies of false positives are - severe liver disease, chronic kidney disease, medullary thyroid cancer and other neuroendocrine tumors, Kawasaki disease, malaria and invasive *Candida* infections, aspergillosis, mucormycosis and coccidioidomycosis.

Procalcitonin may not rise in contained localized infections such as tonsillitis, sinusitis, cystitis, uncomplicated skin/soft tissue infections, abscesses, or empyema (5).

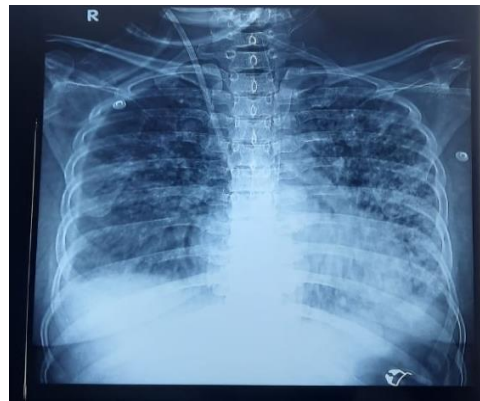
IRIS is also an inflammatory condition in the body like above mentioned causes. Elevated PCT levels secondary to IRIS has never been reported. We report the case of very high procalcitonin levels without bacterial infection secondary to immune reconstitution inflammatory syndrome (IRIS) in non-HIV Tuberculosis patient.

Case Summary

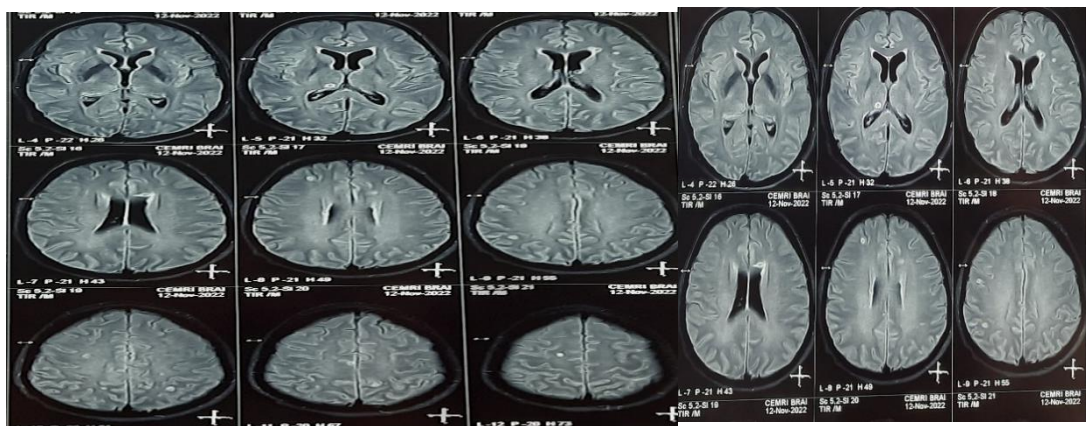
35-year-old female presented with complaints of low-grade fever for last 2 months associated with decreased appetite and weight loss, shortness of breath and cough for 10 days. There has been history of multiple hospitalization (twice) in last two months with the same complaints. she also received 2 units of packed red blood cells during those admissions. On arrival patient was severely dyspneic with oxygen requirement of 10 liters/min. Chest x-ray showed bilateral consolidation with left sided pleural effusion. Blood investigations showed serum creatinine of 6.7, urea 178, hemoglobin 6.8, TLC 20.1, albumin 2.8, procalcitonin 2.6. Patient was intubated after failed NIV trial and was empirically started on meropenem. She required vasopressors and multiple dialysis sessions to correct her metabolic acidosis. Provisional diagnosis of ? Pulmonary Koch's with secondary bacterial infection with acute kidney injury was made. With worsening of PaO₂/FiO₂ ratio less than 150, she also received prone ventilation.

Pleural fluid reports were suggestive of exudative in nature with ADA (adenosine deaminase) of 40.6. On 7th day, bronchoscopy was done for BAL (bronchoalveolar lavage) which detected mycobacterium tuberculosis. Patient was started on isoniazid, Rifampicin, ethambutol & pyrazinamide on alternate day as her renal functions were deranged. Urine culture grew *Pseudomonas aeruginosa* and accordingly antibiotics were modified. Procalcitonin was 4.85 on 8th day of hospitalization. Improvement was expected after targeted antibiotic therapy but patient continued to have fever spikes, high oxygen requirement and incoherence despite off sedation. On the 12th day, repeat procalcitonin showed a high value of 496 with the record >905 the next following day. Repeat cultures were negative. CE (contrast enhanced) MRI Brain was done on day 13 was suggestive of multiple tuberculomas. Patient was started on Dexamethasone 0.3 mg/kg iv considering the possibility of IRIS. On day 16 procalcitonin level decrease to 140 with significant clinical and neurological improvement. On day 25 her procalcitonin further decrease to 2.6. After combined

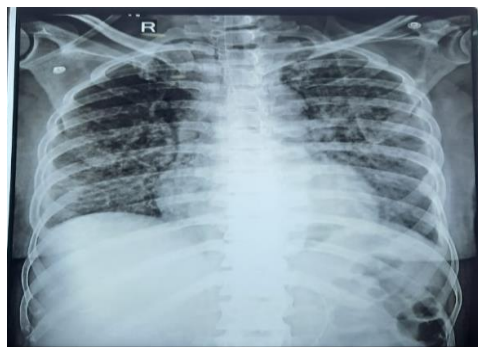
treatment of ATT and steroid for a month, patient showed drastic improvement with self-ambulation and was able to maintain oxygenation on room air.



Chest x ray at initial presentation



MRI brain showing multiple ring enhancing lesions- tuberculomas



Chest xray at day 26

Discussion

Immune reconstitution inflammatory syndrome describes a collection of inflammatory disorders associated with paradoxical worsening of pre-existing infectious process following the initiation of anti-retroviral therapy (ART) in HIV infected individuals (Paradoxical IRIS). Pre-existing infections in individuals with IRIS may be unmasked by the host's regained capacity to mount an inflammatory response (unmasking IRIS) (6). Two other types of IRIS have also been defined in the literature- Cryptic IRIS and Autoimmune IRIS. IRIS can also occur in a non-HIV infected individual with response to anti tubercular therapy. IRIS is not specific for any organism or ART and is not unique to HIV alone. Certain pathogens such as *Mycobacterium tuberculosis*, *mycobacterium avium* complex, Cytomegalovirus, *pneumocystis jirovecii*, herpes simplex virus, *candida albicans*, Epstein-barr virus, *histoplasma*, hepatitis B virus, human herpes virus 8 have also been found to be associated with IRIS (7). Several synonyms of IRIS exist such as immune recovery disease, immune restoration disease, immune rebound illness, steroid withdrawal disease etc. (8).

In healthy individuals, procalcitonin synthesis is restricted to thyroid neuroendocrine cells and the protein is not released into the blood until it is broken down into mature form that is, calcitonin (9). In cases of systemic inflammation caused by bacterial infection, procalcitonin synthesis occurs due to endotoxins, tumor necrosis alpha, interleukin-1-beta and interleukin-6 in mostly all tissues and is released into blood. Serum procalcitonin levels rise within two to four hours of an inflammatory stimulus, typically peaking within 24 to 48 hours and levels plateau. With resolution of inflammation, procalcitonin levels decline by about 50 percent every 1 to 1.5 days (10).

Prior to the emergence of HIV infection, an IRIS-like paradoxical inflammatory response was known to occur in some patients treated for tuberculosis. It is usually characterized by fever, malaise, weight loss, and worsening respiratory symptoms. Transient worsening of radiographic abnormalities, including new parenchymal opacities and progressive intrathoracic lymph node enlargement may also occur in such patients. Rarely it may progress to severe respiratory compromise and adult respiratory distress syndrome (11).

The mechanism for IRIS in TB appears to be immune mediated (12). In our case also, patient had worsening respiratory symptoms despite targeted antibiotic therapy and repeat cultures were negative. Patient was already given DVT prophylaxis, and any new cardiovascular event was ruled out. Repeated serum

procalcitonin levels showed very high value which made us suspect paradoxical response (IRIS). The differential diagnosis of an immune reconstitution inflammatory syndrome includes progression of the initial infection due to antimicrobial resistance or nonadherence to prescribed drug, development of a new infection, or drug toxicity which were ruled out in our case. CEMRI Brain was done in view of incoherence which was showed multiple tuberculomas. Patient was then started on Dexamethasone with favorable clinical response within 3-4 days with subsequent reduction in procalcitonin levels. Such high levels of procalcitonin (>905) responding drastically to corticosteroid confirmed our suspicion of IRIS. We were able to discharged the patient in stable condition after 40 days of hospital stay.

Conclusion

IRIS presenting as extreme PCT elevation is rare and interesting. Procalcitonin levels are routinely used in critical care for de-escalation of antibiotics and differentiating bacterial infection from other causes of sepsis. But through this case report, we emphasized upon the fact that high procalcitonin levels may be considered for diagnosis of IRIS after ruling out other possibilities for instance secondary infection and other inflammatory processes. A good clinical acumen and continues clinical corelation in the bed side of the patient is always required apart from protocol driven practice for best results.

References

- 1) Assicot M, Bohuon C, Gendrel D, Raymond J, Carsin H, Guilbaud J. High serum procalcitonin concentrations in patients with sepsis and infection. *The Lancet*. 1993 Feb 27;341(8844):515-8.
- 2) Mimoz O, Edouard AR, Samii K, Benoist JF, Assicot M, Bohuon C. Procalcitonin and C-reactive protein during the early posttraumatic systemic inflammatory response syndrome. *Intensive care medicine*. 1998 Feb;24(2):185-8.
- 3) Annborn M, Dankiewicz J, Erlinge D, Hertel S, Rundgren M, Smith JG, Struck J, Friberg H. Procalcitonin after cardiac arrest—an indicator of severity of illness, ischemia-reperfusion injury and outcome. *Resuscitation*. 2013 Jun 1;84(6):782-7.
- 4) Carsin H, Assicol M, Feger F, Roy O, Pennacino I, Bever H, Ainaud P, Bohuon C. Evolution and significance of circulating procalcitonin levels compared with IL-6, TNF α and endotoxin levels early after

thermal injury. *Burns*. 1997 May 1;23(3):218-24.

5) Becker KL, Snider R, Nylen ES. Procalcitonin assay in systemic inflammation, infection, and sepsis: clinical utility and limitations. *Critical care medicine*. 2008 Mar 1;36(3):941-52.

6) Mayer KH, Hirsch HH, Kaufmann G, Sendi P, Battegay M. Immune reconstitution in HIV-infected patients. *Clinical Infectious Diseases*. 2004 Apr 15;38(8):1159-66.

7) WISLEZ M, BERGOT E, ANTOINE M, PARROT A, CARETTE MF, MAYAUD C, CADRANEL J. Acute respiratory failure following HAART introduction in patients treated for *Pneumocystis carinii* pneumonia. *American journal of respiratory and critical care medicine*. 2001 Sep 1;164(5):847-51.

8) Murdoch DM, Venter WD, Feldman C, Van Rie A. Incidence and risk factors for the immune reconstitution inflammatory syndrome in HIV patients in South Africa: a prospective study. *Aids*. 2008 Mar 12;22(5):601-10.

9) Becker KL, Nylen ES, White JC, Muller B, Snider Jr RH. Procalcitonin and the calcitonin gene family of peptides in inflammation, infection, and sepsis: a journey from calcitonin back to its precursors. *The Journal of Clinical Endocrinology & Metabolism*. 2004 Apr 1;89(4):1512-25.

10) Maruna P, Nedelnikova K, Gurlich R. Physiology and genetics of procalcitonin. *Physiological Research*. 2000 Apr;49:S57-62.

11) Smith H. Paradoxical responses during the chemotherapy of tuberculosis. *The Journal of infection*. 1987 Jul 1;15(1):1-3

12) Shelburne SA, Montes M, Hamill RJ. Immune reconstitution inflammatory syndrome: more answers, more questions. *Journal of Antimicrobial Chemotherapy*. 2006 Feb 1;57(2):167-70.



