



How to treat deep bite and gummy smile in adult patient?!!

Prof. Maria Kuman, PhD

1. Holistic Research Institute, Knoxville, TN 37923, USA

Corresponding Author: Prof. Maria Kuman, PhD, Holistic Research Institute, Knoxville, TN 37923, USA

Copy Right: © 2022 Prof. Maria Kuman, PhD, This is an open access article distributed under the Creative Commons Attribution License, which permits unrestricted use, distribution, and reproduction in any medium, provided the original work is properly cited.

Received Date: January 24, 2022

Published Date: February 02, 2022

Introduction

21years old female patient well fit and both medically and dentally free presented to the clinic complaining from spacing and unaesthetic appearance on clinical examination

She was class IIdiv1 incisors on skeletal class IIbase and

increased Vertical proportional and no obvious asymmetry transverse ,she has increased incisal show during smiling with Increased over jet and overbite

Buccal segment class 1bilaterally and canine 1/2 unit 2 on right side and class 1on left side with upper midline shift 1mm to left hand side

No crowding were foundin upper and 2mm crowding in lower arch but spacing 5mm in upper arch



Initials	HA
Sex	Female
Age at start of treatment	21
Patient Complaint	Spacing and appearance
Medical History	Free
Other relevant information	Free

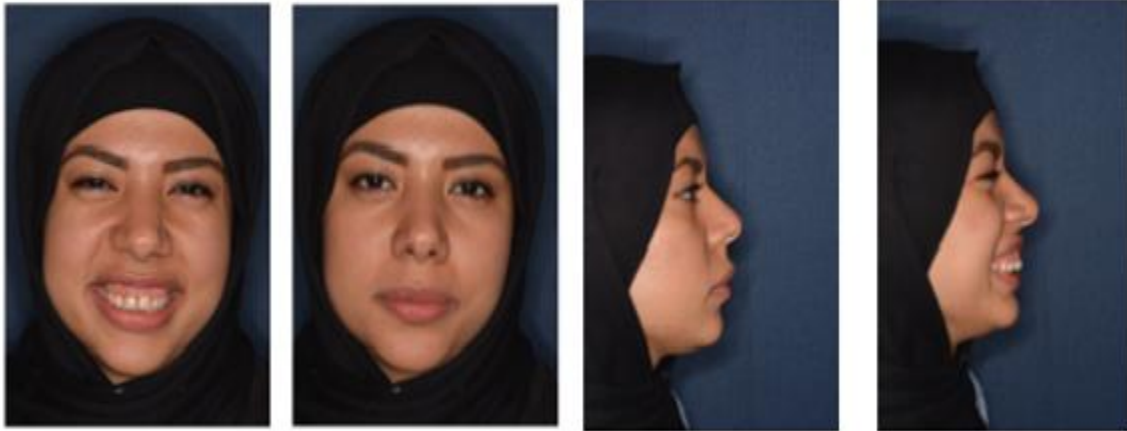Extra Oral Assessment:

Absent teeth	None
Teeth of poor prognosis	None
Other relevant radiographic findings	None

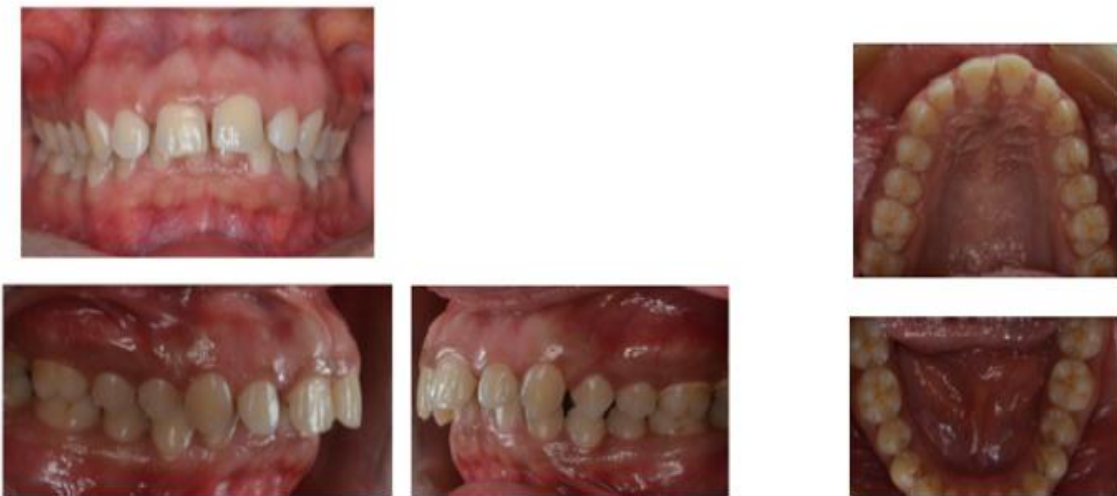Intra Oral Assessment

Skeletal Antero-Posterior	Class II
Skeletal Vertical	Increased LAFH
Skeletal Transverse	No obvious asymmetry
Soft Tissue Assessment	Normal upper and lower lip

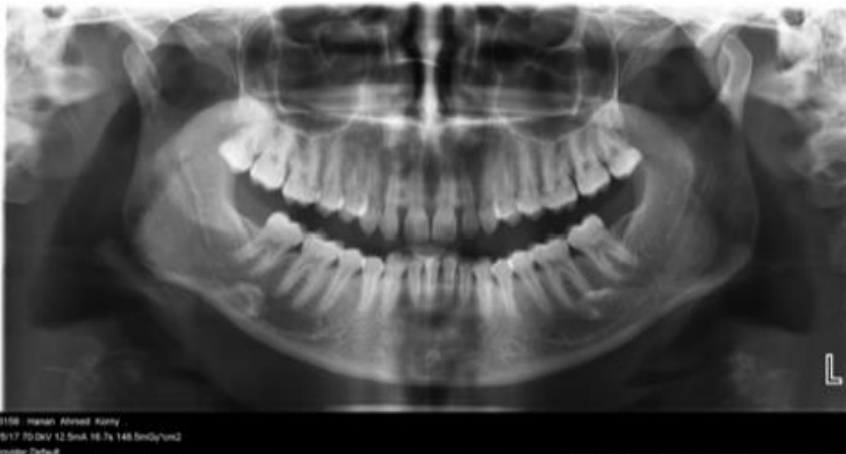
General Radiographic Examination



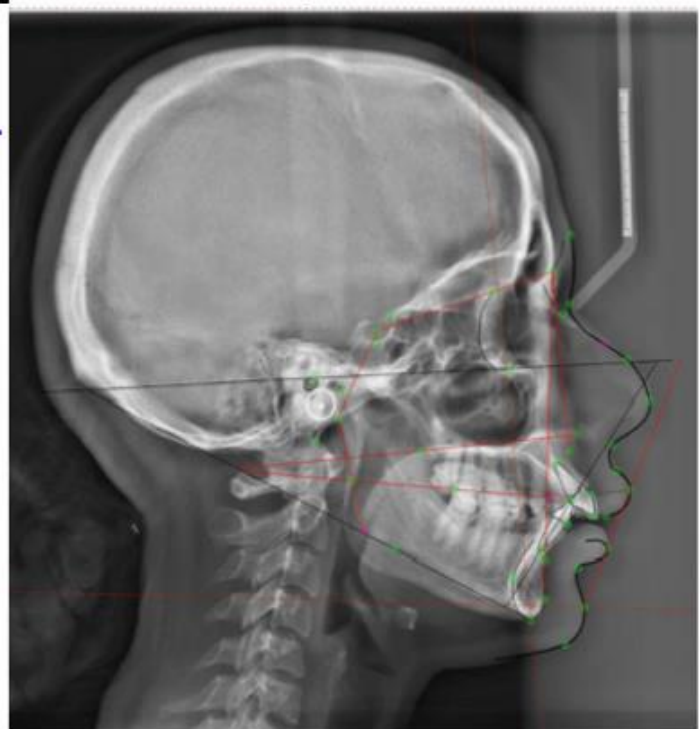
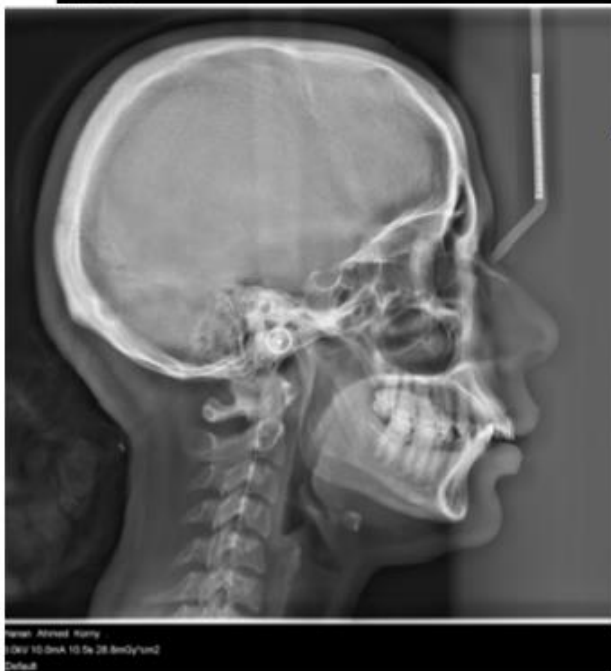Pre-Treatment Photographs: Extra Oral



Pre-Treatment Photographs: Extra Oral



**PRE-TREATMENT
RADIOGRAPHS**



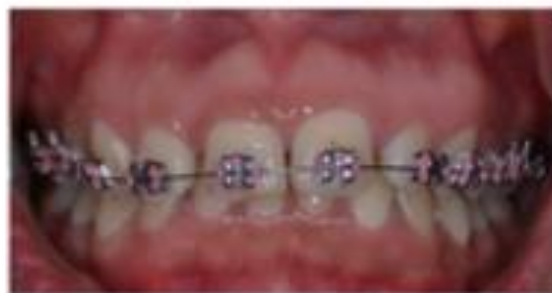PRE-TREATMENT CEPHALOMETRIC ANALYSIS

Variable	TO	Normal
SNA	84	82° ± 3
SNB	75	79° ± 3
ANB	9	3° ± 1
SN to maxillary plane	20.6	8° ± 3
Wits appraisal	7.7	0 ± 1.77mm
Upper incisor to maxillary plane	121	108° ± 5
Lower incisor to mandibular plan	95	92° ± 5
Interincisal angle	113	133° ± 10
MMPA	30	27° ± 5
Face height ratio	66.3%	55%±2%
Lower incisor to APo line	7.6mm	0-2 mm
Nasolabial angle	90	102°±8

Treatment Plan	
Summary	<p>HA is to receive orthodontic treatment using preedgewise fixed appliance with 0.22*0.28 slot Roth prescriptions</p> <p>Extractions :non extraction case Retention :upper and lower fixed retainer placed on lingual surface of upper and lower teeth extending fromUL3 to UR3 and LL3 and LR3 with vacuum formed retainer</p>
Extractions	<p>Upper: none Lower: none</p>
Bond-ups	<p>Upper: upper teeth from 6 to 6 Lower: lower teeth from 6 to 6 Timing of Upper and Lower arch bond-up: <i>Bonding of upper arch ahead of lower arch by 3 months due to increased overbite by 65%</i></p>
Retention	<p>upper and lower fixed retainer placed on lingual surface of upper and lower teeth extending fromUL3 to UR3 and LL3 and LR3 with vacuum formed retainer</p>

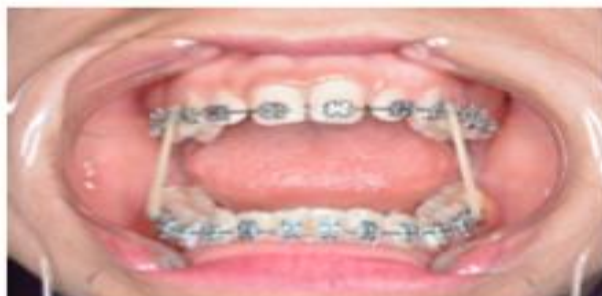Starting Photos:

We bond upper arch from UL6 to LL6 and we place the bracket in differential reposition places more incisal in aid to allow the anterior teeth to intrude and decrease the gummy smile patient complains from



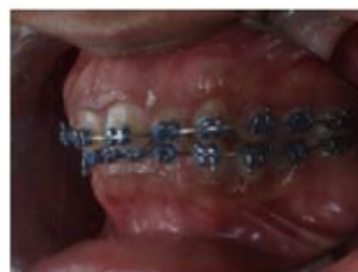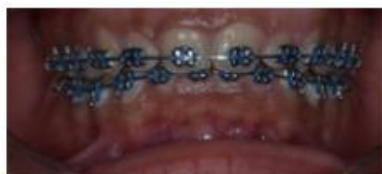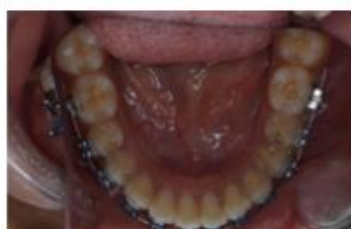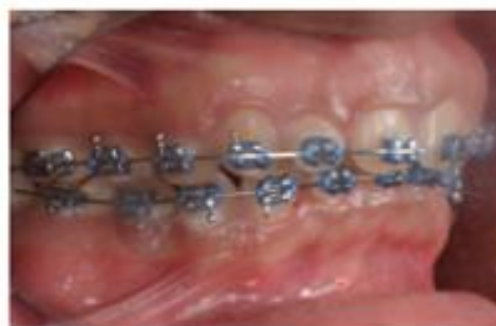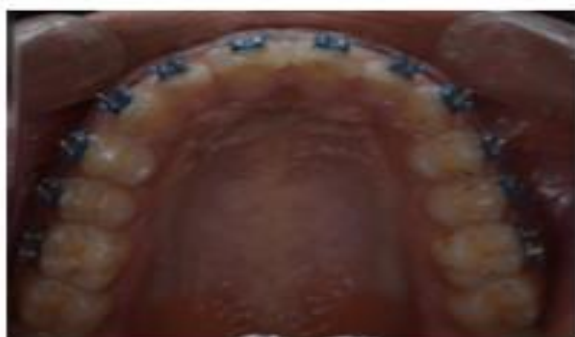After 3 Months

Bonding lower arch from LL6 to LR6 and using early elastic technique to decrease the overbite by extrusion of molar and procline lower incisors and retrocline upper incisors as well as helping in closing spaces in upper arch

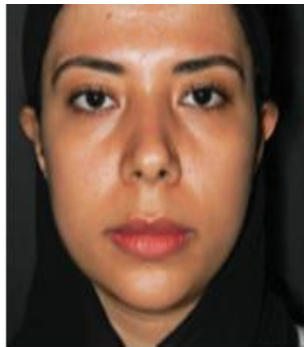
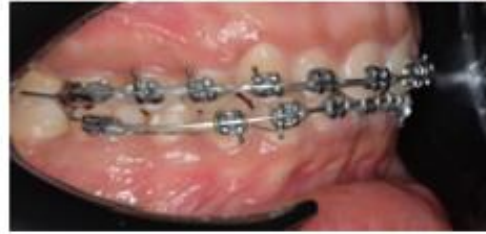
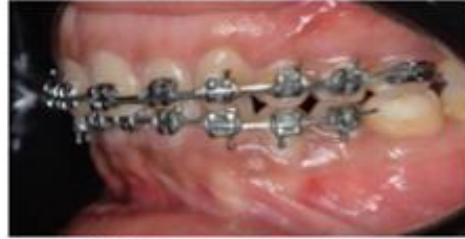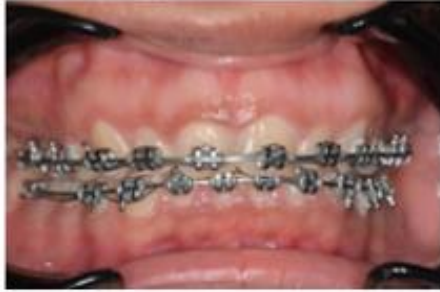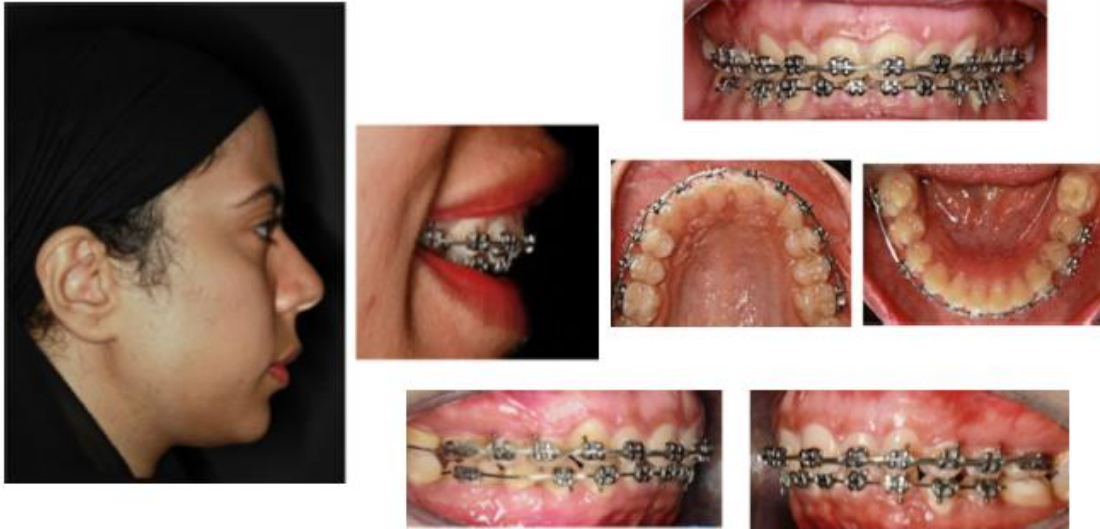MID Photo:

After reaching heavy arch wire 19*25 and ligation all the teeth and place Elastomeric chain in aid to close all the spaces in both arches, before debonding and Retention phase patient complain from gummy smile so we perform gingivectomy.

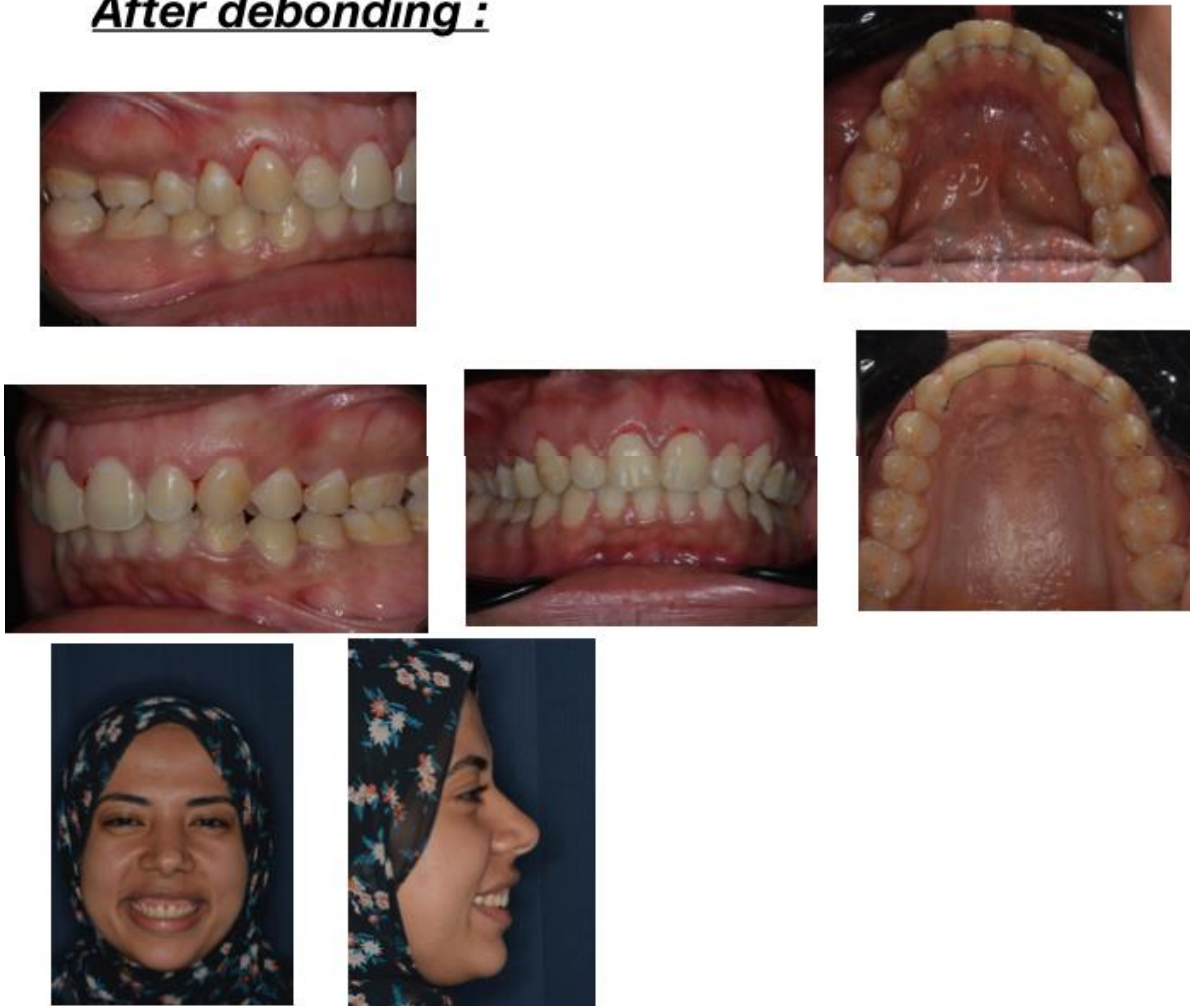

Gingivectomy Step





After debonding :



Post treatment radiographs:

Variable	TO	Normal
SNA	84	82° ± 3
SNB	75	79° ± 3
ANB	9	3° ± 1
SN to maxillary plane	20.6	8° ± 3
Wits appraisal	7.7	0 ± 1.77mm
Upper incisor to maxillary plane	106	108° ± 5
Lower incisor to mandibular plan	114	92° ± 5
Interincisal angle	114	133° ± 10
MMPA	27	27° ± 5
Face height ratio	59%	55%±2%
Lower incisor to APo line	5mm	0-2 mm
Nasolabial angle	90	102°±8

