



Full Arch Rehabilitation of Edentulous Space with One Piece Tissue Level Implants

Dr Jimoh Olubanwo Agbaje¹, Dr. Henri Diederich ^{2*}

1. OMFS-IMPACT Research Group, Department of Imaging and Pathology, Faculty of Medicine, Catholic University Leuven, Belgium
2. Dr. Henri Diederich, 114 av de la Faiencerie, L- 1511 Luxembourg.

Corresponding Author: Dr. Henri Diederich, doctor in dental medicine, 114 av de la Faiencerie, L- 1511 Luxembourg.

Copy Right: © 2022 Dr. Henri Diederich, This is an open access article distributed under the Creative Commons Attribution License, which permits unrestricted use, distribution, and reproduction in any medium, provided the original work is properly cited.

Received Date: August 26, 2022

Published Date: September 01, 2022

Introduction

The loss of teeth can affect people in numerous ways; it impairs aesthetics, mastication (chewing), and speech. In most cases impaired masticatory ability impacts food selection, often leading to poor dietary selections resulting to poor nutritional choices with its associated morbidities. In most patients the quality of life reduces^{1, 2}. Clinical treatment and respective prosthetic solutions help restore aesthetics, mastication, and speech which also improves patient quality of life³⁻⁵.

The cases below illustrate full arch rehabilitation of edentulous area. A number of patients presented in this study used full denture which was either loose or unsatisfactory, in others there is impaired masticatory ability due to their edentulousness. In all cases, prompt rehabilitation was sought within a short period without an elaborate and invasive procedure⁶⁻⁸. Patient missing functional abilities was restored, bringing relief and satisfaction to patients.

Keywords: rehabilitation, full arch implant prosthesis, one piece implants, pterygoid implants, one piece tissue level implants,

Case 1

A 53 years old lady had a loose full arch prosthesis which required prosthesis glue for the prosthesis to stay in the mouth making the patient unhappy. She visited a number of dental clinics, the proposed treatment options offered by the various clinics: Sinus lift, bone grafting or zygomatic implants for the upper edentulous arch. The proposed clinical option was both invasive and require numerous visits to the clinic, this was not acceptable to the patient.

Our clinic was able to offer the patient a minimal invasive treatment option. A clinical examination showed an edentulous upper arch with resorbed ridge. The radiographic examination using an orthopantomogram showed few teeth in the lower jaw with severe vertical resorption in the right premolar and molar region. In the upper jaw, there is a moderate vertical bone resorption (Fig1.)

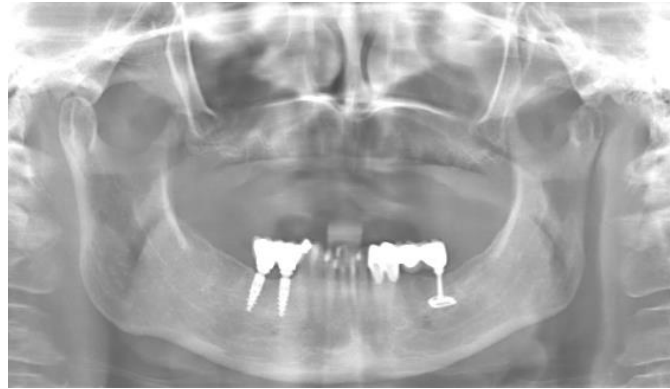

Figure 1 shows the panoramic radiograph of the patient at presentation.

Cortically Fixed protocol can be applied in the cortical areas in the maxilla, which are pterygoid plate, paranasal and biocortical anchorage under the nose. Doing this needs special implants adapted to the bone conditions, long and thin.

It is important to plan and consider which implants match the patient's situation. In this case the Pterygoid implants (ROOTT implants) (TRATE) designed under the guidance of the author (Dr Henri Diederich) are both efficient and its placement is minimally invasive. The design of these implants allow also to be used in soft bone in order to maximize the anchorage

In most cases the application of these designed pterygoids implant requires just a single pilot drill hole, the self-tapping implant will then tap its own hole. The thin point of the implant engages the cortical bone and the larger threads compress the spongy bone and results of the corticalization of the spongy bone. A high torque is usually achieved. A minimum torque of 50N/cm allows for immediate loading of the implant. The Pterygoid implant (ROOTT P) is available in lengths of, 16mm,18mm, 20mm, 22mm, 24mm and 26mm. For the pterygoid region 20mm is the best length to get the strongest anchorage.

Lengths of 22,24 may be used in obliquity in order to reach the paranasal region.

In this case the cortical areas anterior and posterior to the sinus were engaged by the implant without perforating the sinus thus avoiding sinus complications. Then the remaining bone under the nose was used with suitable compressive threads implants (ROOTT M/MS) providing bicortical anchorage.

At time of surgery a flap was raised beginning from distal region on the left side to the anterior region. The pilot drill hole was made and the Pterygoid implant (P4520 - D4.5mm L20mm) was inserted by

hand via the implant carrier (provided avoid hand contact with thread) and then torqued with the wrench until a torque of 65 N/cm was achieved.

Next a P3522 (D3.5mm L22mm) Pterygoid implant was inserted at position 24 in an oblique way in order to fix it to the cortical bone of the nose. Then at position 23, and 22 MS3016 implants (D3.0 L16 mm) were inserted due to a very narrow crest present. Flaps were closed after the implants insertion and the same procedure was repeated on the right side. Fig 2.

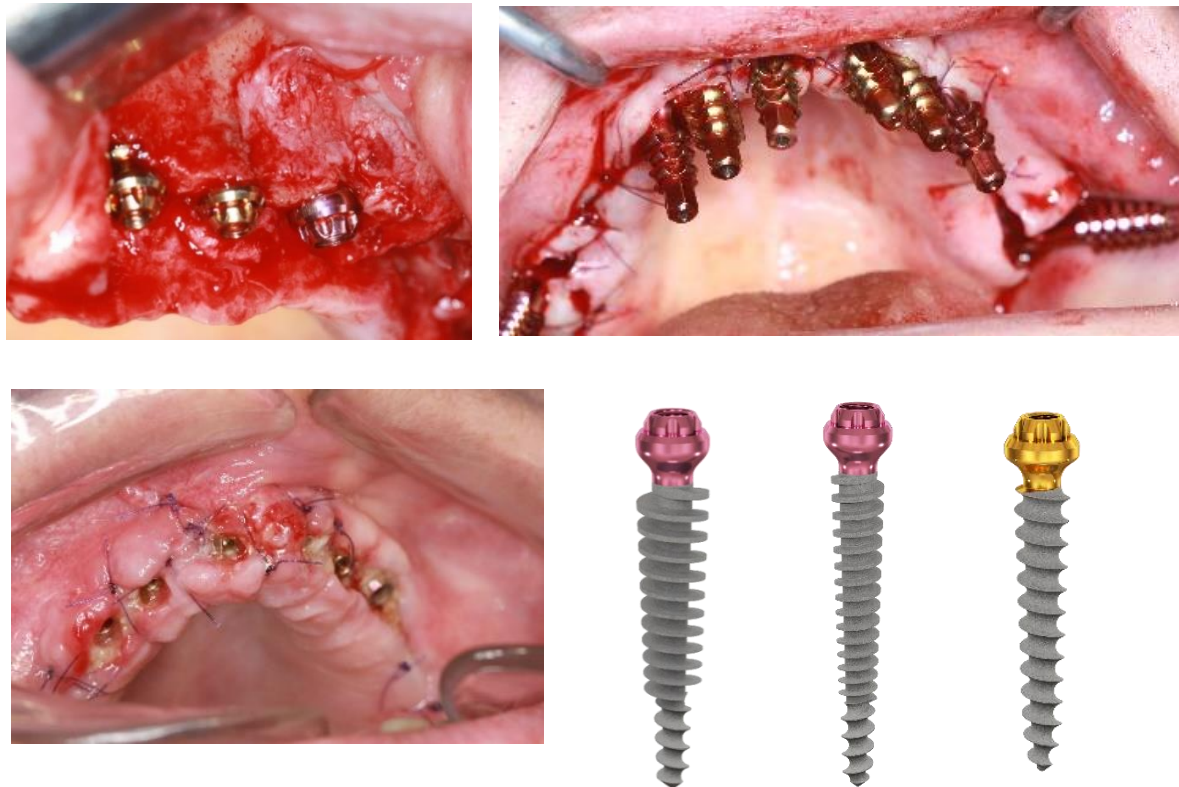


Figure 2: Surgical procedure and implant placement in the maxilla

Flaps were stitched and impression was taken immediately after surgery, open tray, screwed transfers were used, fig 3. At the next appointment the try-in key confirmed, and an aesthetical probe was done. The key is in duralay resin reinforced with metal, which contains all the transfers. The bite check was also carried out.

At the next step, 3rd appointment the metal frame was tried in and validated.

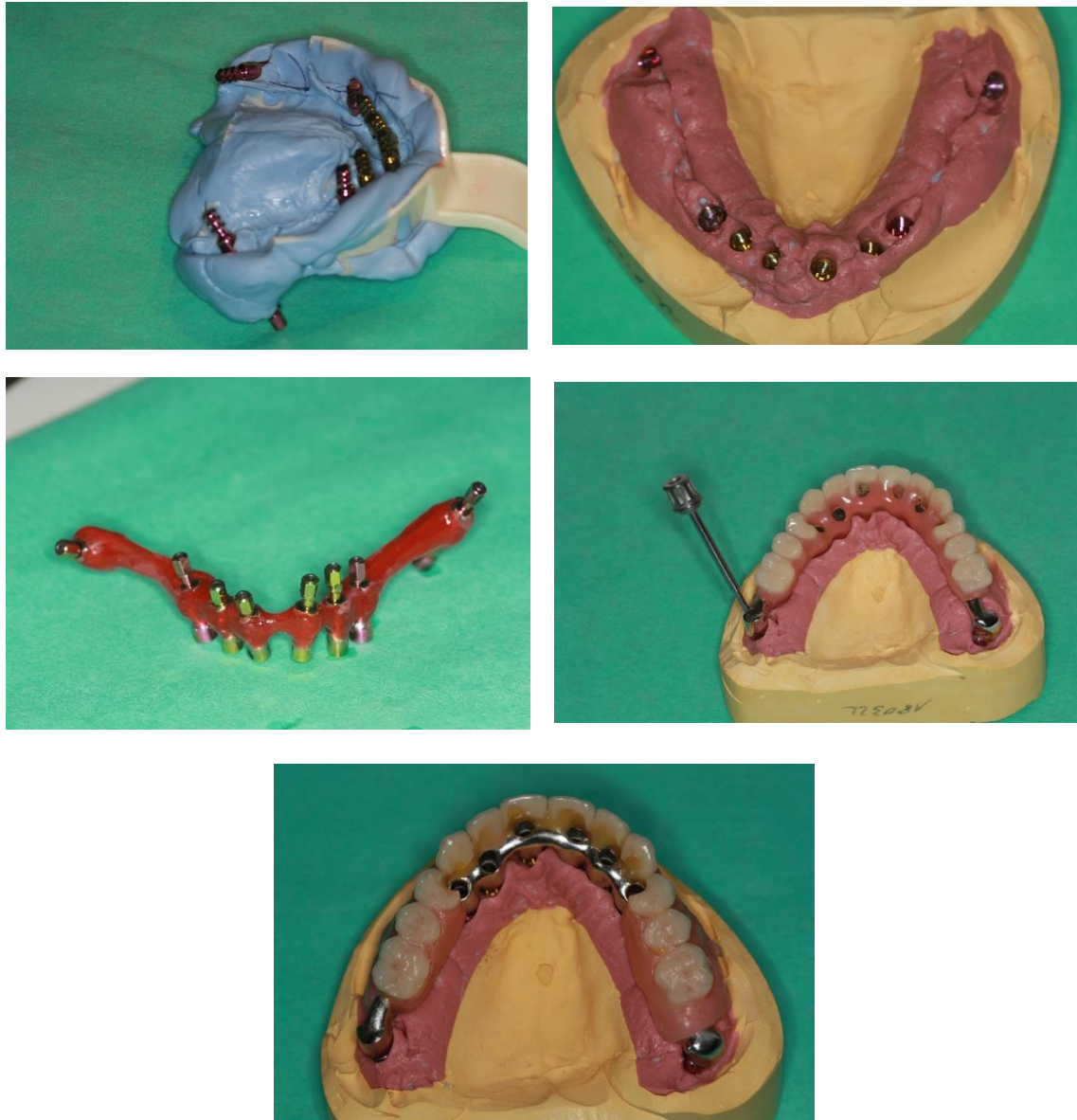

Figure 3: Laboratory steps- Bite registration, impression taken procedure, duralay key and bridge fabrication

A temporary prosthesis was fabricated based on her previous prosthesis. This temporary chair side bridge was cemented on the abutments.

The teeth color was chosen and on the next appointment bridge was placed. The whole treatment procedure took 2 weeks without any complication's fig 4.

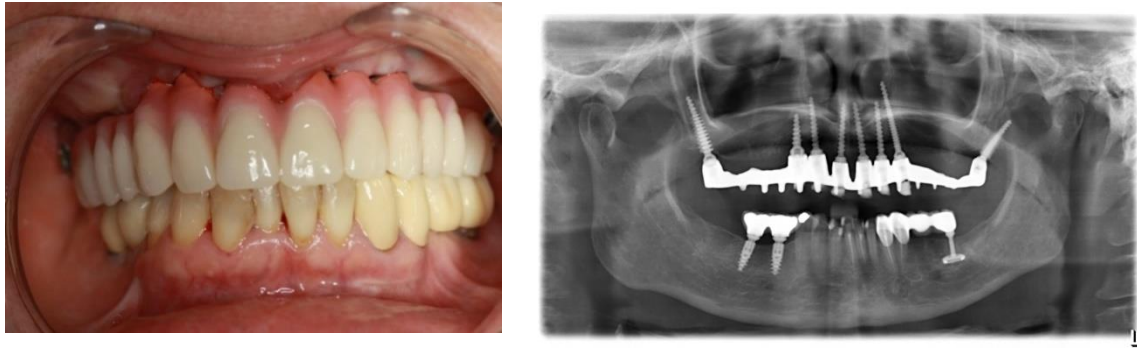


Figure 4: Clinical photograph and the panoramic radiograph of patient and after bridge delivery

Case 2

Patient is a man of 58-year-old who is very unhappy with his full prosthesis because of lack of retention.

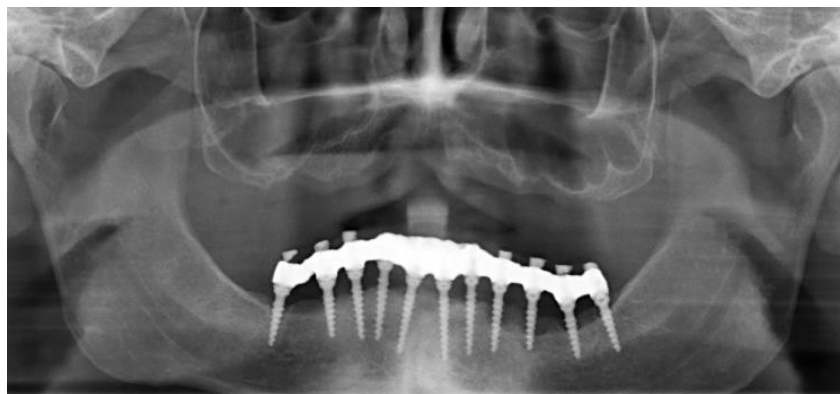

Figure 5 shows the panoramic radiograph of the patient at presentation.

The proposed treatment options at another clinic were to carry out bone grafting this is likely to take a number of months and a number of visits to the clinic. The patient was unhappy with the proposed treatment options, upon attending our clinic he was offered minimally invasive options.

Surgery was carried out under local anesthetic, the same procedure was done as in the previous case, with the only difference that implant can only be inserted till position 13-23. At these positions two P3522 (D3.5mm L22mm) implants were inserted. The thread configuration of the implant is the same as that of implant used at the Pterygoid plate, with a thin part at the apical side which allows a soft slow introduction to the cortical bone of the nose. Fig 6

Pterygoid Implants P4520 (D4.5mm L20mm) were inserted at position 18 and 28. In the front where the ridge is very narrow a MS3016 (D3.0mm L16mm) long implant was used, the head of the implant is small which is better adaptable in a narrow crest

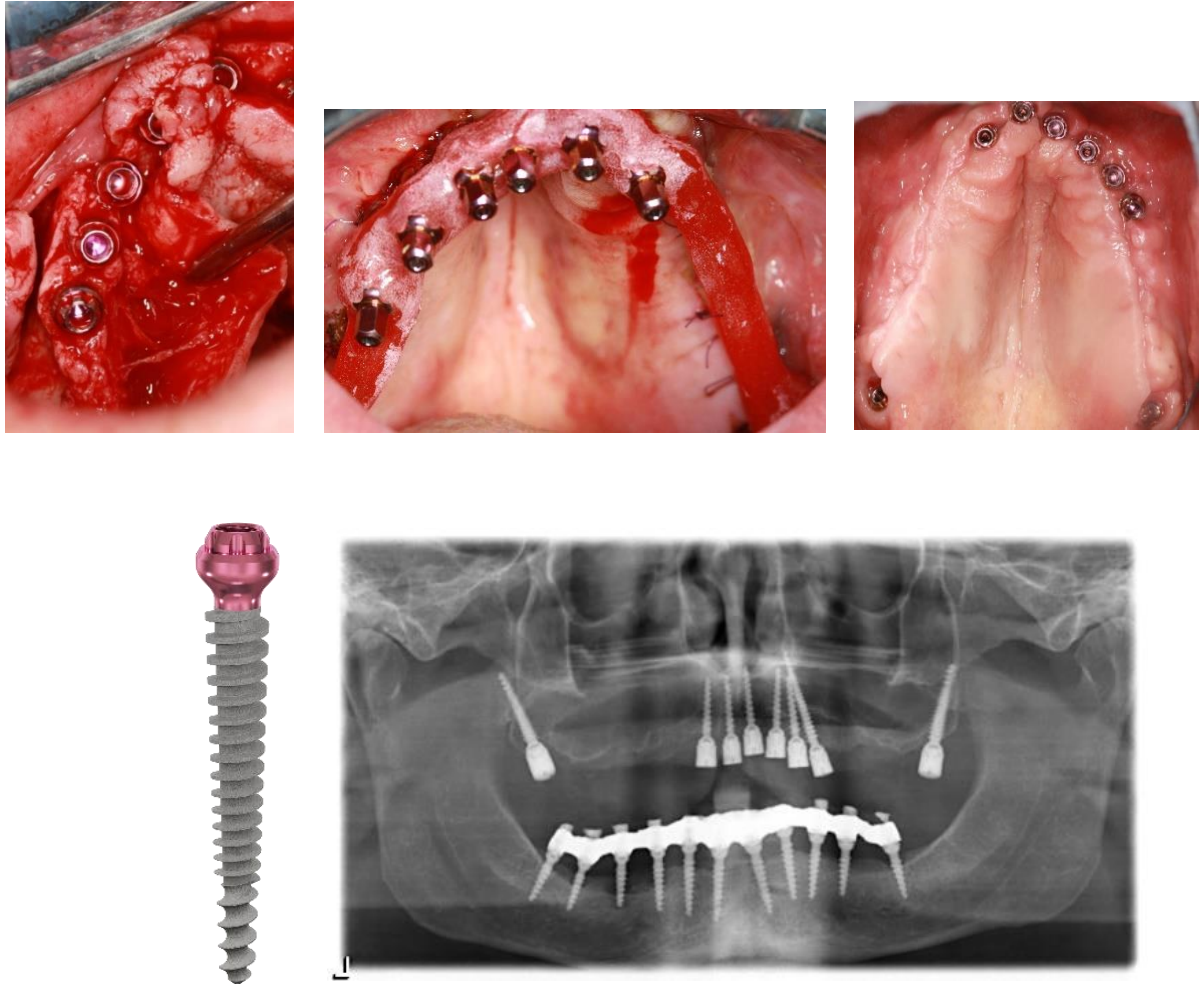


Figure 6: Surgical procedure and implant placement in the maxilla

After the surgery the impression was taken immediately with screwed transfers and a temporary bridge was constructed at chairside. Fig 7

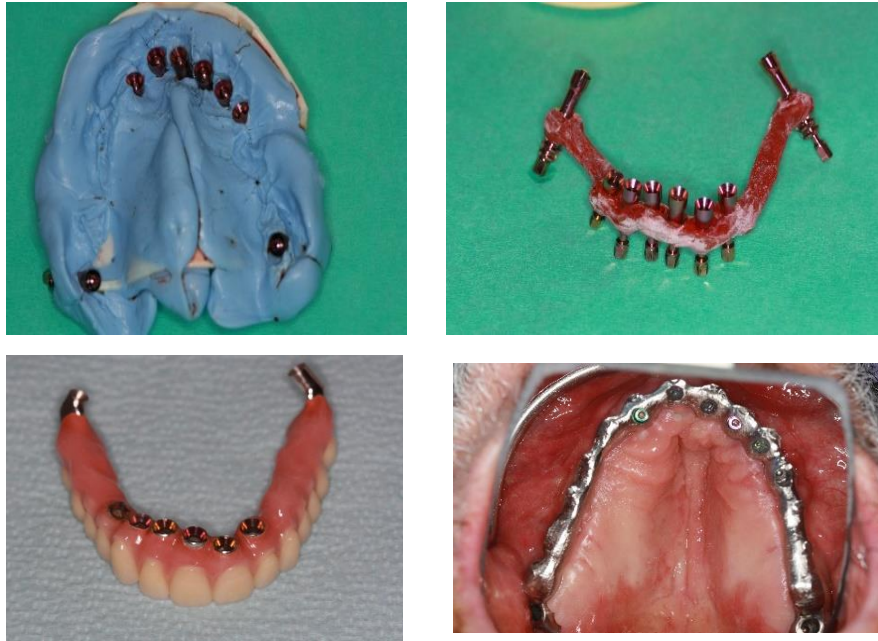

Figure 7: Laboratory steps- Bite, impression taken procedure, duralay- key and bridge fabrication

A

t the second appointment the verification key was tried and occlusion was checked.

At the 3rd appointment the metal frame was tried-in, esthetics was checked at the 4th appointment in this case and then after 3 weeks the case was completed. Figure 8 and 9 show the panoramic radiographic of patient after implant placement and the photos of prosthesis and patient at completion of treatment.

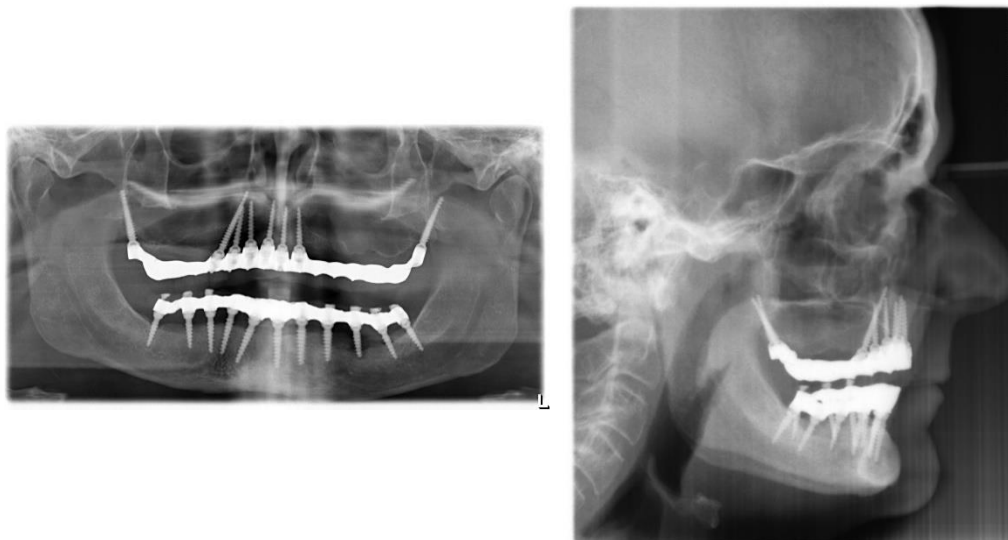


Figure 8: Panoramic radiograph of patient after implant placement

This case was done under local anesthesia with early loading.

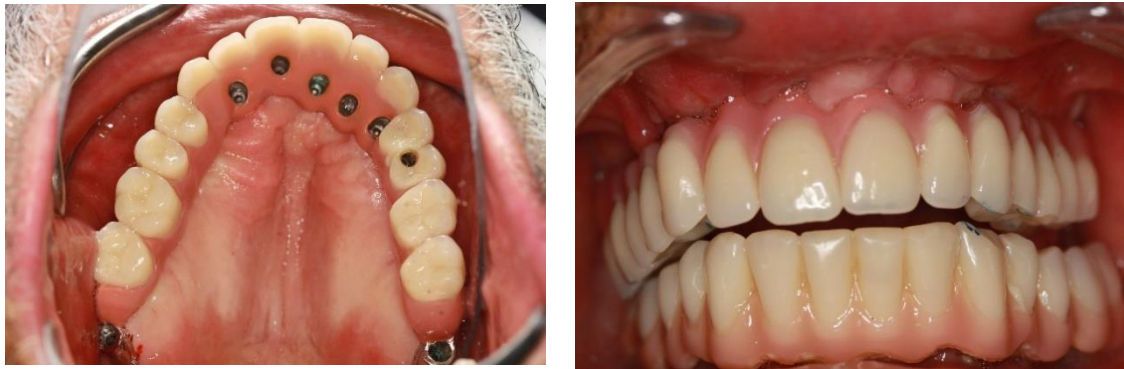

Figure 9: Images of prosthesis and patient at completion of treatment

Case 3

The patient, a lady of 58 wanted fixed prosthesis in the maxilla. The lady has been suffering for several years, she has a loose prosthesis making eating very difficult. The lady had been using prosthesis glue to for retention. The patient has highly pneumatized sinuses which must not be injured Fig 10.

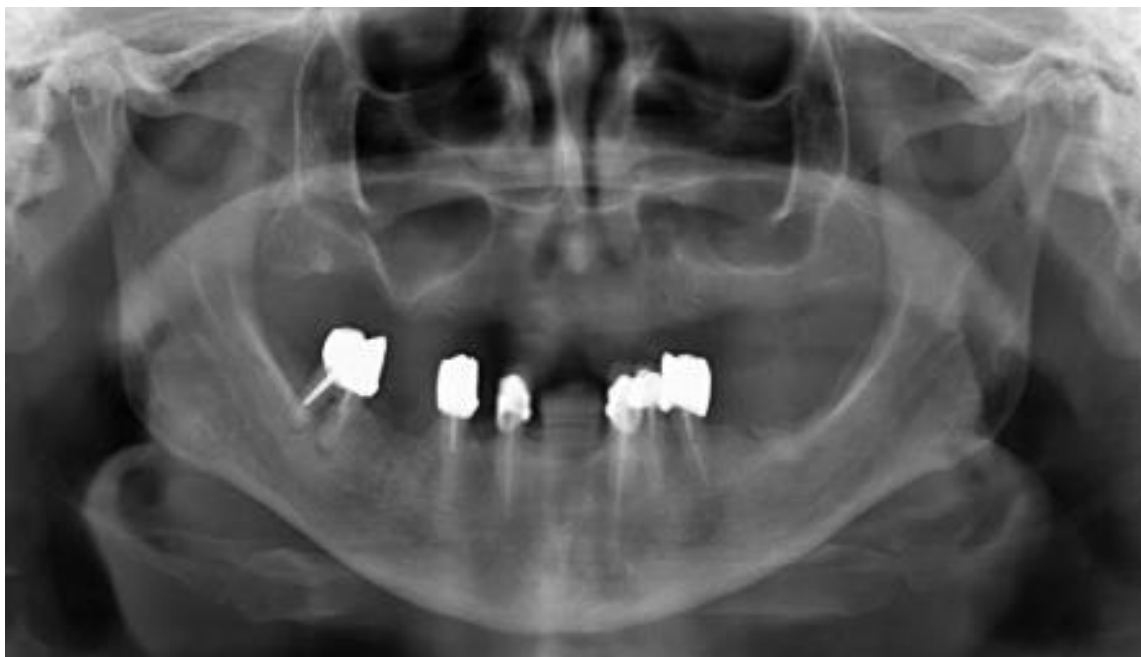

Figure 10: Panoramic radiograph of patient at presentation

The case was managed in a minimal invasive way by using One Piece Tissue level implants.

In the pterygoid region a ROOTT P4520 (D4.5mm L20 mm) implant was inserted on both sides. An implant of length 20mm length for the Pterygoid region is appropriate, thickness is dependent on the bone available which may vary between 3.5mm and 4.5mm. In most cases a 3.5mm diameter is used as per fig 11.

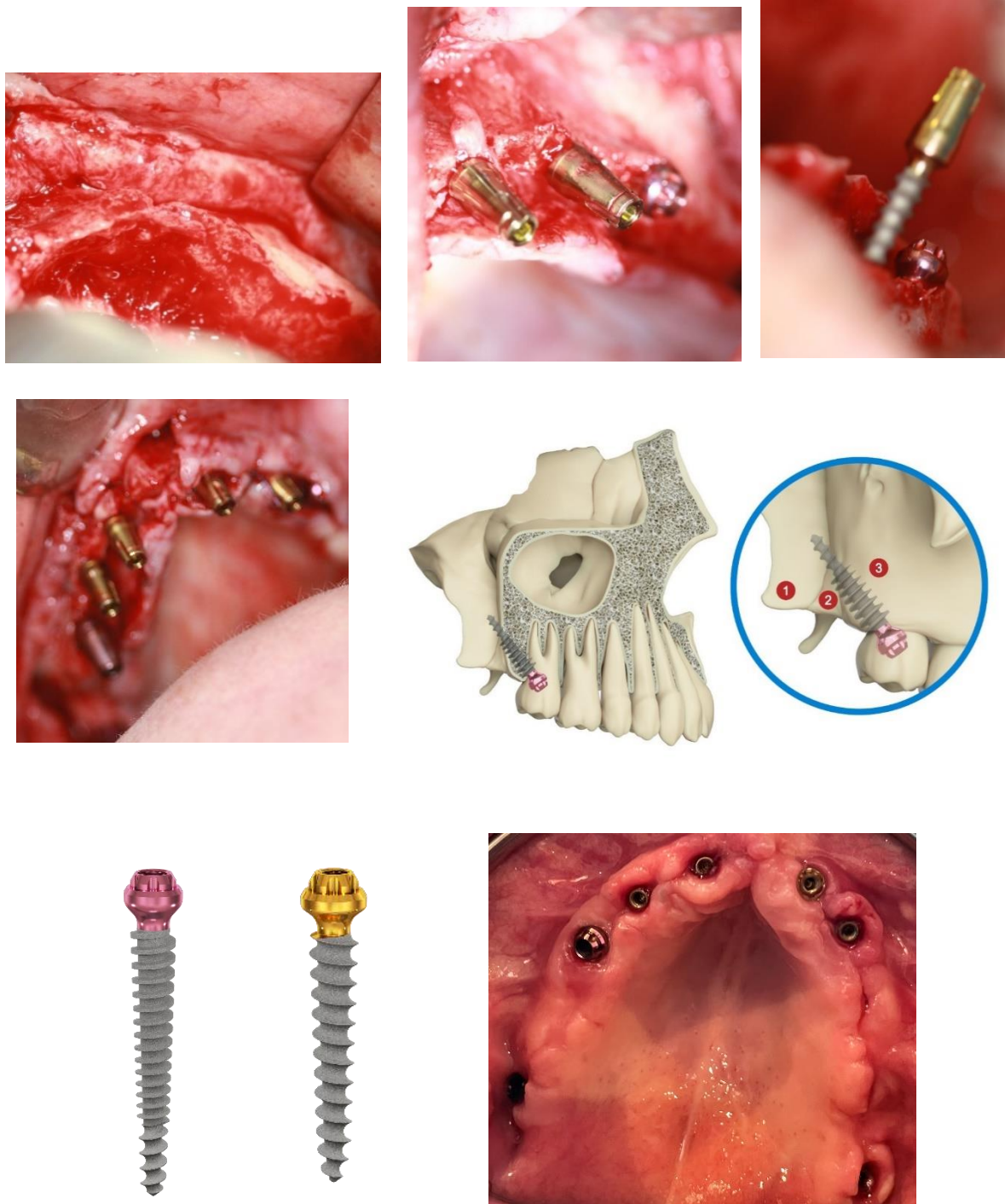


Figure 11: Surgical procedure and implant placement in the maxilla

A torque of 65 N/cm was achieved providing a high degree of stability. Surgery was started at the left side and continued to the right side. In the front under the nose a M3014 (D 3.0mm L14mm) implant was used for bicortical anchorage and in position 14 a long P3522 (D3.5mm L24mm) implant was used in order to reach the cortical bone of the nose.

The primary stability of all implants was high so immediate loading was carried out. Immediately after surgery the impression was taken, and a temporary bridge was fabricated at chairside. Also, the occlusion was checked at this moment. At the second appointment duralay-key was checked, transfers were hold in duralay.

At the third appointment the metal frame was tried in which was ok. At the following appointment the esthetics and occlusion were checked fig 12.

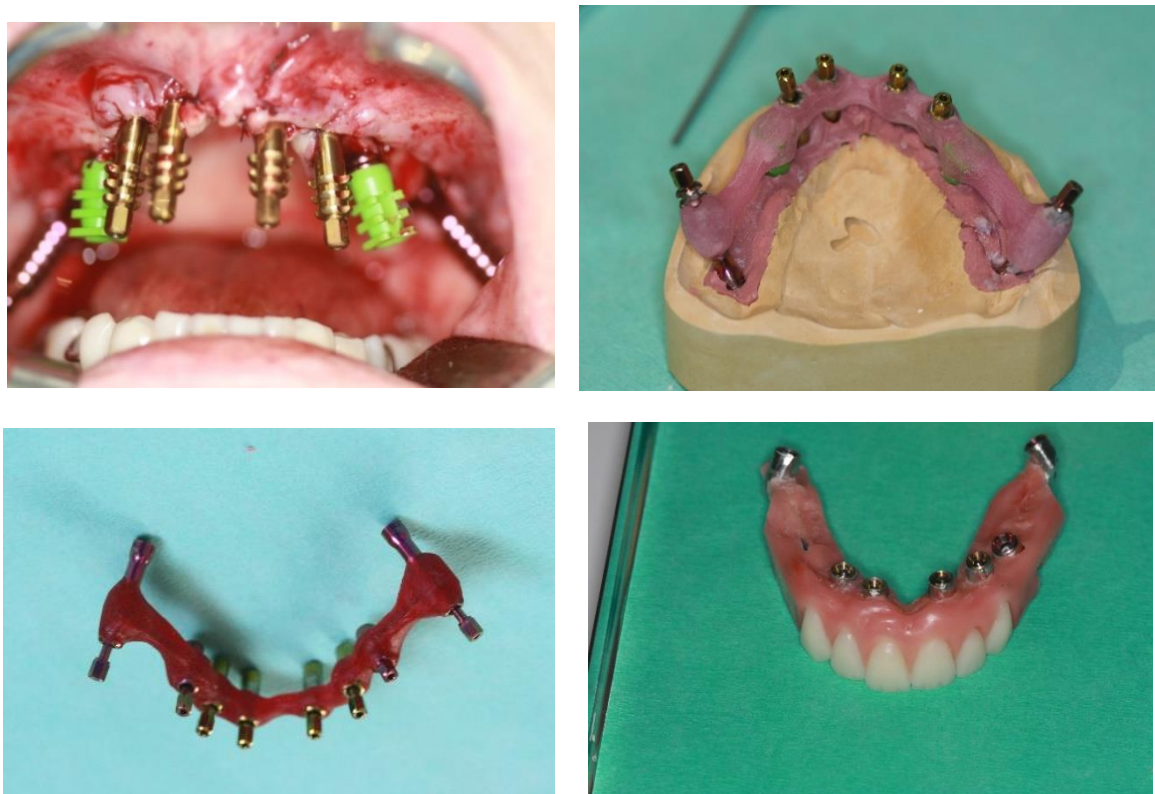


Figure 12: Laboratory steps- Bite registration, impression taken procedure, plater key and bridge fabrication

At the 4th appointment, 2 weeks after the patient got his metal resin bridge. The bridge is screw retained fig 13 and 14 show radiograph and patient photos at completion of treatment.

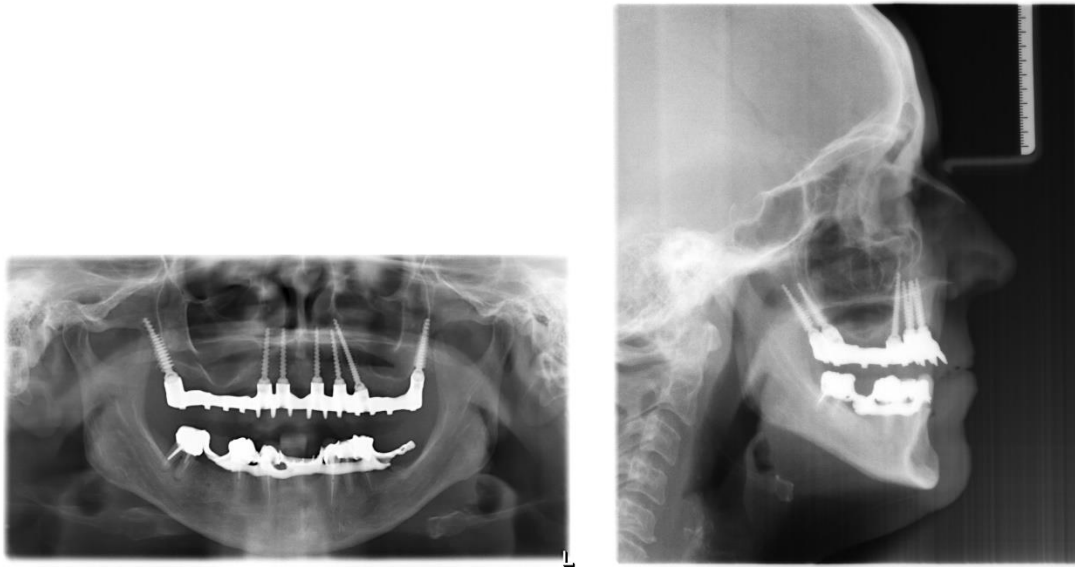


Figure 13: Panoramic radiograph of patient after implant placement

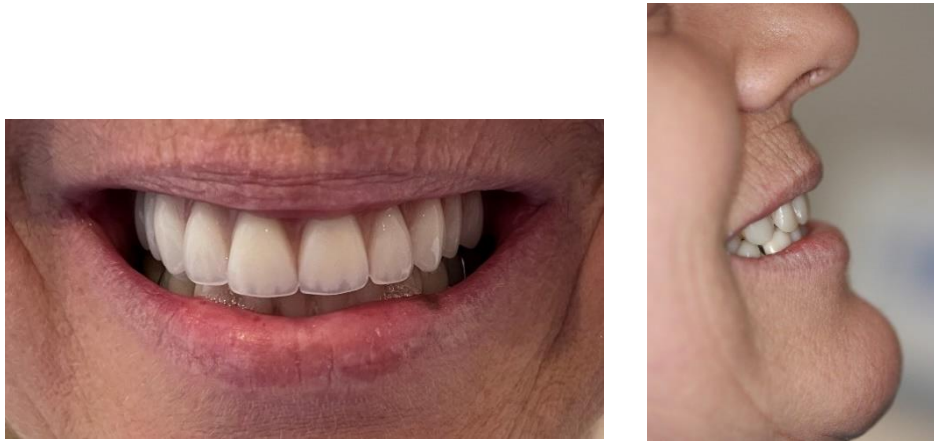

Figure14: Clinical photograph and the panoramique radiographie of patient

Case 4

The patient is a 50 year old man, he was very unhappy as he could not chew and wanted to have teeth in his mouth again fig15 show panoramic radiographie of patient at presentation.

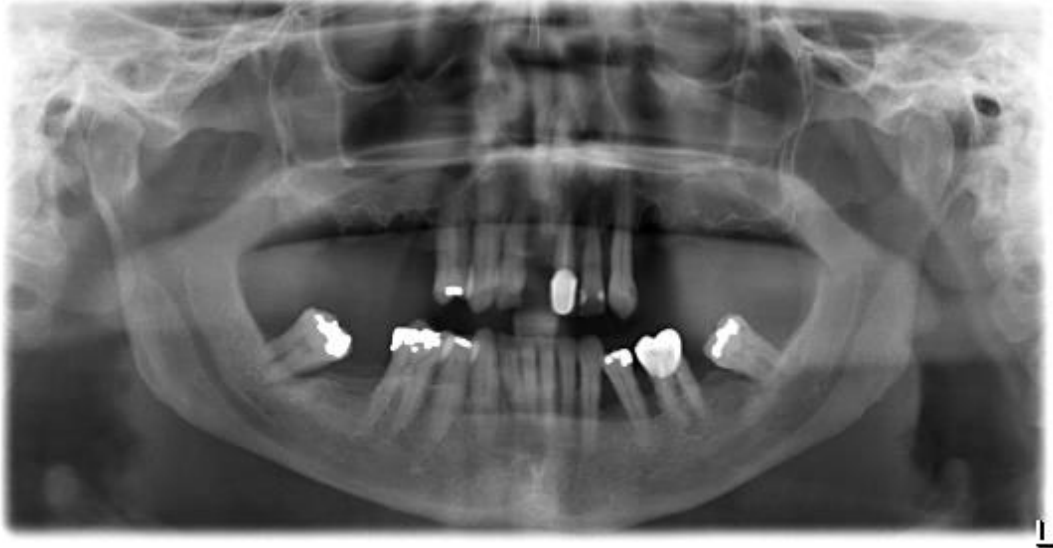

Figure 15: Panoramic radiographie of patient at presentation .

At the first appointment the remaining teeth were extracted, and all nine implants were placed.

A ROOTT P3520 (D3.5mm L20mm) implanted was inserted at the left side Pterygoid region and at position 24 a one-piece implant C3516 (D3.5mm L16mm) was inserted. The head of the one-piece implant was bent in order that the head is on the crest., this can be done when the bone is strong enough to support this procedure. The other One-Piece compressive implants were inserted in the extraction sockets. At position 14 the head of the implant was also bent as per Fig 16.

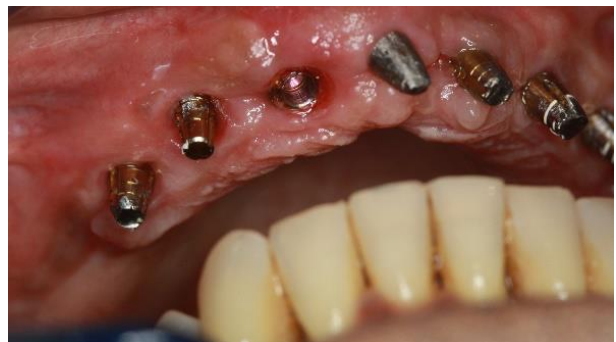
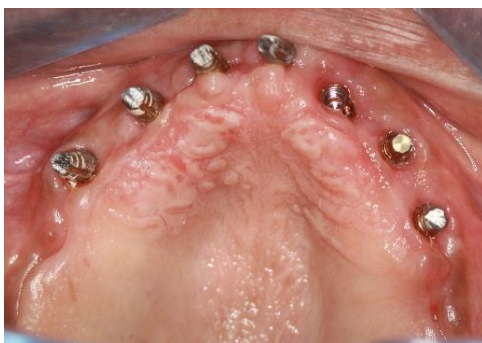


Figure 16: Surgical procedure and implant placement in the maxilla

In this case the bridge was both cemented and screw retained. The procedure here was the same as in other cases except that the metal ceramic bridge was both cemented and screw retained

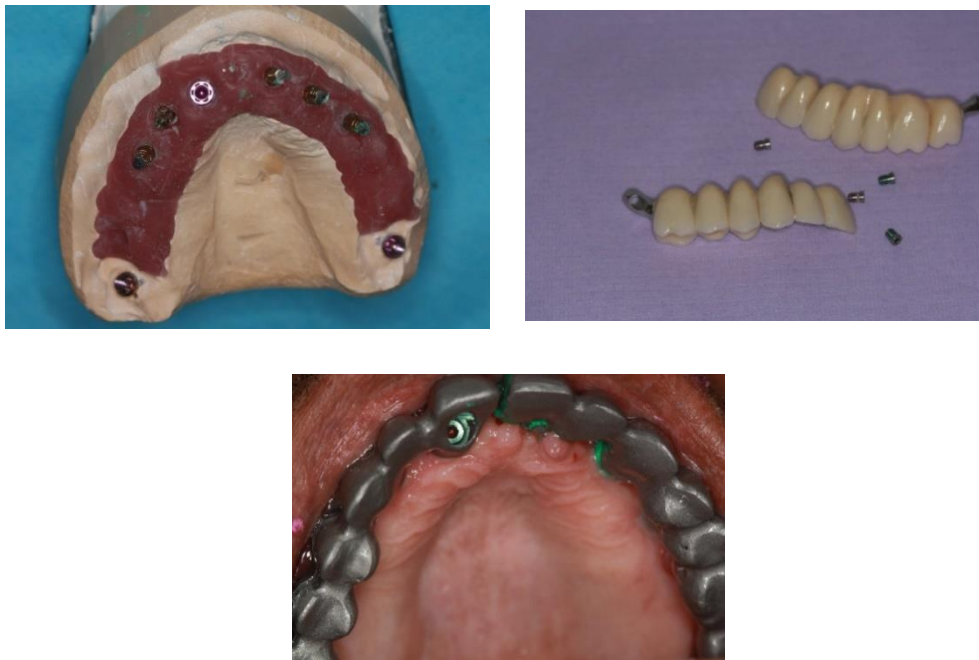


Figure 17 : Laboratory steps- Bite registration, and bridge fabrication

This was possible as the rest bone volume allowed us to do so. In the other cases the residual bone did not allow to support a too much heavy superstructure. Fig. 18 and 19 show the radiographs and clinical photograph of patient after bridge delivery. This case was also completed after just 3 weeks.

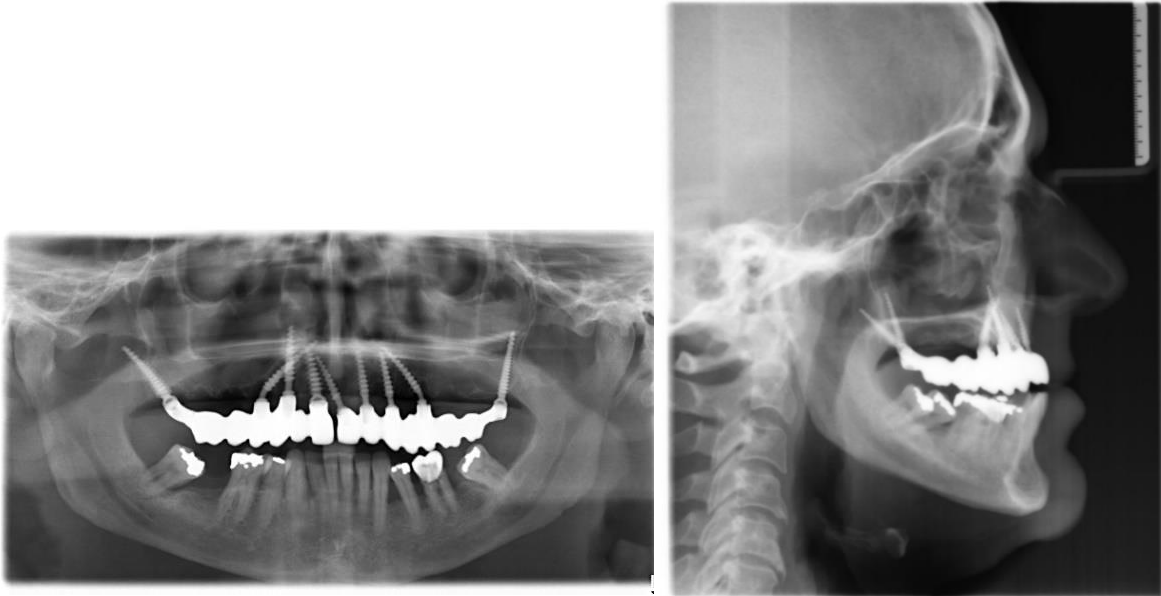


Figure 18: Panoramic radiograph of patient at completion of treatment

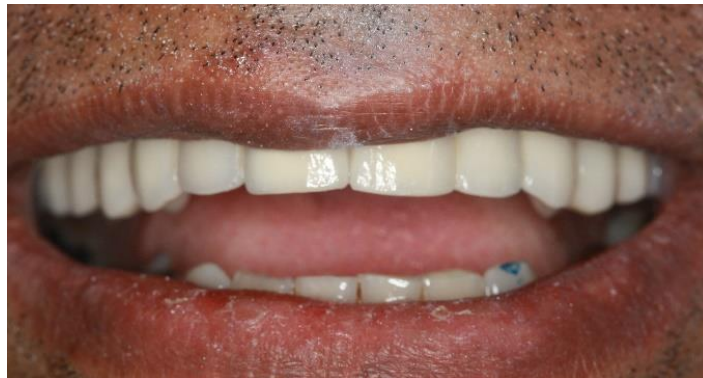

Figure19: Clinical photograph and the panoramic radiograph of patient

Discussion

The presented case reports describe how the pterygoid and the one-piece implants, tissue level, were used for the functional restoration of an edentulous patient with atrophied jaw avoiding surgical procedures such as sinus lift and bone grafts.

With the pterygoid and the one piece implants the patient problem of edentulism in the upper and lower jaws could be solved without additional surgical procedures⁶⁻¹¹.

The rehabilitation of difficult cases is achieved within a short period of time, early loading, and the patient need was met without additional surgical operation.

Reference

1. Ali SA, Karthigeyan S, Deivanai M, Kumar A. Implant rehabilitation for atrophic maxilla: a review. *J Indian Prosthodont Soc* 2014; 14:196-207
2. Figueredo OMC., Câmara-Souza MB, Carletti TM, and odrigues Garcia RCM. Chewing ability and oral health-related quality of life in frail elders after new complete dentures insertion: A paired controlled clinical trial. *Special care in dentistry. American Association of Hospital Dentists, the Academy of Dentistry for the Handicapped, and the American Society for Geriatric Dentistry* 40(2), 168-174. 2020.
3. Chan MF, Narhi TO, de BC, Kalk W. Treatment of the atrophic edentulous maxilla with implant-supported overdentures: a review of the literature. *Int J Prosthodont* 1998; 11:7-15
4. Mericske-Stern RD, Taylor TD, Belser U. Management of the edentulous patient. *Clin Oral Implants Res* 2000; 11 Suppl 1:108-25.:108-125
5. Toljanic JA, Baer RA, Ekstrand K, Thor A. Implant rehabilitation of the atrophic edentulous maxilla including immediate fixed provisional restoration without the use of bone grafting: a review of 1-year outcome data from a long-term perspective clinical trial. *Int J Oral Maxillofac Implants* 2009; 24:518-526
6. Agbaje JO, Diederich H. Minimal Invasive Modality for Full Rehabilitation of Edentulous Mandible with One-Piece Implants in Elderly Patients; A Case Report. *Adv Dent & Oral Health* 2018; 8:001-006
7. Agbaje JO, Diederich H. Minimal Invasive Concept for the Rehabilitation of Edentulous Jaw with One-piece Implants. *International Journal of Case Reports & Short Reviews* 2018; 4:028-030
8. Agbaje JO, Diederich H. Cortically Fixed at Once Implants for the Treatment of the Atrophic Maxilla - A Case Report. *Adv Dent & Oral Health* 2019; 1:001-005
9. Agbaje JO, Meeus J, Vrieling L, Diederich H. Rehabilitation of Atrophic Maxilla using Pterygoid Implants: Case Reports. *Modern Approaches in Dentistry and Oral Health Care* 2018; 1:1-6
10. Agbaje JO, Diederich H. Use of cortically fixed at once implants for the treatment of atrophic and extreme atrophic jaws. *Africa journal of Dentistry and Implantology* 2018; 43-50

11. Candel E, Penarrocha D, Penarrocha M. Rehabilitation of the atrophic posterior maxilla with pterygoid implants: a review. J Oral Implantol 2012; 38 Spec No:461-6. doi: 10.1563/AAID-JOI-D-10-00200. Epub@2011 May 13.:461-466