



Assessment of Sagittal Skeletal Base Relationship of Maxilla and Mandible with anterior cranial base by Horizontal Appraisal Method

Dr. Vakul Dunga *¹, Dr. Amanish Singh Shinh², Dr. Amanpreet Singh Natt³, Dr. Karan Maheshwari⁴,
Dr. Sharnjeet Kaur⁵, Dr. Alisha Babbar⁶.

***Correspondence to:** Dr. Vakul Dunga,

Copyright

© 2023 **Dr. Vakul Dunga**. This is an open access article distributed under the Creative Commons Attribution License, which permits unrestricted use, distribution, and reproduction in any medium, provided the original work is properly cited.

Received: 24 June 2023

Published: 01 July 2023

Abstract

Introduction: *The evaluation of antero-posterior skeletal jaw relationship is crucial before diagnosis and treatment planning. Lateral cephalometry is commonly used to analyse craniofacial morphology, soft tissue profile and the direction of facial growth. Aim and Objectives: The present study is aimed to assess the anteroposterior jaw dysplasia and to assess the correlation between various measurements used in antero-posterior discrepancy.*

Materials and Method: *A total of 30 lateral cephalograms were selected and were subdivided into skeletal Classes I, II, III groups based upon the ANB angle derived from the pre-treatment cephalograms.*

Results: *The results showed that for saddle angle (123 degree) majority of Class I patients have prognathic maxilla (due to position of maxilla) with increased mandibular length & Class II patients showed normal position of mandible but decreased mandibular length, with normal maxilla which leads to skeletal Class II pattern. In class III cases normal and decreased saddle angle (1230 and <123) showed anterior positioning of mandible with increased mandibular length and reduced maxillary length with normal maxillary position (N-ANS).*

Conclusion: *The antero-posterior jaw relationship can finally be effectively and consistently assessed by the clinician using the horizontal evaluation approach in addition to the existing cephalometric tools.*

Key Words: *Antero-posterior discrepancy, horizontal appraisal, cephalometric analysis*

Introduction

Broadbent introduced cephalometrics in 1931. Cephalometrics is regarded as a crucial tool for evaluating jaw relationship in all spatial planes, i.e. anterior-posterior, vertical, and transverse. The anteroposterior plane has been one of the mainstays in the diagnosis, prognosis, treatment planning as well evaluation in mid-treatment/post-treatment and retention. The relationship of the maxilla and the mandible in the sagittal plane is the most crucial criteria employed in orthodontic diagnosis as early as the 1900s, even before Angle created his classification of malocclusion.[1]

ANB-angle, Wits appraisal, YEN-angle, Beta-angle, W-angle, Schwarz and McNamara analysis are some geometric characteristics that have been defined and utilised successfully to aid the physician in the diagnosis of sagittal jaw discrepancies. Particular and unique reference lines, planes and points are employed for each of these attributes.[2,3]

Numerous research has been conducted to evaluate and compare different anteroposterior jaw dysplasia markers in various skeletal patterns and populations. However, for a multitude of times while evaluating skeletal dysplasia, these cephalometric parameters showed conflicting results and a specific diagnosis is hard to reach.

Thus, this study aimed to create new anterior-posterior jaw dysplasia indicators using linear dimensions.

Materials and Methods

The study's sample size was 30 patients who had shown up for orthodontic treatment and were at least 18 years or above. Based on the ANB angle obtained from the pre-treatment cephalogram, the patients were divided into skeletal Classes I, II, and III groups of ten each

Inclusion criteria

1. ANB angle between 1° and 3° for Class I; $>3^{\circ}$ for Class II and $\leq 1^{\circ}$ for Class III;
2. Permanent dentition with no missing teeth;
3. Patients with age group above 18 years.

Exclusion criteria

1. No previous history of orthodontic treatment;
2. No cranial or facial malformation and no history of craniofacial trauma;
3. Poor quality of cephalograms.

Methodology

The pre-treatment cephalograms were obtained and traced on acetate tracing sheet using variable X-ray illuminator. For study purpose, 6 landmarks were marked directly on each film with a soft sharp pencil. After tracing, the samples were divided into groups of 10 each in skeletal Classes I, II, and III using ANB angle. The true horizontal (HOR) was drawn 7o on the film from the S-N line. And vertical lines (TVL) were drawn 90° to the true horizontal plane at various land marks. Next the sagittal relationship was measured and compared for each group by following the parameters given below.

Definition of landmarks

- Sella (S): The midpoint of the hypophysial fossa.
- Nasion (N): The most anterior point of the frontonasal suture in median plane.

- Point A: The deepest midline point in the curved bony outline from the base to the alveolar process of the maxilla
- Point B: The most posterior point in the outer contour of the mandibular alveolar process, in the median plane.
- Gonion (Go): A point on the curvature of the angle of the mandible located by bisecting the angle formed by line tangent to the posterior ramus and the inferior border of the mandible
- Menton (Me): The lowest point on the symphyseal shadow of the mandible
- Posterior nasal spine (PNS): The intersection of a continuation of the anterior wall of the pterygopalatine fossa and the floor of the nose, marking the distal limit of the maxilla.
- Anterior nasal spine (ANS): It is the anterior tip of the sharp bony process of maxilla in the midline of the lower margin of anterior nasal opening.
- HOR: True horizontal (HOR) is the line drawn 7o on the film from the S-N line

Angular and linear measurements.

		CEPHALOMETRIC LANDMARKS.
Angular	ANB	Angle between points A, N, and point B
	Saddle angle	Nasion Sella Articulare angle
Linear	Se-PNS	Sella entrance to posterior nasal spine
	ANS-PNS	Anterior nasal spine – Posterior nasal spine
	Se-N	Sella entrance to nasion.
	Se-A	Sella entrance to point A.
	Se-B	Sella entrance to point B.
	Go-Me	Gonion – Menton.

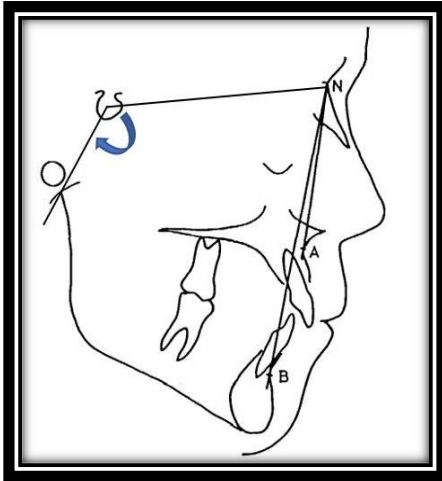


Figure 1: SNA Angle and Saddle Angle

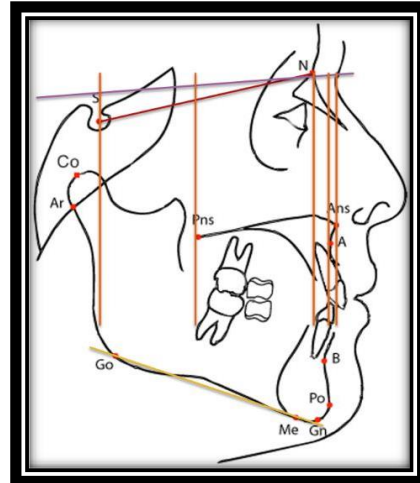


Figure 2: linear measurements

Results

The mean values for all the linear and angular measurements angles in the three skeletal groups are listed in Table 1,2 and 3.

PATIENT	1	2	3	4	5	6	7	8	9	10
ANB	1	1	1.5	2	2	2	3	3	3	3
SNA	83	85	78	83	84	85	81	83	84	85
Saddle	122	123	123	124	122	117	123	120	133	132
N per-A per	-2	-3	5	0	-1	-2	2	0	-1	-1
N-ANS	6	8	1	5.5	3.5	-6	0	-7	-7	-4.5
Se-N	58	56	59	62.5	55	58	56	57	58	56
ANS-PNS	49.5	49	48.5	48	45	48	44	51	52	48.5
Se-PNS	14.5	15	11.5	20	13.5	16	12	13	13	12
Go-Me	59	64	61	67	61	65	54	58	62	64

Table 1: linear and angular measurements for skeletal class I pattern

ANB range is (1-30) i.e., anterior limit of maxilla (point A) and mandible (point B) are Antero posteriorly normal. patient with normal saddle angle (1220-1240), majority of patients were having prognathic maxilla (N-ANS) with increased mandibular length (Go-Me) that leads to class 1 skeletal pattern. Patients with reduced saddle angle (below 1220), majority patients having prognathic mandible (N-Se- Ar) with increased maxillary length (ANS-PNS) and position to compensate for mandibular to maintain class 1 skeletal relation. Patient having increased saddle angle (>1240), mandible is retrognathic with near normal or slightly increased mandibular length and normal maxillary length with posterior positioned maxilla.

PATIENT	1	2	3	4	5	6	7	8	9	10
ANB	4	4	4	5	6	6	7	7	7	8
SNA	80	81	83	82	82	83	72	82	83	84
N per-A per	4	0.5	11.5	1	-0.5	1	3	2	-6.5	1
N-ANS	-1.5	-1.5	8.5	-5	4.5	5	0	3	7	-4
Saddle	124	131	130	120	123	125	131	127	118	130
Se-N	60	57.5	61.5	55	55.5	62	59	61	61	54
ANS-PNS	47	48	42	49	45.5	52	48.5	53.5	53	48.5
Se-PNS	14.5	11	11	11	14.5	15	10.5	10.5	15	9.5
Go-Me	57	60	60	56.5	55	59	59	65	59	54

Table 2: linear and angular measurements for skeletal class II pattern

Similarly, ANB range (>40) i.e., anterior limit of maxilla (point A) and mandible (point B) are Antero posteriorly too far placed from each other. In patient with normal saddle angle (1230) there was normal positioning of mandible with decreased mandibular length (Go-Me), and normal maxilla which leads the patient into class II. In Patient with increased saddle angle (>1230) and ANB=40,had posterior position of mandible with reduced mandibular length with normal maxilla (position)leading to class II. Patient with increased Saddle Angle (>1230) and ANB >40 having posterior position of mandible with reduced length and prognathic maxilla(N-ANS) lead to class II. Patient with decreased saddle angle (<1230) and increased ANB >40 having anteriorly positioned mandible with decreased mandibular length with prognathic maxilla(N-ANS) comparative to cranial base which led to class II skeletal pattern.

PATIENT	1	2	3	4	5	6	7	8	9	10
ANB	0	0	-1	-2	-3	-4	-5	-5	-5	-9
SNA	86	82	75	83	75	79.5	75	77	76	79
Saddle	120	129	126	122	122	115	125	123	124	129
N per -Aper	-1	16	10	14	13	11.5	7	5	8	15
N-ANS	8	3	0	3.5	-2	4.5	1	0	0	2
Se-N	58	59	58	63.5	64	56.5	68	58	61	53
ANS-PNS	47.5	51	47	51.5	46.5	46	51	44.5	47	42.5
Se-PNS	18.5	11	11	15.5	15.5	15	18	12	17	8.5
Se-ANS	66	62	58	67	62	61	69	56.5	64	51
Go-Me	62	65	56	68	68	56	78	69	60.5	61

Table 3: linear and angular measurements for skeletal class III pattern

ANB range(<10) i.e. anterior limit of maxilla (point A) and mandible (point B) are again too far placed from each other. In patients with normal and decreased saddle angle (1230 and <123) showed anterior positioning of mandible with increased mandibular length (Go-Me) and reduced maxillary length (ANS- PNS) with normal maxillary position (N-ANS). Patients with increased saddle angle (1230 – 1260) showed posterior positioning of mandible with increased mandibular length and normal length of maxilla with compensated maxillary position (posterior). Patients with 1290 of saddle angle showed posterior positioning of mandible with increased mandibular length and normal maxillary length and position.

Discussion

In orthodontic diagnosis and treatment planning, evaluation of the antero-posterior jaw relationship is an indispensable step. Both angular and linear cephalometric variables have been proposed to analyse sagittal jaw relationship and jaw position.

This study attempted using customised cephalometric parameters for each patient to indicate the sagittal jaw relationship in Classes I, II, and III malocclusions in assessment of sagittal jaw discrepancies to have a better understanding of the disharmonies. ANB and saddle angle were the two angular variables and Se-N, Se-ANS, Se-PNS, ANS-PNS, N-ANS and Go-me were the six new linear

parameter which were compared in this study. [4,5] The most popular parameter for assessing the sagittal jaw relationship remains the ANB angle which was used in dividing the samples into Classes I, II, and III malocclusions.

All the parameters were found to be equally significant in assessing the antero-posterior discrepancy (ANB Angle) and were in correlation with the previous studies. The most popular parameter for assessing the sagittal jaw relationship remains the ANB angle, but it is affected by various factors and can often be misleading. Nanda and Taylor[6,7] have shown that position of nasion is not fixed during growth, and any displacement of nasion directly affects ANB angle. Furthermore, rotation of the jaws by either growth or orthodontic treatment can also change the ANB. A popular recent alternative, Beta angle avoided use of functional plane and is not affected by jaw rotations. But it uses points A and B, which can be remodeled by orthodontic treatment and growth. Furthermore, as shown by various studies, the reproducibility of the location of condylion on closed-mouth lateral head films is limited. Instead of condylion, center of condyle could be used, but approximation of center of condyle is difficult. This could give a nonsignificant error of approximately 1°. [9]

Yen angle [8] was introduced to overcome few of these deficits. This does not utilize A and B points as skeletal landmarks, which are affected by local remodeling due to orthodontic treatment or occlusal plane as in Wits. Instead, it utilizes points M and G which are not affected by local remodeling, and they approximate to being centroid points similar to Sella. As it is not influenced by growth changes, it can be used in mixed dentition as well. But rotation of jaws can mask true sagittal dysplasia here too. To overcome these existing problems, the Horizontal Appraisal Method was developed. This method used extracranial reference line, that is, HOR(True horizontal line) plane through NHP. The other commonly used reference plane for assessing AP discrepancy are the SN plane, Frankfort horizontal plane, and occlusal plane, all of which have been shown to have limitations. [10,11] Cooke and Wei reported variance of intracranial reference planes to the true vertical in NHP ranging between 25° and 36°. In contrast, the variance of extracranial reference plane in NHP was 4°. The variability of the HOR as a cephalometric reference plane in NHP therefore represents at least a six-fold improvement in reliability in relation to the variability of previously used intracranial reference planes, and therefore, AP analysis based on NHP and the HOR also should be more clinically relevant.[12]

The results in the present study revealed that all the seven parameters considered in the study were accurate in determining the antero-posterior jaw discrepancy with horizontal appraisal method.

The saddle angle is the angle between the anterior and posterior cranial base. Within the region of posterior cranial base lies a sagittal growth centre, the sphenooccipital synchondrosis. A large saddle angle indicates a posterior position, a small saddle angle an anterior position of the glenoid fossa. The results of the present study showed that for normal saddle angle (1230) or normal (1220-1240), majority of patients are having prognathic maxilla (due to position of maxilla) with increased mandibular length that leads to class I skeletal pattern. Patients having reduced saddle angle (below 1220), majority patients having prognathic mandible (position) with increased maxillary length and position to compensate for mandibular position to maintain class 1 skeletal relation. Patient having increased saddle angle (>1240), mandible is retrognathic (post glenoid fossa). Which may be attributed to a catch-up phenomenon to achieve maxillomandibular Harmonie.

For skeletal Class II growth pattern, at normal saddle angle (1230), two out of ten patients were having normal saddle angle with normal position of mandible but decreased mandibular length, with normal maxilla which leads the patient into class II. Patient having increased saddle angle (>1230), have posterior position of mandible with reduced mandibular length with normal maxilla (position) leading to class II (ANB=40). Patient having increased SA (>1230) having posterior position of mandible with reduced length and prognathic maxilla lead to class 2 malocclusion (ANB>40). Patient having decreased saddle angle (<1230) having anterior positioning of mandible with decreased mandibular length with prognathic maxilla comparative to cranial base lead to class II skeletal pattern (ANB >40)

For skeletal Class III growth pattern. In patients with normal and decreased saddle angle (1230 and <123) showed anterior positioning of mandible with increased mandibular length (Go-Me) and reduced maxillary length (ANS-PNS) with normal maxillary position (N-ANS). Patients with increased saddle angle (1230 – 1260) showed posterior positioning of mandible with increased mandibular length and normal length of maxilla with compensated maxillary position (posterior). Patients with 1290 of saddle angle showed posterior positioning of mandible with increased mandibular length and normal maxillary length and position. Individuals with class II and III showed both maxillomandibular deficiency caused by reduced size or retroposition or due to a maxillary excess or a combination of both. It may be because of no catch-up growth or any etiological and

environmental defect to achieve maxillomandibular Harmony. The above results indicated that the newer horizontal appraisal method might be considered highly in the assessment of antero-posterior jaw relationship along with current cephalometric tools.

Although this study proved that all the parameters were efficient in determining antero-posterior skeletal discrepancy with a limitation. Even though the sample size in the study was small but it showed consistent results. In the light of fast paced evolution, sagittal skeletal discrepancy should be investigated further with large sample size.

Conclusion

The limitations of previously used measurements for measuring the anteroposterior jaw discrepancy are well known. The true anteroposterior skeletal disparity can be evaluated using the horizontal evaluation approach in routine clinical practice since it can aid in identifying true skeletal discrepancy, independent of conditions that would typically mask them.

References

1. Angle EH. Classification of malocclusion. *Dent. Cosmos*. 1899;41:350-7.
2. Riedel RA. Esthetics and its relation to orthodontic therapy. *The Angle Orthodontist*. 1950 Jul;20(3):168-78.
3. Jaiswal A, Gupta M, Kanungo H, Mishra K. Comparative analysis and co-relation of antero-posterior jaw dysplasia indicators in angle's Class I molar relation and normal overjet subjects of Central India—A pilot study.
4. Relwani P, Gowda NC, Ramegowda S. Comparative assessment of changes in sagittal relationship of maxilla to mandible in class II malocclusion—A cephalometric study. *Indian J Orthodontics Dentofacial Res*. 2016 Apr;2:77-82.

5. Aparna P, Kumar D, Prasad M, Shamnur N, Kumar A, Sridhar KR, BR GK, Gupta N. Comparative assessment of sagittal skeletal discrepancy: a cephalometric study. *Journal of clinical and diagnostic research: JCDR*. 2015 Apr;9(4):ZC38.
6. Hussels W, Nanda RS. Analysis of factors affecting angle ANB. *American journal of orthodontics*. 1984 May 1;85(5):411-23.
7. Taylor CM. Changes in the relationship of nasion, point A, and point B and the effect upon ANB. *American journal of orthodontics*. 1969 Aug 1;56(2):143-63.
8. Neela PK, Mascarenhas R, Husain A. A new sagittal dysplasia indicator: the YEN angle. *World journal of orthodontics*. 2009 Jun 1;10(2).
9. Roy P, Nambiar S, Unnikrishnan B, Desai A, Suresh C. Assessment of Sagittal Skeletal Base Relationship of Maxilla and Mandible by Horizontal Appraisal Method—A Comparative and Reliability Study. *Journal of Orofacial Sciences*. 2018 Jul 1;10(2):80.
10. Adenwalla ST, Kronman JH, Attarzadeh F. Porion and condyle as cephalometric landmarks—an error study. *American Journal of Orthodontics and Dentofacial Orthopedics*. 1988 Nov 1;94(5):411-5.
11. Lundström A, Lundström F, Le Bret LM, Moorrees CF. Natural head position and natural head orientation: basic considerations in cephalometric analysis and research. *European Journal of Orthodontics*. 1995 Apr 1;17(2):111-20.
12. Cooke MS, Orth D, Wei SH. A summary five factor cephalometric analysis based on natural head posture and the true horizontal. *American Journal of Orthodontics and Dentofacial Orthopedics*. 1988 Mar 1;93(3):213-23.

