



## **Wrap-Around Implant-Supported Oral Rehabilitation on A Free Fibular Flap Maxillary Reconstruction: A Case Report**

Philippe Harris<sup>1\*</sup>, Ryma Kabir<sup>1</sup>, Alex Pisapia<sup>1</sup>, Nimaat Pertick<sup>1</sup>, Robert Durand<sup>1</sup>, Nabil Benahmed<sup>1\*</sup>, Éric Dufresne<sup>1</sup>, Matthieu Schmittbuhl<sup>1</sup>, Simon-Pierre Charbonneau<sup>1</sup>

*1. Department of Stomatology, Centre Hospitalier Universitaire de l'Université de Montréal (CHUM), Montreal, Canada.*

**\*Correspondence to:** Philippe Harris, Nabil BENAHMED, Department of Stomatology, Centre Hospitalier Universitaire de l'Université de Montréal (CHUM) 1000, Saint-Denis Street, Montreal, QC H2X 0C1 Canada.

### **Copyright**

© 2023 **Philippe Harris, Nabil BENAHMED**. This is an open access article distributed under the Creative Commons Attribution License, which permits unrestricted use, distribution, and reproduction in any medium, provided the original work is properly cited.

Received: 06 July 2023

Published: 01 August 2023

### ***Abstract***

*The free fibular flap maxillary reconstruction technique has improved patients' quality of life as compared to standard obturator rehabilitation. Nevertheless, oral rehabilitation following maxillary reconstruction is often challenging. This clinical report describes the removable oral rehabilitation of a patient with osteosarcoma of the jaw. It aims at familiarizing the reader with a type of prosthetic rehabilitation technique used following a partial resection and reconstruction of the upper maxilla with a free fibular flap. After oncologic surgical treatment and healing, the patient received four dental implants placed into the fibular graft. A transitional prosthesis with an increased vertical occlusal dimension was tried. Finally, the patient was rehabilitated with an dental and implant-supported removable partial prosthesis. The patient reported good function and pleasing esthetics at the one- year follow-up.*

***Keywords:*** *Prosthodontics, Head and neck neoplasms, Free fibula flap, Dental implants.*

### **Introduction**

Osteosarcoma is a type of malignant bone neoplasia. The head and neck region is affected in less than 10% of cases (1, 2). This type of pathology is most prevalent in the mandible. Men in their 30s and 40s are the most at risk of being affected with osteosarcoma of the jaws. Clinical signs such as expansion of bone corticals or dental mobility may be present. Patients may report symptoms of paresthesia or pain. Radiological examination may reveal a sunburst pattern as well as an enlargement of the periodontal ligament (Garrington's sign). Destruction of the cortical bone and extracortical bone formation are often present. However, the radiological appearance of the osteosarcoma is not pathognomonic (3) and a biopsy is necessary to establish the diagnosis. The use of three-dimensional, CT scan imaging helps in the assessment of lesion extension (2-5).

Surgical treatment is usually required and the use of adjuvant radiotherapy is considered if the specimen has closed or positive margins (2).

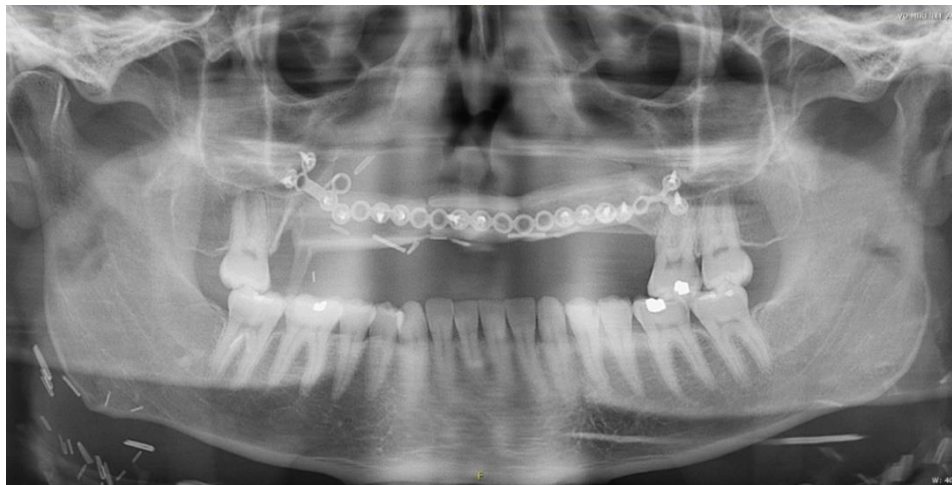In the case of maxillary prosthetic rehabilitation, an obturator is a common solution. However, modern surgical reconstruction techniques are likely to offer closure of post-resection oro-nasal and/or oro-sinusal communications.

The use of a free fibular flap technique following tumor resection was first described in 1989 by Hidalgo in the context of mandibular reconstructions (6). A segment of the patient's fibula bone is taken along with its blood supply. Venous and arterial anastomosis of the graft is performed to ensure blood supply. Additional osteotomies are made on the fibula graft to allow for reproduction of the mandible's shape. Rigid fixation is performed by plates and screws. In 1993, Sadore and Powell described the simultaneous reconstruction of the maxillary and mandible using a fibula segment (7). Both groups reported aesthetic and functional results without the use of an obturator.

Although implants placed in fibulas have a higher failure rate than those placed in native maxillary bone (9% vs. 2.7% for native bone) (8), the success rate remains high. Kramer et al. describe the positive impact of implant-supported restoration on patients' masticatory and swallowing abilities, their phonetics and their quality of life as opposed to conventional prosthetic rehabilitation. The use of implants greatly improves prosthetic retention, especially in cases where hard and soft tissues have been surgically altered (9).

## Case Report

A 34-year-old man was diagnosed with T1 N0 M0-grade anterior maxillary osteosarcoma. Treatment included partial resection surgery of the maxilla, palate and nose, followed by a free fibular flap reconstruction surgery in 2016. Subsequently, the patient was referred to the Maxillofacial Prosthodontics Service at the Centre Hospitalier Universitaire de l'Université de Montréal (CHUM) to undertake the prosthodontic rehabilitation phase.



**Figure 1:** Patient's initial panoramic X-ray

The initial assessment revealed that the middle third of the face had undergone alterations following the surgery. A skin flap extending from the nasolabial fold to the vermilion border substituted the middle part of the upper lip. This displacement did not allow a proper labial seal. The face profile was marked by sagging of the lower nasal portion and loss of upper labial support. The intraoral examination revealed a pilose mobile skin flap replacing the palate's anterior two-thirds. Only teeth #17, 26 and 27 were still present in the upper jaw (Fig. 1). Tooth #17 was partially covered by the flap. Additionally, the maxillary buccal vestibule was absent. No mandibular alterations of the teeth or soft tissues were noticed.

### **Treatment Planning and Prosthetic Oral Rehabilitation Options**

In the context of [1] a lack of inter-arch space, [2] a lack of upper lip mobility and [3] a sagging of the face's middle third, three prosthetic rehabilitation options were considered. These included [1] a conventional teeth-supported removable partial denture, [2] an implant-supported removable partial prosthesis and [3] an implant-supported fixed prosthesis.

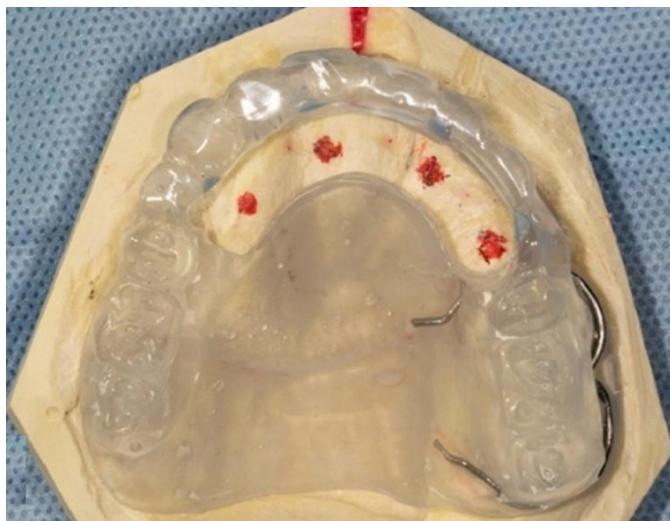
A conventional teeth-supported removable partial prosthesis was not favoured, due to envisioned lack of retention. Indeed, the reduced number of remaining teeth combined with the skin graft's mobility were unfavourable factors for a removable partial denture.

The adequate position of the fibula graft, the available bone volume as well as the absence of previous radiotherapy were favourable factors in choosing an implant-supported prosthesis restoration. Given the significant thickness of the skin graft around implants, a removable prosthesis was favored for ease of hygiene. Thus, the option of an implant-supported removable partial prosthesis was discussed and proposed to the patient.

### Implant Placement Surgery

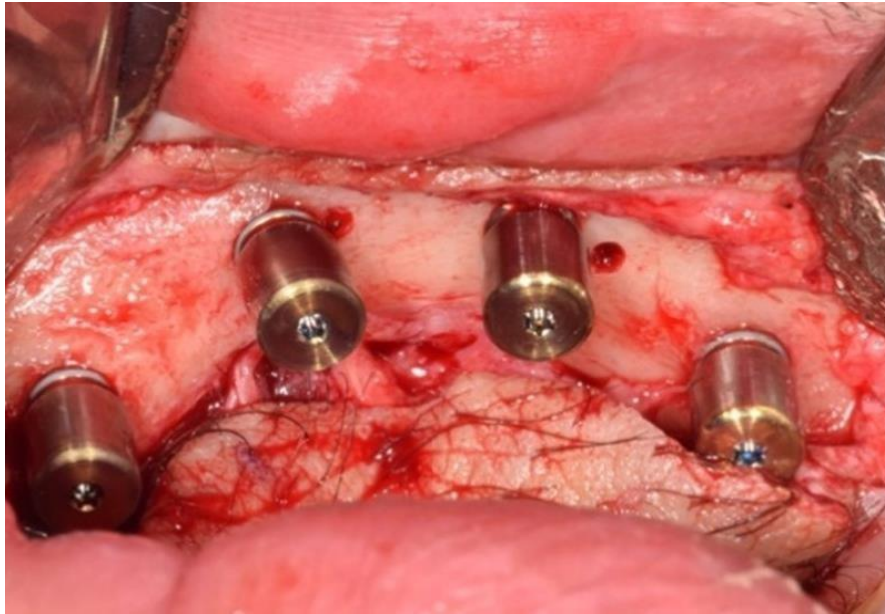
A radiological evaluation done by cone beam computed tomography (CBCT) with a radiological guide was carried out during the planning phase. Bone volumes were identified and quantified. Graft reconstruction yielded an osseous volume of variable height and thickness (apicocoronal height between 8 and 12 mm, buccolingual width between 9 and 14 mm). The positioning of 4 implants spread evenly on the edentulous ridge was considered during the planning in order to optimize the distribution of occlusal forces and to ensure the stability of the prosthesis.

Implant surgery was performed in an operating room under general anesthesia to ensure the patient's comfort and to limit the risk of severing the flap's vascular bundle during dissection. A surgical guide was used to ensure maximal precision during implant placement (Fig. 2A).



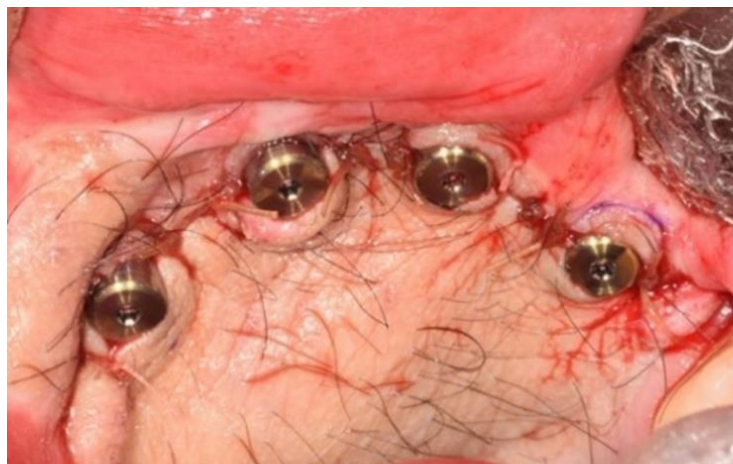**Figure 2:** Surgical Guide

An incision was made at the junction of the skin flap and the adjacent upper labial mucosa. The skin flap thickness above the fibula bone measured around 7 mm (Fig. 3).



**Figure 3:** Four 4.3 x 10 mm implants with their 7 mm healing abutments

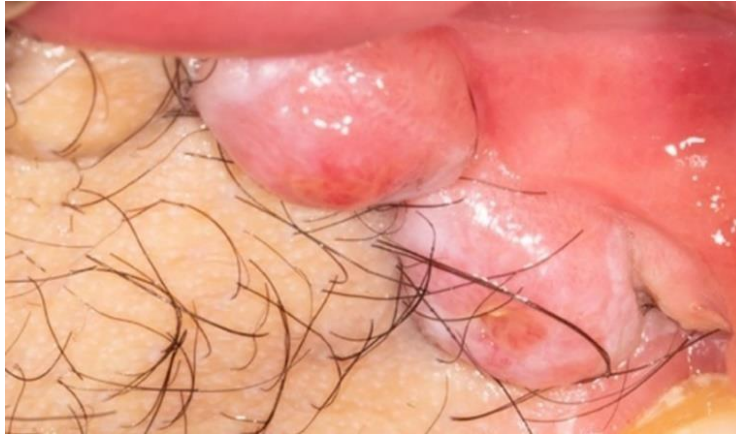Four Nobel Replace Conical Connection TiUltra RPTM (Nobel Biocare Inc., Kloten, Switzerland) implants of 4.3 x 10 mm were placed in positions #12, 14, 22 and 24 according to manufacturer's drilling protocol. The healing abutments were are juxta-mucous despite their 7 mm height due to the flap thickness (Fig. 4). A six-month healing period was followed before initiating the prosthetic phase.



**Figure 4:** Flap sutured in place

### Peri-implant Soft Tissue Management

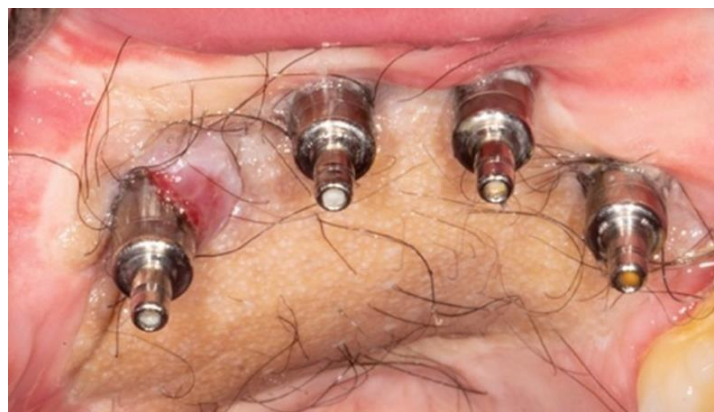Peri-implant tissue management represented a clinical challenge. Skin flaps do not share the same characteristics as mucogingival tissues. Soft tissues' mobility and lack of attachment around implants resulted in increased inflammation and hyperplastic tissues (Fig. 5).



**Figure 5:** 6 months after implants placement, erythematous hyperplastic tissue covers the healing abutments.

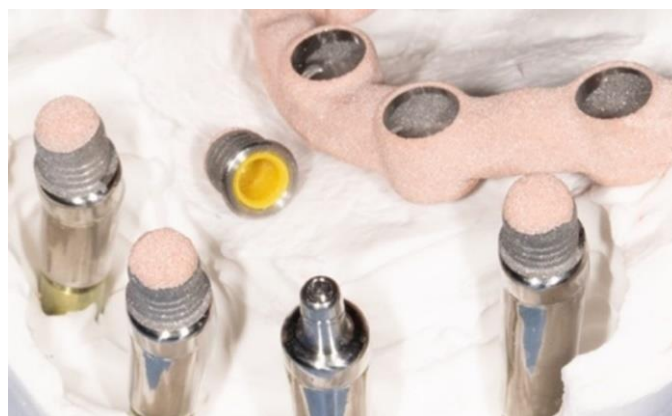Thus, once the implants obtained adequate osseointegration at 6 months, surgical excision of the hyperplastic, erythematous, non-keratinized granulation tissue around the healing abutments was necessary. Palatal skin flap thickness was also reduced.

Seven months after the first tissue correction, a second skin flap reduction surgery was performed. During this surgery, the custom-made transmucosal prosthetic abutments were placed.



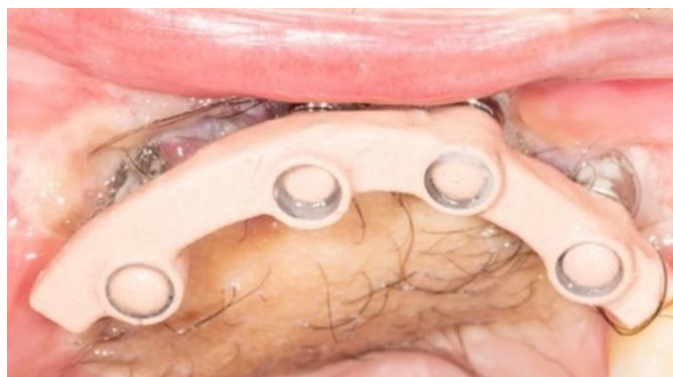**Figure 6:** Peri-implant tissues 22 months after implant placement

Following this second surgical revision, the peri-implant tissues were stabilized and the patient reported significant improvement in comfort. Adequate intaglio adaptation to the surrounding tissues helped prevent further tissue hyperplasia. A prosthetic design including an Integrated Bar™ (Panthera Dental Inc., Quebec, Canada) was retained by the restorative team. This system is similar to that of Locators® (Zest Dental Solutions Co., Carlsbad, CA, USA) in its inclusion of retention pieces lined with a nylon sheath which is affixed to a metal portion connected to the implants (Fig. 7).



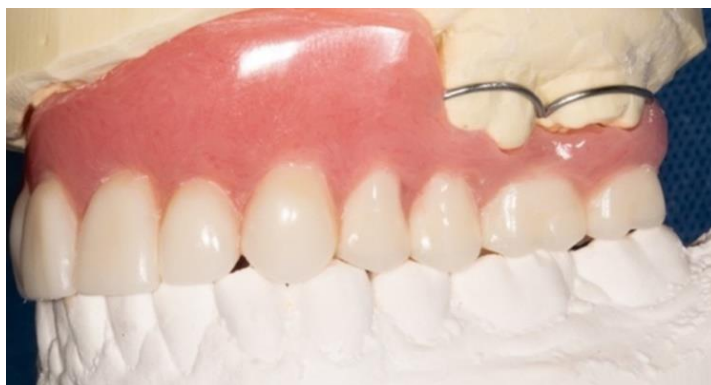**Figure 7:** Implant retention system

In addition, the custom-made intermediate prosthetic abutments manufactured from Pantera Dental make it possible to reach the required height and parallelize the male portions, which increases the system's retention and reduces the wear and tear of nylon sheaths (Fig. 7). To ensure passivity between implants and the bar, the implants female retention elements were reindexed with a composite cement (3M™ ESPE™ RelyX™ Unicem, 3M Co., Maplewood, MN, USA) on a bar that is itself wrapped around the final prosthesis (Fig. 8).



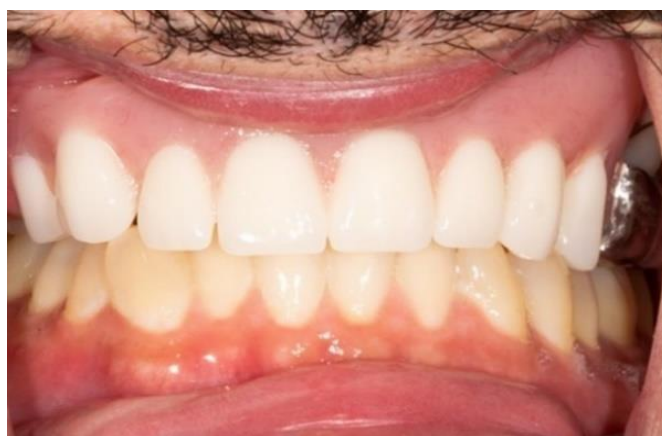**Figure 8:** The female retention elements are reindexed within the integrated bar directly in the mouth.

Therefore, the prosthesis used was a removable acrylic partial prosthesis with a double chrome/cobalt mesostructure, including the Integrated Bar™ being the built-in bar. The other metal structure was the partial's metal skeleton and the two structures were joined together by acrylic. The retention of the prosthesis was ensured by the 4 implants and the remaining 3 teeth #17, 26 and 27. The four custom made transscrewed implants abutments were paired to the Integrated Bar™ female attachments by way of resilient compressible nylon sheaths.



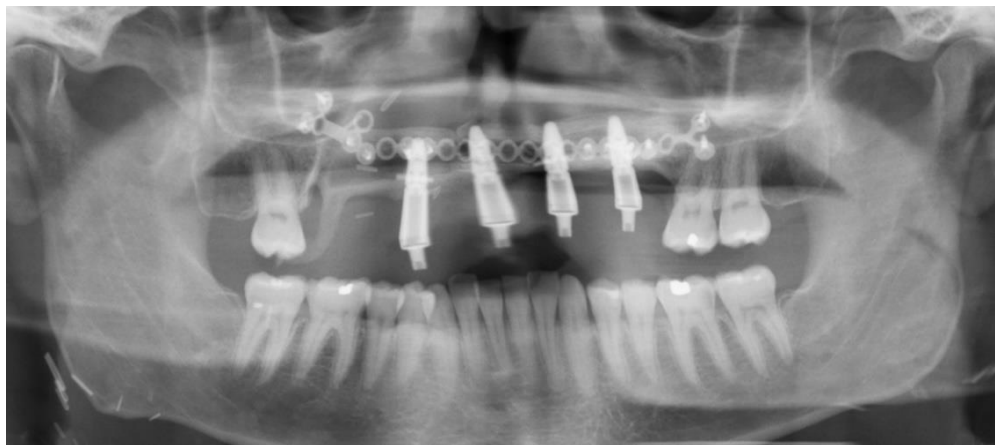**Figure 9:** Removable transition prosthesis

The patient's comfort and adaptation to the newly increased vertical dimension of occlusion (VDO) was verified using a removable transition prosthesis (Fig. 9). The final prosthesis was fitted with a metal frame that covered the occlusal surfaces of the remaining posterior teeth. Cast circumferential clasps were placed on teeth #26 and 27. Intaglio's acrylic allowed for easy adjustments to maintain adequate soft tissue adaptation over time.



**Figure 10:** Final prosthesis during lip retraction

At the one-year follow-up, the patient was still satisfied with the aesthetics and chewing function provided by the implant-supported prosthesis. Adequate daily hygiene was confirmed by the healthy appearance of peri-implant tissue.



**Figure 11:** Panoramic X-ray 11 months after implant placement

## Discussion

While an implant-supported prosthesis is preferred in cases of extensive partial edentation rehabilitation with adequate bone volume, proper management of prosthodontic parameters must be taken into consideration. A thorough prosthodontic evaluation, along with a proper discussion of the patient's therapeutic goals is required to ensure optimal treatment planning, to respect the

patient's wishes and to optimize treatment outcomes. Good results and success rates of 98% were reported in the literature for implants placed in a fibular flap (10).

For this specific patient, interocclusal space was insufficient for a bar-supported removable prosthesis, and an increase of 7 mm in the VDO was required. The major limitation was access and oral hygiene with the excessive amount of soft tissue. Hygiene access was optimized with the placement of oversized prosthetic abutments to compensate for the high thickness of the peri-implant soft tissues.

However, the increased abutments heights increased the risk of implant overload since they were acting as levers when transmitting forces to the implants, especially during lateral and protrusive movements. Pairing of the implants was thus required to maximize the resistance to various occlusal forces.

In this context, a bar-supported system would have made it possible to offer adequate retention and stability in addition to allowing distribution of occlusal forces through implant splinting.

However, since this system would have significantly complicated hygiene for the patient, it was not retained. On the other hand, a system of individual fasteners such as Locators® would have greatly facilitated hygiene. Unfortunately, there are currently no Locators® abutments at this height.

An Integrated Bar™ system including retention pieces lined with a nylon sheath affixed to a metal portion connected to the implants was used for several reasons. This resilient retention system limits stress applied to the implants and potential loss of retention overtime. In addition, it provides additional structure strength, ensures greater passivity of the sheaths, and minimizes the micromovements associated with indexation in the acrylic.

## Conclusion

Patients treated for osteosarcomas of the jaw face significantly loss of function and esthetics after resective surgeries. This clinical report presented a successful case of oral rehabilitation using an implant-supported removable prosthesis following maxillectomy and free fibular flap reconstruction. Patient satisfaction at the one-year follow-up was high for both aesthetics and function. However, considering the significant tissue thickness around the implants and the difficult hygiene access to the implants, the risk of peri-implantitis is higher in the long term, resulting in the necessity to regularly assess periodontal health around the implants.

The collaboration of several medical and dental specialists combined with the use of custom- made prosthetic abutments with a wrap-around bar led to a functional and esthetic result with this challenging case. We therefore emphasize the importance of teamwork and interdisciplinarity not only when approaching complex cases, but also when conducting routine work in dentistry.

## References

1. Fernandes R, Nikitakis NG, Pazoki A, Ord RA. Osteogenic Sarcoma of the Jaw: A 10-Year Experience. *Journal of Oral and Maxillofacial Surgery*. 2007;65(7):1286-91. doi: 10.1016/j.joms.2006.10.030.
2. Mendenhall WM, Fernandes R, Werning JW, Vaysberg M, Malyapa RS, Mendenhall NP. Head and neck osteosarcoma. *American Journal of Otolaryngology*. 2011;32(6):597-600. doi: 10.1016/j.amjoto.2010.09.002.
3. Cawson RA, Odell EW, Porter S. *Cawson's Essentials of Oral Pathology and Oral Medicine*. 7 ed: Churchill Livingstone - Elsevier Science Limited; 2002 2002. 402 p.
4. Lee Y, Van Tassel P, Nauert C, Raymond A, Edeiken J. Craniofacial osteosarcomas: plain film, CT, and MR findings in 46 cases. *American Journal of Roentgenology*. 1988;150(6):1397-402. doi: 10.2214/ajr.150.6.1397.
5. Brenner W, Bohuslavizki KH, Eary JF. PET Imaging of Osteosarcoma. *Journal of Nuclear Medicine*. 2003;44(6):930-42.
6. Hidalgo DA. Fibula free flap: a new method of mandible reconstruction. *Plastic and Reconstructive Surgery*. 1989;84(1):71-9.
7. Sadove RC, Powell LA. Simultaneous maxillary and mandibular reconstruction with one free osteocutaneous flap. *Plastic and Reconstructive Surgery*. 1993;92(1):141-6.
8. Ch'ng S, Skoracki RJ, Selber JC, Yu P, Martin JW, Hofstede TM, et al. Osseointegrated implant-based dental rehabilitation in head and neck reconstruction patients. *Head & Neck*. 2016;38(S1):E321-E7. doi: 10.1002/hed.23993.

9. Kramer F-J, Dempf R, Bremer B. Efficacy of dental implants placed into fibula-free flaps for orofacial reconstruction. *Clinical Oral Implants Research*. 2005;16(1):80-8. doi: 10.1111/j.1600-0501.2004.01040.x.
10. Sozzi D, Novelli G, Silva R, Connelly ST, Tartaglia GM. Implant rehabilitation in fibula-free flap reconstruction: A retrospective study of cases at 1–18 years following surgery. *Journal of Cranio-Maxillofacial Surgery*. 2017;45(10):1655-61. doi: 10.1016/j.jcms.2017.06.021.

