



Esthesioneuroblastoma of Sphenoid Sinus- A Case Report

Dr. Pramod Chirakkal ^{*1}, Dr. Amira Nasser Al Hail ², Prof. Dr. Arunachalam Ravikumar ³

1,2. Department of ENT, Head & Neck surgery (Al Wakra Hospital, Hamad Medical corporation).

3. Department of ENT, Head & Neck surgery (SRM Institute of Science and Technology).

***Correspondence to:** Dr. Pramod Chirakkal, Department of Otorhinolaryngology and Head & Neck surgery, Al Wakra Hospital, Hamad Medical corporation, Doha- Qatar P.O Box 82228

Copyright

© 2023 **Dr. Pramod Chirakkal**. This is an open access article distributed under the Creative Commons Attribution License, which permits unrestricted use, distribution, and reproduction in any medium, provided the original work is properly cited.

Received: 02 June 2023

Published: 20 June 2023

Abstract

Esthesioneuroblastoma (ENB) is a rare malignant neoplasm of the nasal vault that arises from the olfactory epithelium. In 1924, Berger and Luc first described the tumor in the French medical literature under the name *esthésioneuroépithéliome olfactif*. In an extensive literature review, Broich et al. found about 1000 new cases reported; Most cases (80%) were reported within the last 20 years. This is certainly the result of better recognition of this disease entity by pathologists, although the possibility of a rising incidence cannot be entirely ruled out. In view of the lack of precise epidemiologic studies, the authors' data suggest an incidence of 1 case per 1,000,000 per year. We present a unique case on its own where a biopsy of the sphenoid sinus mass revealed ENB.

Introduction

A 73-year-old woman was apparently normal one month back when she presented with a global type headache on & off and two episodes of instability associated with vomiting, which lasted up to 5-10 minutes and stopped without any treatment. The patient had similar episodes after 2-3 weeks. She had no history of associated epistaxis, diplopia, or sensory changes. Initially, she was examined and evaluated by a neurosurgeon that was unremarkable, and later she was referred to us. On clinical examination, the patient was asymptomatic. Ear, nose & throat examination found were unremarkable. Diagnostic nasal endoscopic examination revealed mucoid discharge in the sphenoidal recess of the right nasal cavity. Examination of the left nasal cavity was normal.

Computed tomography (CT) showed a soft tissue mass filling the posterior aspect of the sphenoid sinus that extends from the upper clivus. This lesion was an eroding body of the pterygoid and the greater wing of the right sphenoid. An erosion of medial wall of the cavernous sinus was also observed bilaterally and superiorly in the sella turcica. The entire sphenoid body, the upper clivus, the lesser and greater wing of the sphenoid and their inner table was expanded and replaced by mass.

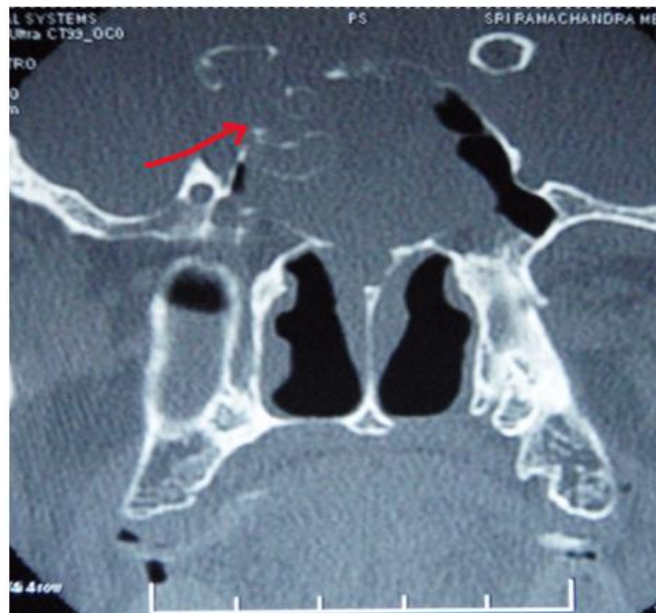Magnetic resonance imaging (MRI) revealed a soft tissue lesion with a cystic component involving the sphenoid clivus. The lesion had infiltrated the adjacent posterior ethmoids and the right optic foramen. Minimum extension into right orbit along with infiltration into bilateral cavernous sinus was observed. However, the bilateral cavernosal internal carotid artery showed a normal flow void.

The patient was subjected to endoscopic assisted biopsy of the right sphenoid mass under GA, and revealed pulsatile herniation of the dura arising from the posterior and right posterosuperior wall of the right sphenoid sinus. A mass was found that occupied the intersphenoid sinus and extended across to the left sphenoid sinus. The right carotid canal was not identifiable and the right optic canal wall was thinned out. The right sphenoid ostium was found open. The left sphenoid ostium was found to be blocked. And a jelly-like mass was found covering the herniating mass. An endoscopic biopsy was taken.

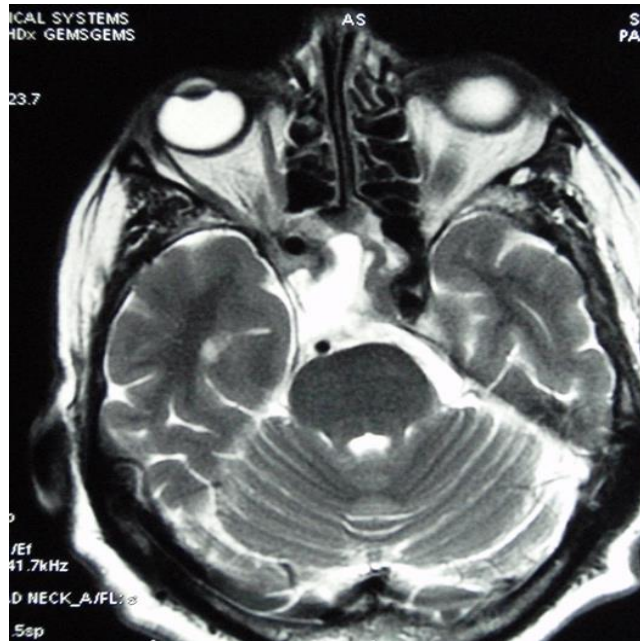
Histopathological examination showed a small blue cell tumor composed of monotonous sheets of small uniform cells with round nuclei and scanty cytoplasm interspersed with several rosettes. These cells were separated by fibrovascular stroma. The pseudo-stratified ciliated columnar epithelium was evident in some of the foci.

When histological and immunohistochemical characteristics were correlated, the diagnosis was summarized to that of grade 1 esthesioneuroblastoma.

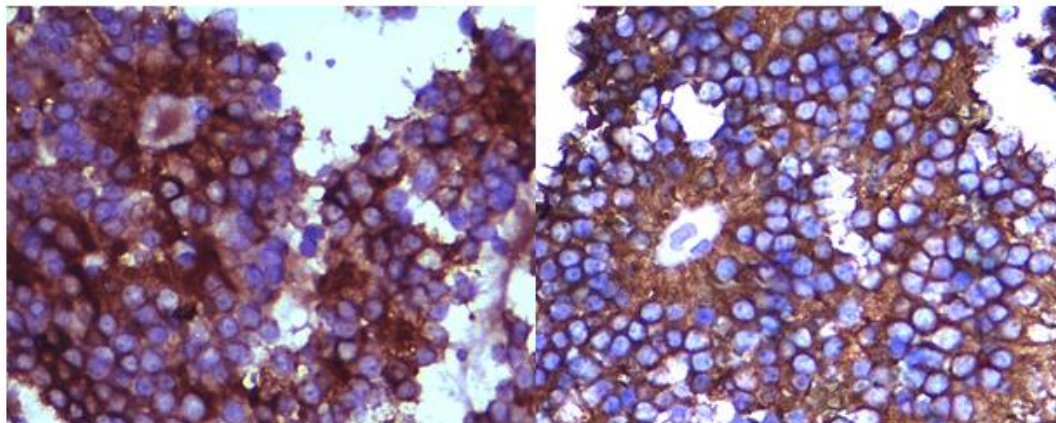
Taking into account the age of patient and the asymptomatic profile of the lesion, the recommended treatment was chemotherapy by a medical oncologist consisting of cisplatin (33 mg/m²/d) and etoposide (100 mg/m²/d). During the first follow-up after 3 months she was asymptomatic and a diagnostic endoscopy was performed which did not show further extension of the lesion.



Computed tomography (CT) coronal image demonstrating soft tissue mass filling posterior aspect of sphenoid sinus extending from the upper clivus. Eroding body of pterygoid and greater wing of right sphenoid. Erosion of medial wall of cavernous sinus bilaterally and superiorly sella turcica.



(Axial magnetic resonance imaging (MRI) shows findings similar to computed tomography (CT) images)



Synaptophysin X20

Chromogranin X40

Immunohistochemistry for chromograin and synaptophysin revealed diffuse intense cytoplasmic positivity. EMA, S100,GFAP, and CD45 were all negative.H&E small cells in rosette X40

Discussion

Esthesioneuroblastoma is a rare tumor that arises from the olfactory epithelium and has a predilection for invading surrounding regions, such as the paranasal sinuses, orbits, and skull base and was first described in 1924 in the French medical literature, and since that time, this tumor continues to be uncommon. The true incidence is difficult to ascertain; however, it can account for 3% of all intranasal tumors. The most common symptoms in patients with this tumor may include nasal obstruction, epistaxis, anosmia, and headache. Most of these symptoms are nonspecific and patients often present with locally advanced disease. A unilateral mass within the nasal cavity is frequently noted at presentation. However, our patient did not reveal any such lesion. Initially, due to the rarity of esthesioneuroblastoma, we theorized that patient had a tumor on the right side, as indicated by opacification on CT/MRI images.

The diagnosis of this tumor can initially be difficult, and it has been referred to as ‘the great imposter.’ Many tumors may mimic an esthesioneuroblastoma, and one must be aware of the differential diagnosis, particularly in a situation such as ours where the specific tumor is not only rare but the contiguous pathway of the lesion was highly unlikely. Specific tumors to be aware of include inverted papilloma, squamous cell carcinoma, adenocarcinoma, sinonasal undifferentiated carcinoma, hemangioma, and metastatic carcinoma. Certainly, in addition to imaging, the diagnosis must be made definitively through histopathology. Homogeneous small cells in rosette or pseudorosette formation characterize a well-differentiated esthesioneuroblastoma, whereas an undifferentiated esthesioneuroblastoma consists of anaplastic hyperchromatic small cells with little cytoplasm. The latter may be difficult to diagnose; therefore, further studies in the form of electron microscopy and immunohistochemical staining should be performed.

Taking into account the age of our patient and the asymptomatic profile of the lesion, the recommended treatment was chemotherapy by a medical oncologist. Recurrence could occur years after the end of treatment, often more than 10 years; therefore, prolonged follow-up is required.

References

1. Broich G, Pagliari A, Ottaviani F. Esthesioneuroblastoma: a general review of the cases published since the discovery of the tumour in 1924. *Anticancer Res.* Jul-Aug 1997;17(4A):2683-706.
2. Constantinidis J, Steinhart H, Koch M. Olfactory neuroblastoma: the University of Erlangen-Nuremberg experience 1975-2000. *Otolaryngol Head Neck Surg.* May 2004;130(5):567-74.
3. Devaney K, Wenig BM, Abbondanzo SL. Olfactory neuroblastoma and other round cell lesions of the sinonasal region. *Mod Pathol.* Jun 1996;9(6):658-63.
4. Dias FL, Sa GM, Lima RA. Patterns of failure and outcome in esthesioneuroblastoma. *Arch Otolaryngol Head Neck Surg.* Nov 2003;129(11):1186-92.
5. Dulguerov P, Calcaterra T. Esthesioneuroblastoma: the UCLA experience 1970-1990. *Laryngoscope.* Aug 1992;102(8):843-9.
6. Dulguerov P, Allal AS, Calcaterra TC. Esthesioneuroblastoma: a meta-analysis and review. *Lancet Oncol.* Nov 2001;2(11):683-90.
7. Dulguerov P, Allal AS. Nasal and paranasal sinus carcinoma: how can we continue to make progress?. *Curr Opin Otolaryngol Head Neck Surg.* Apr 2006;14(2):67-72.
8. Koka VN, Julieron M, Bourhis J. Aesthesioneuroblastoma. *J Laryngol Otol.* Jul 1998;112(7):628-33.
9. Loy AH, Reibel JF, Read PW. Esthesioneuroblastoma: continued follow-up of a single institution's experience. *Arch Otolaryngol Head Neck Surg.* Feb 2006;132(2):134-8.
10. Min KW. Usefulness of electron microscopy in the diagnosis of "small" round cell tumors of the sinonasal region. *Ultrastruct Pathol.* Sep-Oct 1995;19(5):347-63.
11. Mishima Y, Nagasaki E, Terui Y. Combination chemotherapy (cyclophosphamide, doxorubicin, and vincristine with continuous-infusion cisplatin and etoposide) and radiotherapy with stem cell support can



be beneficial for adolescents and adults with esthesioneuroblastoma. *Cancer*. Sep 15 2004;101(6):1437-44.