



## Operative Treatment VS. Long term Follow up of Thyroid Nodules in Pediatric Age

Dr. Basel Zoudeh\*<sup>1</sup>

**Corresponding Author: Dr. Basel Zoudeh**, Department of Endocrinology Pediatric Endocrinology Mediclinic welcare Hospital Al Garhoud, Dubai, UAE.

**Copy Right:** © 2023 Dr. Basel Zoudeh, This is an open access article distributed under the Creative Commons Attribution License, which permits unrestricted use, distribution, and reproduction in any medium, provided the original work is properly cited.

**Received Date: June 20, 2023**

**Published Date: July 01, 2023**

**Abstarct**

*Adults are frequently diagnosed with thyroid nodules. Although it is uncommon in children, the risk of thyroid cancer is substantially higher in children than among adults. Thyroid nodular disease in children, which can present as either a single nodule or a multinodular goitre, requires a thorough workup that includes a thorough clinical examination, a history of radiation exposure, careful palpation of the thyroid and lymph nodes, blood tests, ultrasonography, and cytological evaluation. The gold-standard treatment for paediatric thyroid nodules is thyroid surgery, but there is still debate regarding how extensive the procedure should be. The decision matrix is forced to concentrate on the advantages of surgery for the child in light of all preoperative tests because surgery carries some risk.*

*While potentially reducing surgery for benign disease, new diagnostic techniques like molecular testing with fine needle aspiration biopsies may aid in differentiating between benign and malignant tumours. This review's goal is to provide an overview of recent developments in the clinical disease treatment of nodular thyroid disease in children, including patient history, physical examination, and diagnostic workup.*

**Key words:** *Pediatrics, Thyroid, Nodules, Oncology, Therapeutics, Cancer*

**Abbreviations**

FMTC: familial medullary thyroid cancer

(MEN2): multiple endocrine neoplasia type 2

MTC: Medullary Thyroid Carcinoma

TPO: Thyroid Peroxidase

TSH: Thyroid Stimulating Hormone

T3: triiodothyronine

T4: Thyroxine

FNAB: Fine Needle Aspiration Biopsy

DTC: Differentiated thyroid cancer.

## Introduction

Thyroid nodules are typically identified in adults, but they are uncommon in children (under the age of 18), where they impact only 1%–2% of the population according to clinical examination [1-4]. Head and neck radiation, being a girl, a lack of iodine, reaching puberty early, and having a family or personal history of thyroid disease are all risk factors for developing thyroid nodules in children [5, 6]. Children's thyroid nodules might be mistaken for other conditions, such as abscesses, lymphatic or vascular abnormalities, ectopic thymus, thyroglossal duct cysts, and tumours. A nodule may also be induced by the palpable changes that Hashimoto's thyroiditis causes in the gland [7]. Solitary nodules, multinodular goitres, nodular goitre seen in autoimmune goitre (chronic lymphocytic thyroiditis presenting as Hashimoto thyroiditis or Graves' disease), and nonpalpable thyroid nodules are all examples of thyroid nodular disease [8]. Differentiating benign from malignant lesions is the population's most difficult conundrum [1]. According to data from a surgical cohort [1, 9-11], children who report with thyroid nodules have a higher prevalence of thyroid cancer than adults. Between 9.2% and 50% [12, 13] of thyroid nodules in children have been found to be malignant, with a mean of 26.4%, whereas between 5% and 15% of thyroid nodules in adults have been reported to be malignant.

The risk of cancer varies depending on how many thyroid nodules are present; this has been a topic of discussion. Although cancer can be present in multinodular thyroid illness, the majority of malignant nodules are identified in uninodular glands [3, 9, 14–16], and the presence of a solitary nodule does not appear to make them considerably more likely to be cancerous [10]. Thyroid cancer accounts for 0.5%–3% of all paediatric malignancies, making it the most prevalent endocrine malignancy in children [6]. The most frequent non-malignant diagnosis in children with thyroid nodules is follicular adenoma [11, 18]. Thyroid carcinomas in children nearly invariably have a distinct malignancy distribution [15], which is comparable to that seen in adults [19, 20].

## Classification of Thyroid Cancer in children

### There are several types of thyroid cancer:

1. Differentiated thyroid carcinoma includes two different types, papillary thyroid carcinoma and follicular thyroid carcinoma. Both of these types of thyroid cancer develop from the cells of the thyroid gland that normally produce thyroid hormone. Papillary carcinoma is the more common type, accounting for about 90 percent of thyroid cancers in children. Follicular carcinoma is less common and accounts for about 10 percent of cases.

2. Medullary thyroid carcinoma is very rare and develops in thyroid cells that do not produce thyroid hormone (called C-cells). Medullary thyroid cancer most often occurs in adults. However, there are familial conditions in which children may develop medullary thyroid carcinoma early in childhood or even in infancy. These familial syndromes are called multiple endocrine neoplasia type 2 (MEN2) or familial medullary thyroid cancer (FMTC).
3. Anaplastic thyroid cancer is an extremely rare and aggressive type of thyroid cancer that occurs almost exclusively in adults.

### **Case Study**

The first case is a 17-year-old girl who presented with difficulty in swallowing, she has positive family history of thyroid disease.

On exam, she had right thyroid big nodule with Lymphadenopathy. FNA resulted Follicular epithelial cells. She underwent total thyroidectomy and final pathology was Follicular carcinoma.

The second case is a 14-year-old boy who presented with Goiter, he has negative family history of thyroid disease. On exam he has goiter on right thyroid lobe, with no adenopathy.

FNA resulted suspicious for follicular neoplasm. He underwent right hemi thyroidectomy and the final pathology was benign colloid/adenomatoid nodule.

A thyroid nodule may be found accidentally during neck imaging or by a doctor performing a routine physical examination. It may also be found by patients themselves. However, the majority (75%) of paediatric patients with asymptomatic neck tumours had benign or malignant nodules [23]. Tachycardia, elevated differential pressure, weight loss with increased appetite, heat intolerance and increased sweating, diarrhoea, and exophthalmia are just a few of the clinical signs of hyperthyroidism [26]. Bradycardia, lowered differential pressure, decreased appetite with weight gain, hyperhidrosis, constipation, and tremors are some of the clinical signs and symptoms of hypothyroidism that contrast [26]. For children presenting with benign and malignant lesions, respectively, the average time before a thyroid nodule diagnosis is made is between 5 and 6 months [27].

Paediatric thyroid nodular illness has been associated with more females than boys, with a female to male ratio of 3:1 or higher [15, 17, 29], albeit this has not been independently verified [28]. According to Scholz et al. [29], this ratio sharply drops to 1.25/1 in children under the age of 10, and the incidence of thyroid nodules and cancer peaks in adolescence (12–16 years) with a mean and median of 12 and

13. In Yip et al.'s research [14], Male prepubescent youngsters under the age of 12 were more likely to get cancer. According to Scholz et al. [29], younger children with thyroid nodules had a higher risk of malignancy (48% in children under 10 years old) than older children (33% in children older than 10 years). The mean age of patients with malignant lesions is 16.4 years, compared to 14.5 years for patients without lesions, suggesting that older patients are more at risk for cancer [14]. Since puberty is also the time when the well-documented female sex preponderance in thyroid disease is first noticed [30, 31], it has been hypothesised that increased sex hormone levels during puberty may contribute to thyroid carcinogenesis [6].

The age of the children included, inclusion or exclusion linked to pathologic diagnosis, and whether the studies were retrospective or prospective in character could all be factors in the stated gender differences' lack of support. Table 1 lists additional clinical indicators of thyroid cancer that may be present.

	Case 1	Case 2
Age	17	14
Sex	girl	boy
Ethnicity	UAE	Jordanian
Chief complaints	Difficulty in swallowing	Goiter
Thyroid symptoms	None	None
Family history of thyroid Disease	Positive Thyroid Carcinoma (PTC)	Negative
Autoimmunity	Negative	Negative
Vitals (heart rate & blood pressure)		Normal
Physical Examination	Right thyroid big nodule with Tracheal deviation to left	Goiter
Lymphadenopathy neck	Multiple lymph nodes are seen in the jugulodigastric trunk at level 2 and 3	None
Labs	Normal TSH, FT4 Calcitonin	Normal TSH, FT4 Calcitonin
Thyroid replacement Medication	None	None

Ultrasound Thyroid (dimensions in cm)	The right lobe: 5.3 x 4.1 x 8.5 cm.  Right side nodule: 5.3 x 4.1 x 5.8 cm.  Left Lobe: 3.3 x 0.9 x 1.3 cm	The right Lobe: 4.4 x 1.6 x 2.4 cm  Nodule right side: 2.6 x 1.6 x 1.9 cm  Left Lobe: 4.1 x 0.9 x 1.4 cm
Nodule features	Solid Hypoechoic, poorly defined	Hypoechoic, calcifications, increase vascularity
FNA Thyroid and Pathology report	Follicular epithelial cells, Bethesda Category 2.	Suspicious for a Follicular neoplasm. Bethesda IV.
Other imaging	CT Scan neck: Multiple lymph nodes are seen in the jugulodigastric trunk at Level 2 and 3	None
Treatment	Total thyroidectomy and ablation with iodine 131	Right hemithyroidectomy
Final Pathology	Follicular carcinoma	Benign colloid/adenomatoid nodule
Post-surgery labs	Elevated TSH, Low FT4 started levothyroxine. Normal calcium	TSH, FT4 normal Calcium normal
Follow up	Thyroglobulin <0.040	

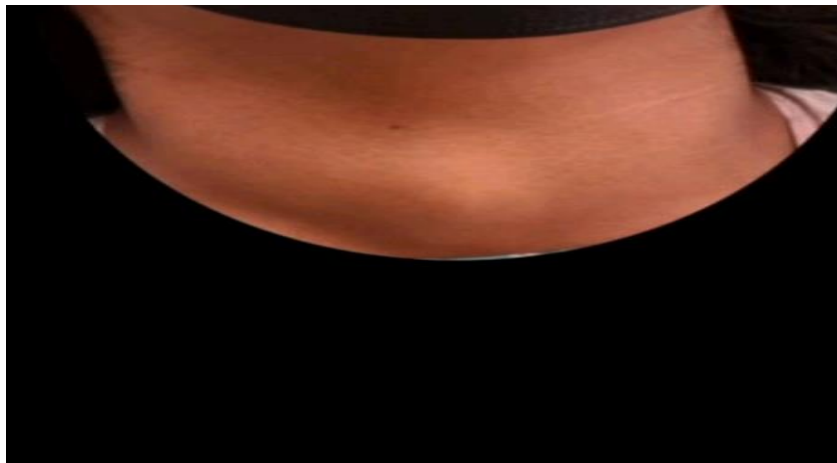
**Table: 1**

### **Treatment**

Thyroid problems are managed surgically using a variety of techniques, such as lobectomy, near total thyroidectomy, and total thyroidectomy. The idea of categorising thyroid operations into two general categories—lobectomy or complete thyroidectomy—is currently supported. Diagnoses, surgical alternatives, and the long-term effects of such management call for discussion between the doctor and the child's guardians as a measure of fully informed consent in all situations where surgical management is advised.

The initial course of treatment for thyroid nodules is determined by the clinical picture and the findings of the diagnostic tests. Surgical resection can be avoided if a patient has benign cytology without worrisome nodules and no cancer-related risk factors [10, 21, 24]. Re-evaluation with FNAB or surgical excision is advised if the nodule grows during the follow-up or measures more than 4 cm in diameter [26]. A heated nodule that usually corresponds to a toxic adenoma might cause hyperthyroidism symptoms. Thyroid lobectomy is advised if it is limited to the gland [23, 27]. Although there may be a link between cold nodules and a higher risk of cancer, the patient's entire clinical picture and FNAB should be taken into consideration when deciding whether to perform surgery.

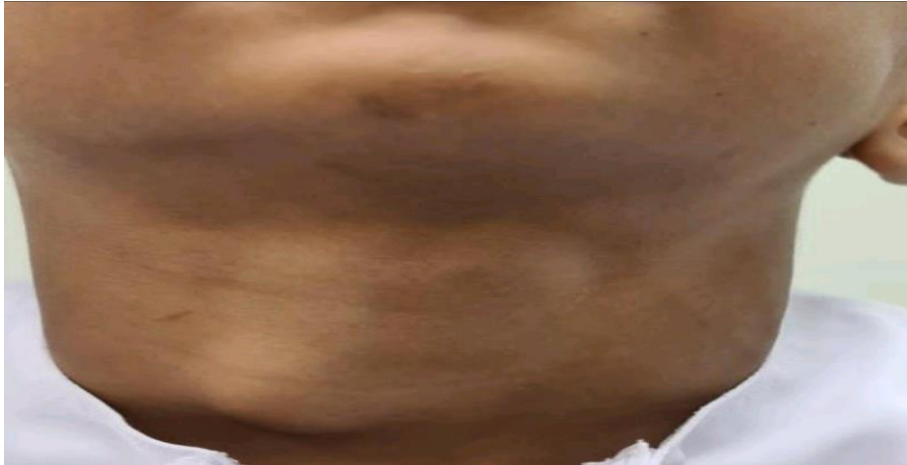Surgical resection can be avoided if a patient has benign cytology without any worrisome nodules and no cancer-related risk factors. Re-evaluation with FNAB or surgical removal is necessary if the nodule grows larger over the course of the follow-up or measures more than 4 cm in diameter.



The purpose of surgical intervention in patients with a worrisome cytological result on FNAB is to provide diagnostic histology. A lobectomy is advised as the initial operation for children who have a unilateral nodule that is suspect of being a follicular neoplasm, followed by a total thyroidectomy if the cancer diagnosis is confirmed by operative histology [7].

A complete thyroidectomy is advised in situations of bilateral nodularity when malignancy is clinically suspected and cytologically diagnosed [98]. Total thyroidectomy is the main form of treatment for thyroid cancer that has been well differentiated (DTC). The extent of surgery for DTC is debatable in some situations, though. By removing as much healthy thyroid tissue as possible, total thyroidectomy increases the effectiveness of postoperative radioiodine scanning and subsequent ablation. Additionally, a total thyroidectomy allows for a more precise assessment of the blood thyroglobulin

level following surgery, which is a crucial adjunct to detecting recurrent disease [46]. These advantages are particularly significant for young children because they have considerably greater rates of thyroid cancer metastasis and recurrence [47]. When compared to children treated with complete thyroidectomy, lobectomy-only patients have significantly higher recurrence rates.



Early cervical lymph node involvement in DTC in children is frequently observed, occurring in 27%–83% of paediatric cases as opposed to 20%–50% in adult instances. There is ongoing dispute over how many lymph nodes should be removed, and there are little data on paediatric patients. A lymph node excision is more successful than cherry picking at preventing recurrent illness in patients who present with a positive central cervical lymph node during a preoperative US evaluation [100]. This consensus was supported by Dinauer et al., who recommended a complete thyroidectomy with uni- and bilateral central compartment lymph node dissection (level VI) for children with DTC and positive lymph node disease.

The hyoid bone, the substernal notch, the median carotid sheath, and the prevertebral fascia serve as the boundaries of this compartment on the superior, inferior, lateral, and dorsal sides, respectively. The rates of survival are comparable to those with node-negative illness. According to a recent study, prophylactic dissection of the central compartment lymph nodes on the ipsilateral side of the tumour is advised due to concerns about the possibility of follicular thyroid cancer because of the high prevalence of local lymph node involvement in children with DTC, even if no lymph node metastasis is evident during a preoperative evaluation. This is different from adult therapy, where preventive lymph node dissection of any kind should not be used to treat follicular thyroid cancer. However, more research is need to support this therapy in paediatrics.

Thyroid cancer in children might infiltrate lymph nodes in the lateral neck. Research on adults is the foundation for management recommendations for children. Only patients with obvious metastases (clinically or on preoperative US or FNAB) [9], including those with thyroid cancer T1 or greater and microcarcinoma (1 cm), should undergo lateral neck dissection. The most recent research has shown that despite the rarity of this cancer in children, central or lateral lymph node metastases is far more common than recurrence after surgery.

Regardless of the size of the lesion, complete thyroidectomy and preventive bilateral central neck dissection are recommended for children with MTC [46]. In fact, 40% of these carcinomas spread to the lymph nodes on the opposite side, and 80% of them spread to the central ipsilateral cervical lymph nodes [105]. A lateral compartment lymph node dissection must be done if lateral lymphadenopathy is seen clinically or radiographically and the FNAB test is positive. Complications from thyroid surgery, including lobectomy and complete thyroidectomy, are possible. Surgery may be linked to hypoparathyroidism, recurrent laryngeal nerve injury, or haemorrhage, notwithstanding their rarity in occurrence. Due to their smaller anatomy, younger children—especially those under 4 years old—have a higher risk of problems. A surgeon's experience and operating volumes have been demonstrated to be important predictors of morbidity in thyroid surgery; risks can be reduced in the hands of surgeons with extensive experience, defined as those who have conducted more than 100 thyroidectomies in 6 years.

## **Conclusion**

Although benign thyroid nodules in children are the majority, it is important to distinguish benign from malignant lesions during the initial workup. Palpable cervical lymphadenopathy stands up as the highest predictor of thyroid cancer in children among a number of clinical prognostic markers of malignancy documented in the literature. The initial workup involves a blood test to measure thyroid function, US, and FNAB, even though numerous tools are accessible and used. FNAB continues to be the examination of choice today for making a cancer diagnosis and recommending a surgical course of action. Surgery is the most effective treatment even if it is associated with more complications in children since the risk of cancer is higher in the paediatric population compared to the adult population. The therapy of this illness is currently the subject of heated discussion on paediatric diagnostic and therapeutic techniques. To reach an agreement on the diagnosis and treatment of thyroid nodules in the paediatric population, more research, especially multicenter trials, is required.

## Reference

1. Haveman JW, van Tol KM, Rouwé CW, et al. Surgical experience in children with differentiated thyroid carcinoma. *Ann Surg Oncol*. 2003;10:15–20. [PubMed] [Google Scholar]
2. Arici C, Erdogan O, Altunbas H, et al. Differentiated thyroid carcinoma in children and adolescents. Clinical characteristics, treatment and outcome of 15 patients. *Horm Res*. 2002;57:153–156. [PubMed] [Google Scholar]
3. Dinauer C, Francis GL. Thyroid cancer in children. *Endocrinol Metab Clin North Am*. 2007;36:779–806, vii. [PubMed] [Google Scholar]
4. Kim E-K, Park CS, Chung WY, et al. New sonographic criteria for recommending fine-needle aspiration biopsy of nonpalpable solid nodules of the thyroid. *AJR Am J Roentgenol*. 2002;178:687–691. [PubMed] [Google Scholar]
5. Moon W-J, Jung SL, Lee JH, et al. Benign and malignant thyroid nodules: US differentiation: Multicenter retrospective study. *Radiology*. 2008;247:762–770. [PubMed] [Google Scholar]
6. Saavedra J, Deladoëy J, Saint-Vil D, et al. Is ultrasonography useful in predicting thyroid cancer in children with thyroid nodules and apparently benign cytopathologic features? *Horm Res Paediatr*. 2011;75:269–275. [PubMed] [Google Scholar]
7. Corrias A, Cassio A, Weber G, et al. Thyroid nodules and cancer in children and adolescents affected by autoimmune thyroiditis. *Arch Pediatr Adolesc Med*. 2008;162:526–531. [PubMed] [Google Scholar]
8. Lawrence W, Jr, Kaplan BJ. Diagnosis and management of patients with thyroid nodules. *J Surg Oncol*. 2002;80:157–170. [PubMed] [Google Scholar]
9. Bonnema SJ, Bennedbaek FN, Wiersinga WM, et al. Management of the nontoxic multinodular goitre: A European questionnaire study. *Clin Endocrinol (Oxf)* 2000;53:5–12. [PubMed] [Google Scholar]
10. Panneerselvan R, Schneider DF, Sippel RS, et al. Radioactive iodine scanning is not beneficial but its use persists for euthyroid patients. *J Surg Res*. 2013;184:269–273. [PMC free article] [PubMed] [Google Scholar]
11. White AK, Smith RJ. Thyroid nodules in children. *Otolaryngol Head Neck Surg*. 1986;95:70–75. [PubMed] [Google Scholar]

12. McHenry CR, Danish R, Murphy T, et al. Atypical thyroglossal duct cyst: A rare cause for a solitary cold thyroid nodule in childhood. *Am Surg*. 1993;59:223–228. [PubMed] [Google Scholar]
13. Gharib H. Changing concepts in the diagnosis and management of thyroid nodules. *Endocrinol Metab Clin North Am*. 1997;26:777–800. [PubMed] [Google Scholar]
14. Hamberger B, Gharib H, Melton LJ, 3rd, et al. Fine-needle aspiration biopsy of thyroid nodules. Impact on thyroid practice and cost of care. *Am J Med*. 1982;73:381–384. [PubMed] [Google Scholar]
15. Caplan RH, Strutt PJ, Kisken WA, et al. Fine needle aspiration biopsy of thyroid nodules. *Wis Med J*. 1991;90:285–288. [PubMed] [Google Scholar]
16. Belfiore A, La Rosa GL. Fine-needle aspiration biopsy of the thyroid. *Endocrinol Metab Clin North Am*. 2001;30:361–400. [PubMed] [Google Scholar]
17. Stevens C, Lee JKP, Sadatsafavi M, et al. Pediatric thyroid fine-needle aspiration cytology: A meta-analysis. *J Pediatr Surg*. 2009;44:2184–2191. [PubMed] [Google Scholar]
18. Bargren AE, Meyer-Rochow GY, Sywak MS, et al. Diagnostic utility of fine-needle aspiration cytology in pediatric differentiated thyroid cancer. *World J Surg*. 2010;34:1254–1260. [PubMed] [Google Scholar]
19. Calkovsky V, Hajtman A. Thyroid diseases in children and adolescents. *Bratisl Lek Listy (Tlacene Vyd)* 2009;110:31–34. [PubMed] [Google Scholar]
20. Gutman PD, Henry M. Fine needle aspiration cytology of the thyroid. *Clin Lab Med*. 1998;18:461–482, vi. [PubMed] [Google Scholar]
21. Geiger JD, Thompson NW. Thyroid tumors in children. *Otolaryngol Clin North Am*. 1996;29:711–719. [PubMed] [Google Scholar]
22. Lafferty AR, Batch JA. Thyroid nodules in childhood and adolescence—thirty years of experience. *J Pediatr Endocrinol Metab*. 1997;10:479–486. [PubMed] [Google Scholar]
23. Chang SH, Joo M, Kim H. Fine needle aspiration biopsy of thyroid nodules in children and adolescents. *J Korean Med Sci*. 2006;21:469–473. [PMC free article] [PubMed] [Google Scholar]
24. Degnan BM, McClellan DR, Francis GL. An analysis of fine-needle aspiration biopsy of the thyroid in children and adolescents. *J Pediatr Surg*. 1996;31:903–907. [PubMed] [Google Scholar]

25. Khurana KK, Labrador E, Izquierdo R, et al. The role of fine-needle aspiration biopsy in the management of thyroid nodules in children, adolescents, and young adults: A multi-institutional study. *Thyroid*. 1999;9:383–386. [PubMed] [Google Scholar]
26. Al-Shaikh A, Ngan B, Daneman A, et al. Fine-needle aspiration biopsy in the management of thyroid nodules in children and adolescents. *J Pediatr*. 2001;138:140–142. [PubMed] [Google Scholar]
27. Ardito G, Pintus C, Revelli L, et al. Thyroid tumors in children and adolescents: Preoperative study. *Eur J Pediatr Surg*. 2001;11:154–157. [PubMed] [Google Scholar]
28. Kaur J, Srinivasan R, Arora SK, et al. Fine-needle aspiration in the evaluation of thyroid lesions in children. *Diagn Cytopathol*. 2012;40(suppl 1):E33–E37. [PubMed] [Google Scholar]
29. Willgerodt H, Keller E, Bennek J, et al. Diagnostic value of fine-needle aspiration biopsy of thyroid nodules in children and adolescents. *J Pediatr Endocrinol Metab*. 2006;19:507–515. [PubMed] [Google Scholar]
30. Smith M, Pantanowitz L, Khalbuss WE, et al. Indeterminate pediatric thyroid fine needle aspirations: A study of 68 cases. *Acta Cytol*. 2013;57:341–348. [PubMed] [Google Scholar]
31. Izquierdo R, Arekat MR, Knudson PE, et al. Comparison of palpation-guided versus ultrasound-guided fine-needle aspiration biopsies of thyroid nodules in an outpatient endocrinology practice. *Endocr Pract*. 2006;12:609–614. [PubMed] [Google Scholar]
32. Nikiforov YE, Ohori NP, Hodak SP, et al. Impact of mutational testing on the diagnosis and management of patients with cytologically indeterminate thyroid nodules: A prospective analysis of 1056 FNA samples. *J Clin Endocrinol Metab*. 2011;96:3390–3397. [PMC free article] [PubMed] [Google Scholar]
33. Nikiforov YE, Steward DL, Robinson-Smith TM, et al. Molecular testing for mutations in improving the fine-needle aspiration diagnosis of thyroid nodules. *J Clin Endocrinol Metab*. 2009;94:2092–2098. [PubMed] [Google Scholar]
34. Yamashita S, Saenko V. Mechanisms of disease: Molecular genetics of childhood thyroid cancers. *Nat Clin Pract Endocrinol Metab*. 2007;3:422–429. [PubMed] [Google Scholar]
35. Xing M. BRAF mutation in thyroid cancer. *Endocr Relat Cancer*. 2005;12:245–262. [PubMed] [Google Scholar]

36. Bongarzone I, Fugazzola L, Vigneri P, et al. Age-related activation of the tyrosine kinase receptor protooncogenes RET and NTRK1 in papillary thyroid carcinoma. *J Clin Endocrinol Metab.* 1996;81:2006–2009. [PubMed] [Google Scholar]
37. de Groot JWB, Links TP, Plukker JTM, et al. RET as a diagnostic and therapeutic target in sporadic and hereditary endocrine tumors. *Endocr Rev.* 2006;27:535–560. [PubMed] [Google Scholar]
38. Nikiforov YE, Rowland JM, Bove KE, et al. Distinct pattern of ret oncogene rearrangements in morphological variants of radiation-induced and sporadic thyroid papillary carcinomas in children. *Cancer Res.* 1997;57:1690–1694. [PubMed] [Google Scholar]
39. Collins BJ, Chiappetta G, Schneider AB, et al. RET expression in papillary thyroid cancer from patients irradiated in childhood for benign conditions. *J Clin Endocrinol Metab.* 2002;87:3941–3946. [PubMed] [Google Scholar]
40. Basolo F, Torregrossa L, Giannini R, et al. Correlation between the BRAF V600E mutation and tumor invasiveness in papillary thyroid carcinomas smaller than 20 millimeters: Analysis of 1060 cases. *J Clin Endocrinol Metab.* 2010;95:4197–4205. [PubMed] [Google Scholar]
41. Lassalle S, Hofman V, Marius I, et al. Assessment of morphology, antigenicity, and nucleic acid integrity for diagnostic thyroid pathology using formalin substitute fixatives. *Thyroid.* 2009;19:1239–1248. [PubMed] [Google Scholar]
42. Monaco SE, Pantanowitz L, Khalbuss WE, et al. Cytomorphological and molecular genetic findings in pediatric thyroid fine-needle aspiration. *Cancer Cytopathol.* 2012;120:342–350. [PubMed] [Google Scholar]
43. Buryk MA, Monaco SE, Witchel SF, et al. Preoperative cytology with molecular analysis to help guide surgery for pediatric thyroid nodules. *Int J Pediatr Otorhinolaryngol.* 2013;77:1697–1700. [PubMed] [Google Scholar]
44. Suárez HG. Genetic alterations in human epithelial thyroid tumours. *Clin Endocrinol (Oxf)* 1998;48:531–546. [PubMed] [Google Scholar]
45. Kroll TG, Sarraf P, Pecciarini L, et al. PAX8-PPARgamma1 fusion oncogene in human thyroid carcinoma. *Science.* 2000;289:1357–1360. [published correction appears in *Science* 2000;289:1474] [PubMed] [Google Scholar]
46. Vecchio G, Santoro M. Oncogenes and thyroid cancer. *Clin Chem Lab Med.* 2000;38:113–116. [PubMed] [Google Scholar]

47. Schlinkert RT, van Heerden JA, Goellner JR, et al. Factors that predict malignant thyroid lesions when fine-needle aspiration is “suspicious for follicular neoplasm” Mayo Clin Proc. 1997;72:913–916. [PubMed] [Google Scholar]
48. Breuer C, Tuggle C, Solomon D, et al. Pediatric thyroid disease: When is surgery necessary, and who should be operating on our children? J Clin Res Pediatr Endocrinol. 2013;5(suppl 1):79–85. [PMC free article] [PubMed] [Google Scholar]
49. Welch Dinauer CA, Tuttle RM, Robie DK, et al. Extensive surgery improves recurrence-free survival for children and young patients with class I papillary thyroid carcinoma. J Pediatr Surg. 1999;34:1799–1804. [PubMed] [Google Scholar]
50. Kim K-E, Kim E-K, Yoon JH, et al. Preoperative prediction of central lymph node metastasis in thyroid papillary microcarcinoma using clinicopathologic and sonographic features. World J Surg. 2013;37:385–391. [PubMed] [Google Scholar]