



Removal of Complicated Gastric Balloon at Community Hospital

Saraswathi Lakkasani MD ¹, Rewanth Katamreddy MD ², Katie Roster M.S, DO ³,
Ummul Asfeen DO ⁴, Mehul Shah MD ⁵.

1,2,3,4,5. Saint Michael's Medical Center in affiliation with New York Medical College, Newark, New Jersey, USA.

Corresponding Author: Saraswathi Lakkasani, Saint Michael's Medical Center in affiliation with New York Medical College, Newark, New Jersey, USA.

Copy Right: © 2023 Saraswathi Lakkasani, This is an open access article distributed under the Creative Commons Attribution License, which permits unrestricted use, distribution, and reproduction in any medium, provided the original work is properly cited.

Received Date: April 04, 2023

Published Date: May 01, 2023

Introduction

A gastric balloon is one of the various minimally invasive procedures used for treating Obesity. They are commonly made up of silicon and are inflated with fluid or air. They work by promoting early satiety and therefore decrease calorie intake. They can be left in the lumen of the stomach for 6 to 12 months. However, it is associated with various complications either device related early complications or due to delayed removal. In this case report we report gastric outlet obstruction due to intragastric balloon.

Case Presentation

A 56-year-old female with Hypothyroidism, Hypertension is admitted with complaints of nausea, vomiting, and abdominal pain for 4 days. Patient had a Gastric Balloon that was placed endoscopically in Dominican Republic 5 months earlier and since then she lost 34 lbs. Patient abdominal pain is constant dull and non-radiating and improved by positional changes (turning to the left). Patient has not passed stools in the past 5 days which she attributes to no solid or liquid intake due to nausea. However, she is able to pass flatus. On examination, a palpable mobile mass is present in the epigastrium with minimal tenderness.

A CT scan of the abdomen was done which showed severely distended stomach with intragastric balloon causing obstruction and thickening of the distal esophagus suggestive of esophagitis (Image 1). The patient is subjected to endoscopy and the gastric balloon filled with Blue Gel like substance was punctured with Rat tooth forceps and all the fluid suctioned before removal (Image 2). Patient symptomatically improved and able to tolerate the diet.

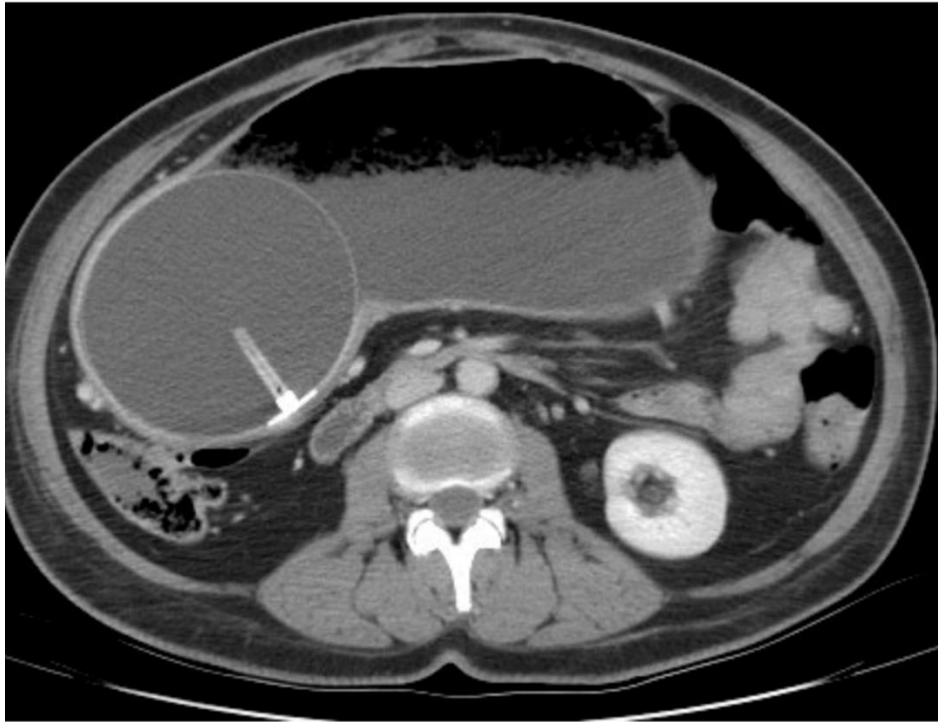


Image 01 CT Image showing intra gastric balloon causing obstruction

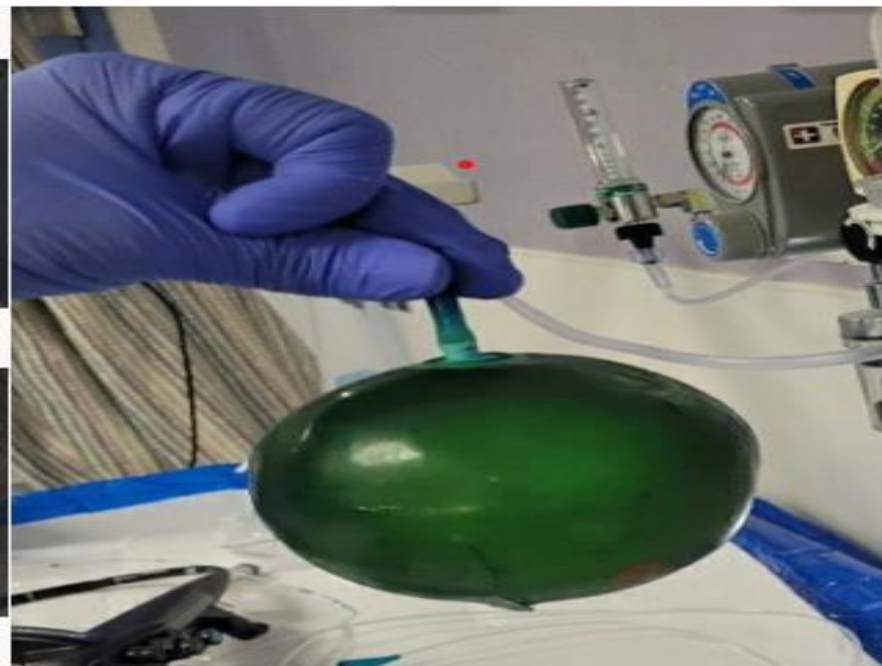


Image 2 showing the Gastric Balloon after removal

Discussion

There are 6 types of intragastric balloons available which are Orbera, ReShape Duo, Obalon, Heliosphere, Spatz, and Elipse approved by FDA or CE (European community). These devices have a capacity to expand between 400ml to 1000 ml with air filled balloons being able to accommodate higher volume. However, there are various complications which include nausea, vomiting, abdominal pain and discomfort, gastric erosions, gastric outlet obstruction, rarely lumbar radiculopathy or hollow viscous perforation. The reported complication rates are between 5.5% and 8%. It is imperative to identify these early to prevent catastrophic complications like perforation. Our patient was presented with gastric outlet obstruction with evidence of distended stomach. Our patient who had a device placed in another country is unsure of the particulars of the device. Therefore, it is important to be cognizant about the various devices available and endoscopic techniques used to remove such devices. We deflated the balloon before removing it with the toothed forceps.

References

1. Bazerbachi, F., Haffar, S., Sawas, T. et al. Fluid-Filled Versus Gas-Filled Intragastric Balloons as Obesity Interventions: A Network Meta-analysis of Randomized Trials. *OBES SURG* 28, 2617–2625 (2018). <https://doi.org/10.1007/s11695-018-3227-7>
2. Ourfalian R, Worsley C, El-Feky M, et al. Bariatric intragastric balloon therapy. Reference article, Radiopaedia.org (Accessed on 03 Apr 2023) <https://doi.org/10.53347/rID-47632>
3. Kool N, Müggler SA. *BMJ Case Rep* Published Online First: [please include Day Month Year]. doi:10.1136/bcr-2018- 224394
4. Bazerbachi, Fateh, Eric J. Vargas Valls, and Barham K. Abu Dayyeh. "Recent clinical results of endoscopic bariatric therapies as an obesity intervention." *Clinical endoscopy* 50.1 (2017): 42-50.
5. INatalia I. Khalaf, MD Anish Rawat, MDGreg Buehler, MD
Published:February 04, 2014DOI:<https://doi.org/10.1016/j.jemermed.2013.11.068>