



*Case Report*

---

**Bergmeister's Papilla : About A Case**

Dr Farah Benlkadri<sup>1</sup>, Dr Basma Ouidani<sup>1</sup>, Dr El Mehdi El Filali<sup>1</sup>, Dr Youssef bennouk<sup>1</sup>, Pr Hussein Ait lhaj<sup>1</sup>, Pr Mohamed Kriet<sup>1</sup>, Pr Fouad Elasri<sup>1</sup>

1. Military Hospital of Marrakech, Ophthalmology Department.

**\*Correspondence to:** Dr Farah Benlkadri, Military Hospital of Marrakech, Ophthalmology Department.

**Copyright**

© 2023 **Dr Farah Benlkadri**. This is an open access article distributed under the Creative Commons Attribution License, which permits unrestricted use, distribution, and reproduction in any medium, provided the original work is properly cited.

Received: 10 July 2023

Published: 01 August 2023

## Introduction

The Bergmeister's papilla is a rare congenital anomaly of the optic disc, characterized by the persistence of residues of the hyaloid artery on the optic disc, in the form of an epipapillary glial membrane, which can occlude the papilla or part of it, making it sometimes difficult to visualize.<sup>1</sup>

The residue of the anterior portion of the hyaloid artery on the posterior lens capsule is called Mittendorf's dot, while the posterior residue on the optic disc is called Bergmeister's papilla, and is usually made up of glial tissue.<sup>2</sup> In most cases, it is an occasional finding, which has no clinical impact. However, in the most severe forms it can be associated with cataracts, persistence of the primitive vitreous, microphthalmia, vitreous hemorrhages and sometimes tractional retinal detachment, due to contraction of the residual fibrovascular tissue.<sup>1</sup>

We report a case of a young patient who consults for an optical correction. The best corrected visual acuity was 10/10 in both eyes. Examination of the ocular fundus revealed, on the inferior portion of the optic disc, there was a whitish area of vitreous thickening, residual from the fetal vascularization on the optic disc (Bergmeister's papilla) (Fig. 1).

An optical coherence tomography (SD-OCT), showed identifying a hyperreflective opacity as a cap on the left optic disc, remnant of fetal vasculature, with adjacent vitreo-retinal adhesion, that must be monitored (fig.2).

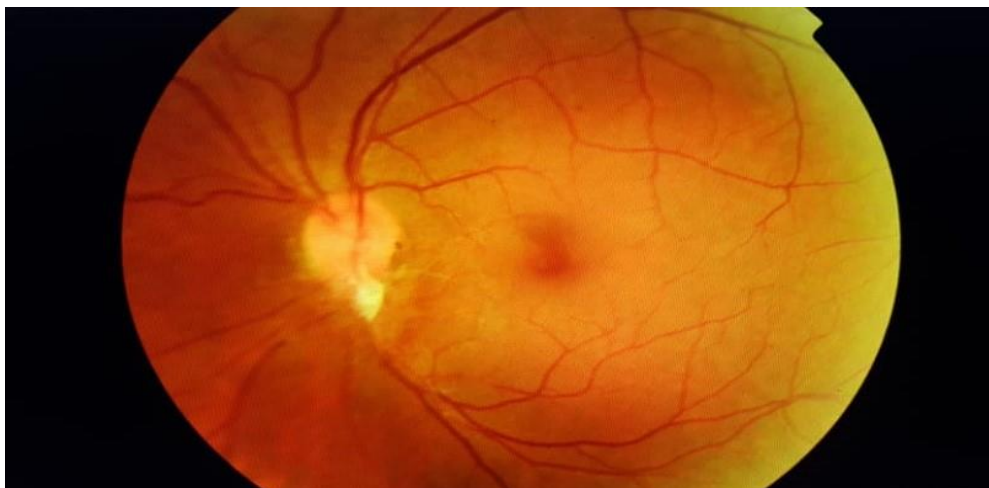


Figure1. Fundus photographs shows a Bergmeister's papilla

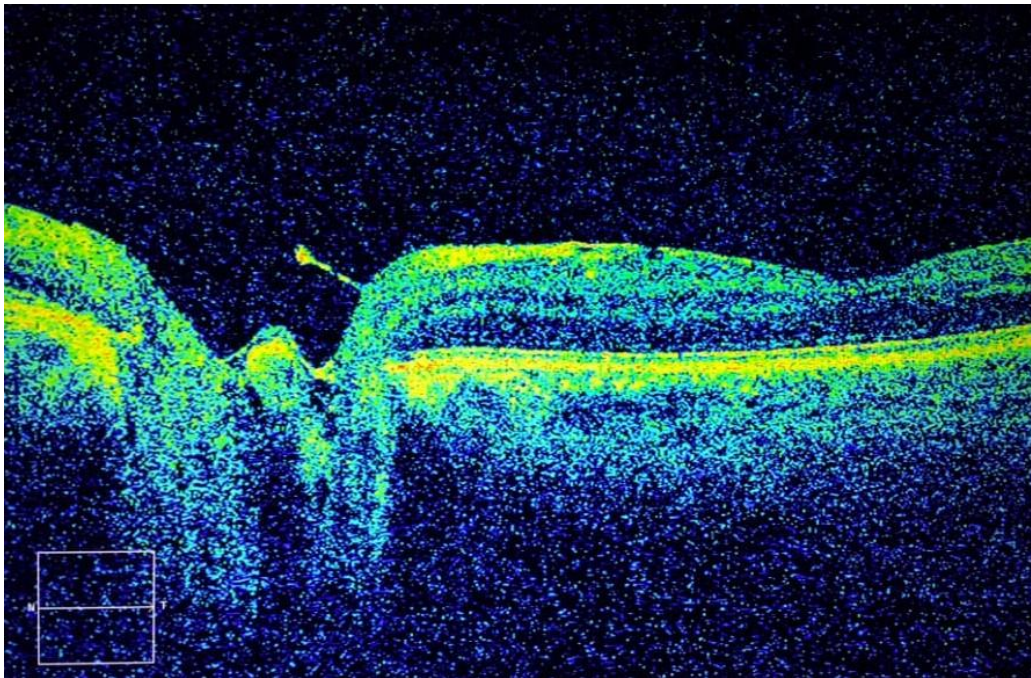


Figure2. Spectral domain optical coherence tomography of the optic nerve shows the presence of a hyperreflective opacity as a cap (Bergmeister's papilla).

## Reference

1. Petersen HP. Persistence of the Bergmeister papilla with glial overgrowth. *Acta Ophthalmol.* 2009;46(3):430-440.
2. Ramesh SV, Ray P, Ramesh PV, Ramesh MK, Rajasekaran R. There's more to a Bergmeister's papilla than which meets the eye. *J Clin Diagn Res.* 2021;15(5):NJ01-NJ02.

