



Sister Mary Joseph Nodule: A Rare Presentation of Metastatic Cervical Squamous Cell Carcinoma

Majumder A ^{*1}, Joshi P, Dhakane M A. ²

***Correspondence to:** Majumder A..

Copyright

© 2023 **Majumder A.** This is an open access article distributed under the Creative Commons Attribution License, which permits unrestricted use, distribution, and reproduction in any medium, provided the original work is properly cited.

Received: 15 September 2023

Published: 01 October 2023

Abstract

Sister Mary Joseph nodule refers to a palpable nodule bulging into the umbilicus as a result of metastasis of a malignant tumor in abdomino-pelvic area. It is a sign of advanced malignancy and signifies poor prognosis. We present the case of a 76-year-old lady a previously operated and treated case of carcinoma cervix, with only the physical findings of a palpable umbilical nodule. Further workup was consistent with metastatic squamous cell carcinoma of the cervix.

Key words: *Sister Mary Joseph nodule, metastasis, Malignancy, Cervix.*

Introduction

Sister Mary Joseph nodule is a metastatic umbilical nodule, seen in cases of certain advanced malignancies of abdomen and pelvic area. This term was coined by Sir Hamilton Bailey in 1949, in honor of Sister Mary Joseph Dempsey, Dr William J. Mayo's surgical assistant at St. Mary's Hospital (presently the Mayo Clinic) in Rochester as she noticed the frequent presence of a nodule/mass in the umbilical and periumbilical region in cases of advanced malignancies (1). This nodule signifies a poor prognosis and is an indicator of advanced malignant disease. Here we discuss the case of an elderly patient with a history of previously operated and treated case of carcinoma cervix, presenting with an umbilical nodule, which on further investigations proved out to be a metastatic squamous cell carcinoma.

Case Report

A 76 year old lady came to the OPD with complaints of weakness, anorexia and weight loss along with a recently developed reddish white umbilical nodule. She was diagnosed with cervical cancer 2 years back and was subsequently operated. On physical examination the nodule was primarily diagnosed as Sister Mary Joseph nodule. Later a fine needle aspiration cytology was performed and it revealed sheets of atypical squamous cells along with necroinflammatory debris, confirming it as metastatic squamous cell carcinoma.

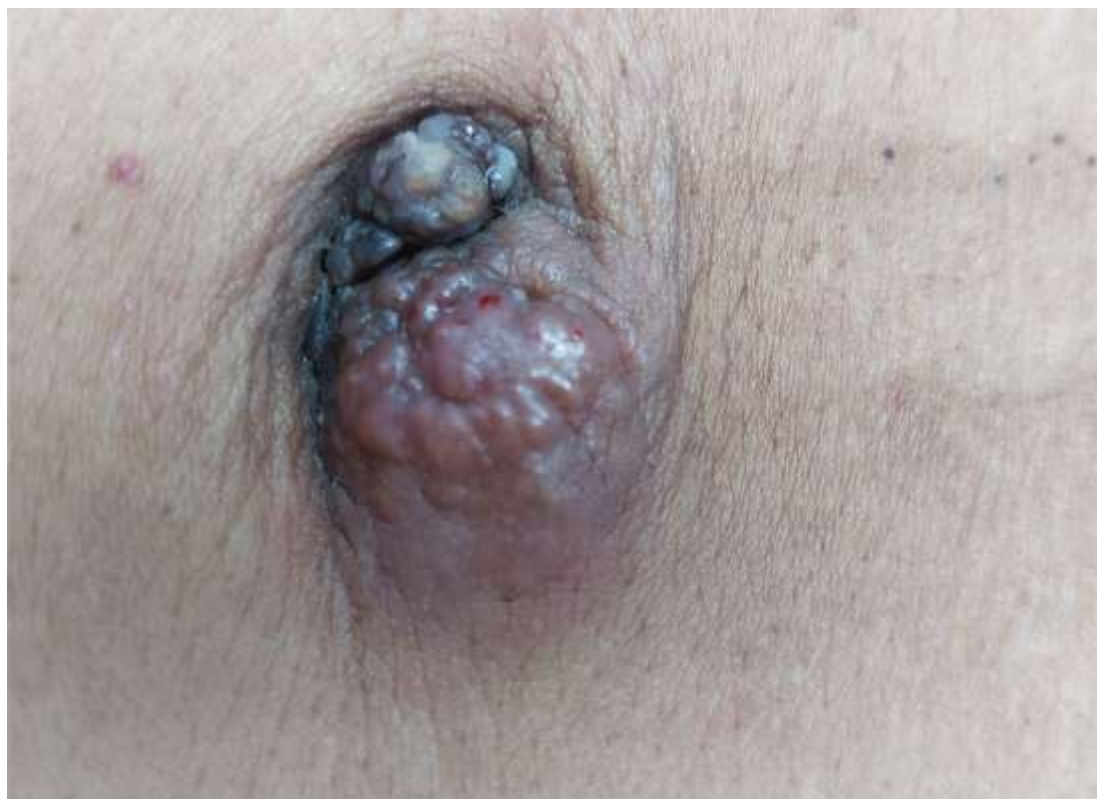

Figure: 1. Umbilical reddish white nodule with mild surface ulceration

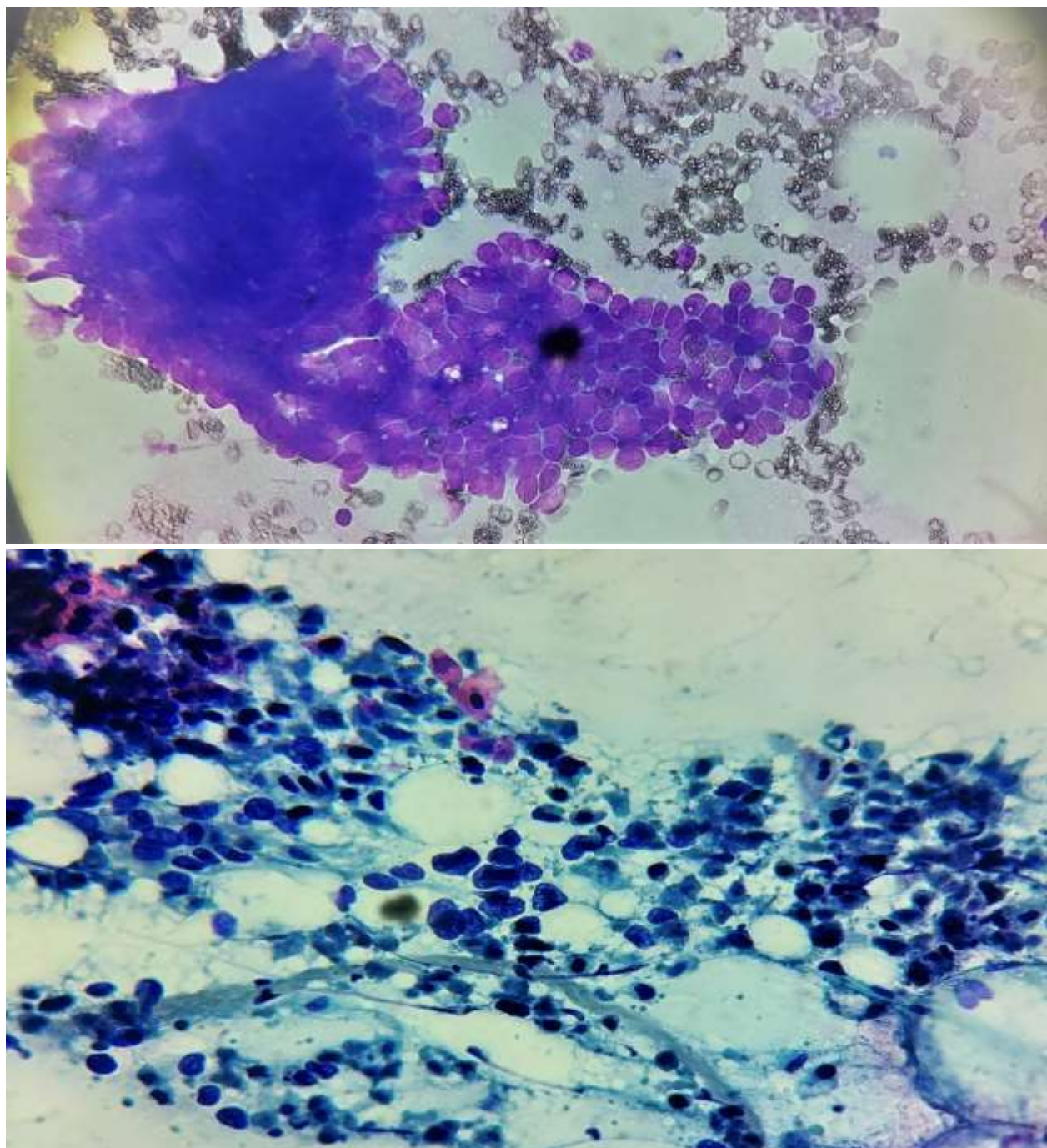


Figure 2 & 3. Fine needle aspiration cytology showing sheets of atypical squamous cells with necroinflammatory debris.

Discussion

Sister Mary Joseph nodule usually represents an adenocarcinoma of abdominopelvic region. The ovary, endometrium, and pancreatobiliary tree are most common primary sites in women, whereas the genitourinary tract, pancreato-biliary tree, and the gastrointestinal tract are the most common sites in men (2). It has been observed that women tend to present with umbilical nodule more than men. Moreover, umbilical nodules can arise as benign cutaneous tumors too. Keloid, umbilical hernia, urachus, sebaceous cyst, endometriosis, granuloma, fibroepithelial papilloma, dermatofibroma, fibroma, , urachal duct cyst, seborrheic keratosis, foreign body, myxoma, omphalitis, polyp, and abscess are the common differential diagnosis (3).

The nodule usually presents as firm, indurated swelling with superficial ulceration and may have serous, mucinous, purulent or bloody discharge. The nodule appears as white, bluish violet and brownish red and is often pruritic, typically less than 5 cm in diameter but occasionally enlarges to form a protruding mass. Patients with Sister Mary Joseph nodule present with a number of clinical symptoms consistent with intra-abdominal cancer including epigastric pain, abdominal distension, weight loss, nausea, ascites and bleeding per rectum (4). The occurrence of Sister Mary Joseph nodule is uncommon and as a first sign of malignancy is rare.

CT Scan (abdomen and chest) and Fine Needle Aspiration Cytology (FNAC) of the tumors are invaluable in the diagnosis of Sister Mary Joseph nodule and help to exclude a primary benign umbilical neoplasm.

In 14-33% of cases, umbilical metastases lead to the diagnosis of previously occult neoplasms (5). In 40% of patients with a known neoplasm the nodule was an early sign of relapse (6)

Spread of metastatic carcinoma to the umbilical region has been hypothesized to occur by either contiguous spread of peritoneal cancer, hematogenous spread through arterial and venous systems or lymphatic spread (mainly pancreatic carcinoma) with extension along ligaments of embryonic origin (round ligament of liver, urachus, vitello intestinal duct remnant and the obliterated vitelline artery).

Specifically, the umbilical region is connected by the lymphatic system to the axillary, inguinal, and paraaortic lymph nodes and exhibits a rich arterial supply via the inferior epigastric and deep circumflex iliac branches of the external iliac artery and the superior epigastric branch of the internal mammary artery. Along with these there are the several venous anastomotic branches from the internal mammary vein, the superficial epigastric vein, and the portal system of the liver. The presence of a Sister Mary Joseph nodule

signifies advanced metastatic malignancy and a poor prognosis with a survival time of 10 months (range 2-17 months) and inoperability. Treatment of established Sister Mary Joseph nodule is mostly palliative as wide excision, surgery and radiotherapy have all proved ineffective.

Conclusion

Once diagnosed, the sister Mary Joseph nodule signifies advanced malignancy and there is only scope of minimal palliative care. Nevertheless, a Sister Mary Joseph nodule is a time tested, honored clinical sign emphasizing the importance of a careful physical examination of the abdomen. It still remains an interesting and useful diagnostic tool in modern medicine.

References

1. Windsor LL. Dempsey, Sister Mary Joseph. In: *Women in Medicine: an Encyclopedia*. Santa Barbara, CA: ABC-CLIO, 2002: 58-59. <http://books.google.com/books?id¼QtZtkf35CF0C&lpg¼PP1&pg¼PP1#v¼onepage&q&f¼false>. Accessed October 15, 2014.
2. Chalya PL, Mabula JB, Rambau PF, McHembe MD. Sister Mary Joseph's nodule at a university teaching hospital in northwestern Tanzania: a retrospective review of 34 cases. *World J Surg Oncol*. 2013 Jul 5;11:151.
3. Coll DM, Meyer JM, Mader M, Smith RC. Imaging appearances of Sister Mary Joseph nodule. *Br J Radiol*. 1999 Dec;72(864): 1230-1233
4. Urbano FL. Sister Joseph's nodule. *Hospital Physician* 2001;37(5):33-5, 44.
5. Majumdar B, Wiskind AK, Croft BN, Dudley AG. The Sister (Mary) Joseph nodule: its significance in gynecology. *Gynecol Oncol* 1991;40(2):152-9.
6. Srinivasan R, Ray R, Nijhawan R. Metastatic cutaneous and subcutaneous deposits from internal carcinoma. An analysis of cases diagnosed by fine needle aspiration. *Acta Cytol* 1993;37(6):894-8.

