



Subungual Resection of the Glomus Tumor

Muhammad Azfar *¹, Tariq Yahia Alatta ², Omer Adil Awadelkarim ³, Qamar Jaleel Akhtar ⁴

1. Orthopedic Specialist Dr Sulaiman AlHabib Suwaidi Hospital Riyadh.
- 2,3. Resident Orthopedic Dr Sulaiman AlHabib Suwaidi Hospital Riyadh.
4. Consultant orthopedic Surgeon Dr Sulaiman AlHabib Suwaidi Hospital Riyadh.

Corresponding Author: Muhammad Azfar Khanzada, Dr Sulaiman Al Habib Suwaidi Hospital Riyadh KSA.

Copy Right: © 2023 Muhammad Azfar Khanzada, This is an open access article distributed under the Creative Commons Attribution License, which permits unrestricted use, distribution, and reproduction in any medium, provided the original work is properly cited.

Received Date: February 22, 2023

Published Date: March 01, 2023

Abstract

Background: *Glomus tumors are rare benign hamartomas that arise from the glomus body and are most common in the digits' subungual region. These tumors are generally misdiagnosed or diagnosed very late even taking several years before they get diagnosed correctly.*

Case presentation: *In this case, we report a 66- year old male who presented with a history of spontaneous pain and tenderness under the nail of the left ring finger for a few months. The treatment was subungual resection of the glomus tumor. An incision was made to the nail bed accompanied by a glomus tumor resection followed by patching of the nail bed over the bone indentation. After the procedure, the patient's previously injured finger was functionally restored.*

Keywords: *Fingers, Glomus tumors, Magnetic resonance imaging, Pain*

Introduction

Glomus tumor is a rare type of benign tumor derived from structures known as glomus bodies and occurs frequently in the hand's subungual region. These glomus bodies are neuromyo-arterial structures that significantly control the local blood flow and thermoregulation. (1) Despite being present throughout the body's dermis, they are more prevalent in the hands and feet. Glomus tumors make up 2% of all hand tumors while 25% to 75% of these take place in the subungual region. These tumors occur in 1.8 new patients per million. Glomus tumors have been reported in patients of all ages but they typically affect patients in their middle years. (1, 2)

These tumors are generally misdiagnosed or diagnosed very late; it typically takes several years before a correct diagnosis is made. Patients typically present with distinguishing features of tumor including a firm, subungual nodule in the distal phalanx with moderate pain to severe spontaneous paroxysmal pain, point or localized tenderness, and sensitivity to cold. While their diagnosis typically relies on a patient's precise history and a physical examination. Moreover, for further precise diagnoses, additional imaging tests can be carried out and MRI can still be helpful for cases with less distinct clinical signs and symptoms. (2, 3, 4)

Complete surgical excision is the only known curative technique that can be accomplished because of the small tumor mass. However, the subungual area inherently poses difficulties for excision. Improper surgery may result in nail deformity and/or a local recurrence. (5) Here in this report, we describe a case of an elderly male who presented with a solitary subungual glomus tumor that was successfully excised surgically.

Case Report

A male patient of 66 years presented to the orthopedic outpatient department at Dr. Sulaiman AL-Habib hospital Suwaidi KSA, with a history of spontaneous pain under the nail of the left ring finger for a few months. He reported having pain in his left ring finger several times a day. The pain in his finger aggravates even with a slight touch, contact, or compression. He also has difficulty performing daily routine work. There was no history of trauma, extremity injury, systemic complaints, or the patient's description of night pain.

On examination: An elderly male, with a discolored lesion under the nail of the left ring finger. (Figure 1) Point tenderness was positive while local temperature hypersensitivity was not present. Based on history and clinical examination it was suspected that it could be a subungual hemangioma, a neuroma, or some bony lesion.

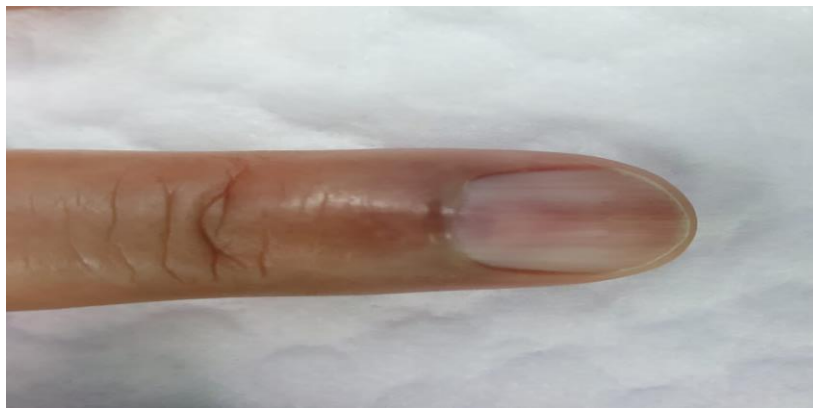

Figure 1: Preoperative clinical presentation photograph of the patient's affected ring finger showing the faint bluish discoloration visible under the nail.

Radiographic (X-ray) findings revealed a small erosion in the anterior part of the ring finger distal phalanx base. Soft tissue swelling was observed but no definite fracture or dislocation was seen. (Figure 2) While on MRI: a well-defined hyper-intense soft tissue lesion was found at the subungual region of the fourth finger, dorsal to the distal phalanx, causing scalloping of the cortex, the lesion measures 0.5x0.7 cm. This is highly suspicious for a Glomus tumor. (Figure 3).

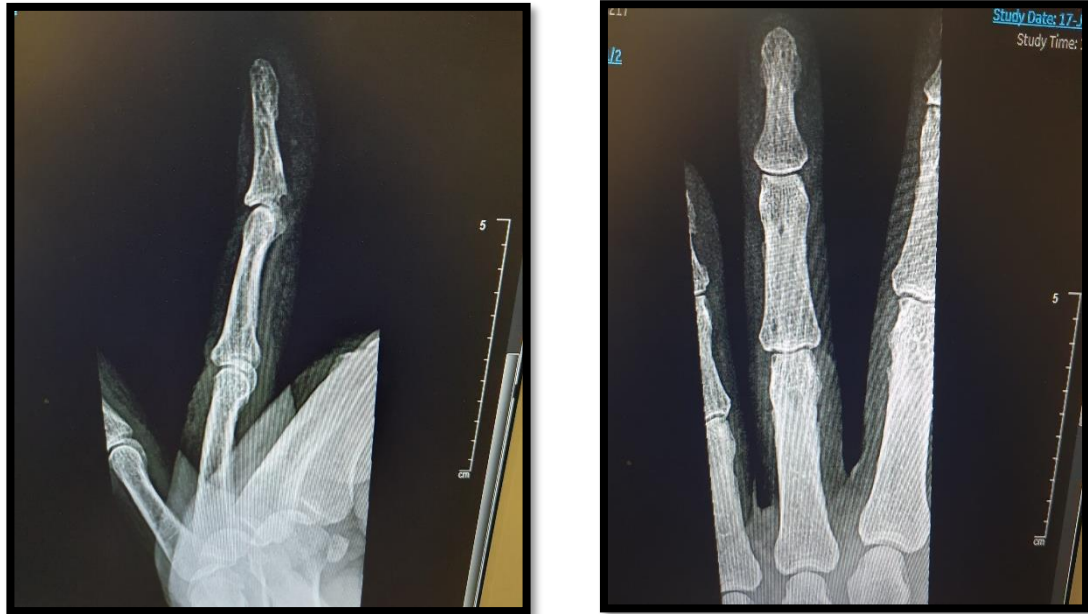

Figure 2: Pre-operative radiographic presentation (X-ray) findings of patient's ring finger

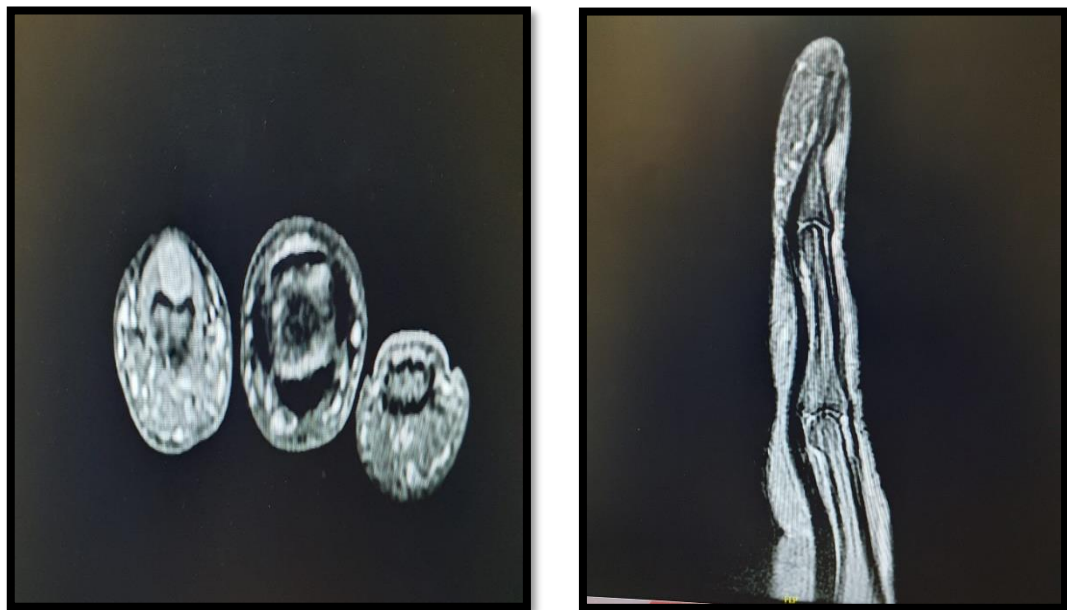


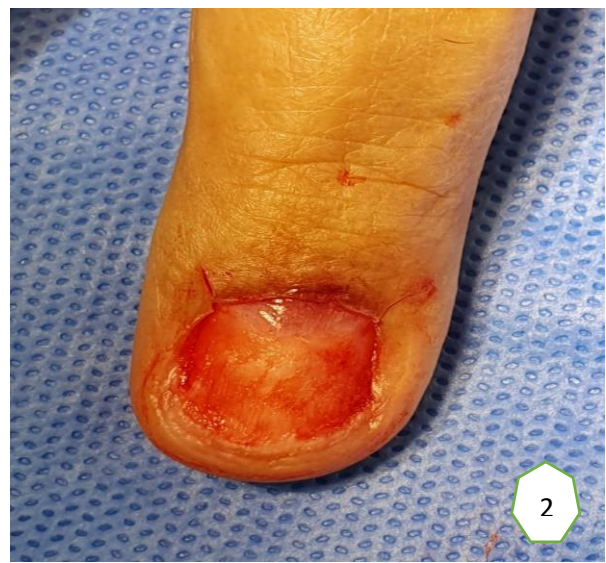Figure 3: Pre-operative radiographic presentation (MRI) findings of patient's ring finger

Pre-operative investigations were unremarkable in this case. Consent was obtained for the surgery from the patient after explaining the procedure details. Moreover, permission for publishing photographs was also obtained. The patient planned for subungual resection of the glomus tumor under general anesthesia. During the procedure, two small incisions at the side of the nails for nail removal. Then a small incision in the nail bed of the left ring finger was given. The nail bed was elevated off and retracted for exposure to the underlying glomus tumor. Later the tumor was resected and the nail bed was patched over the bone indentation using the absorbable suture. (Figure 4) The outcome of the surgical excision was excellent and no complications or complaints of pain have reported during the patient 8-month follow-up.

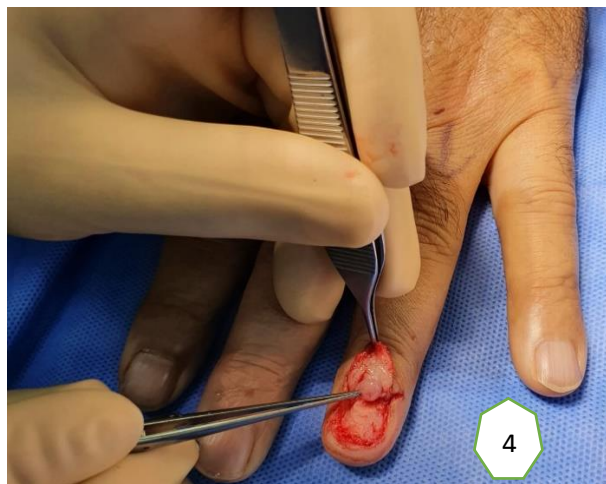
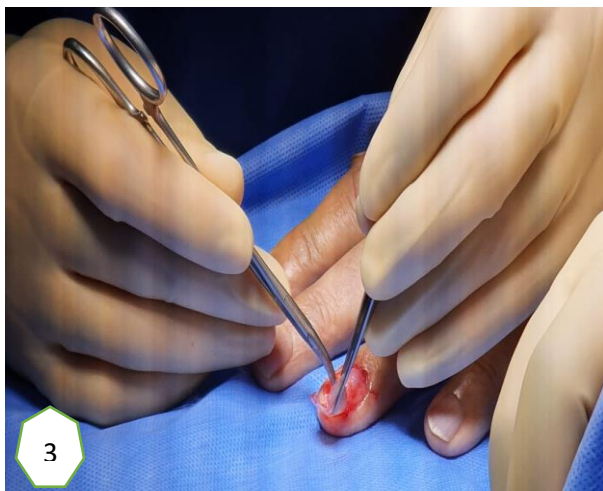
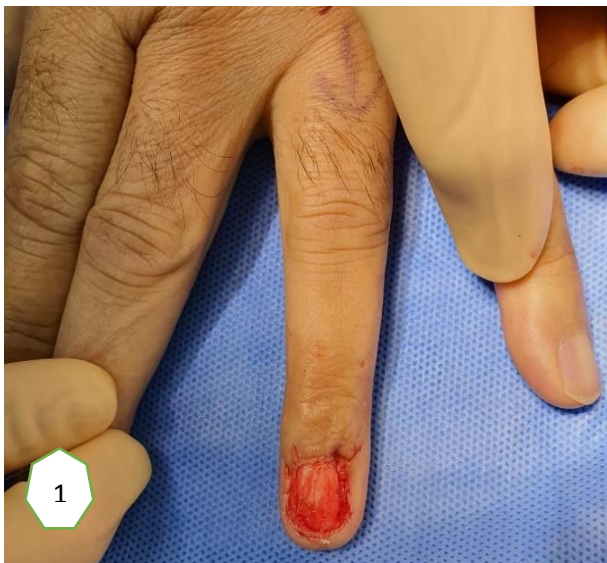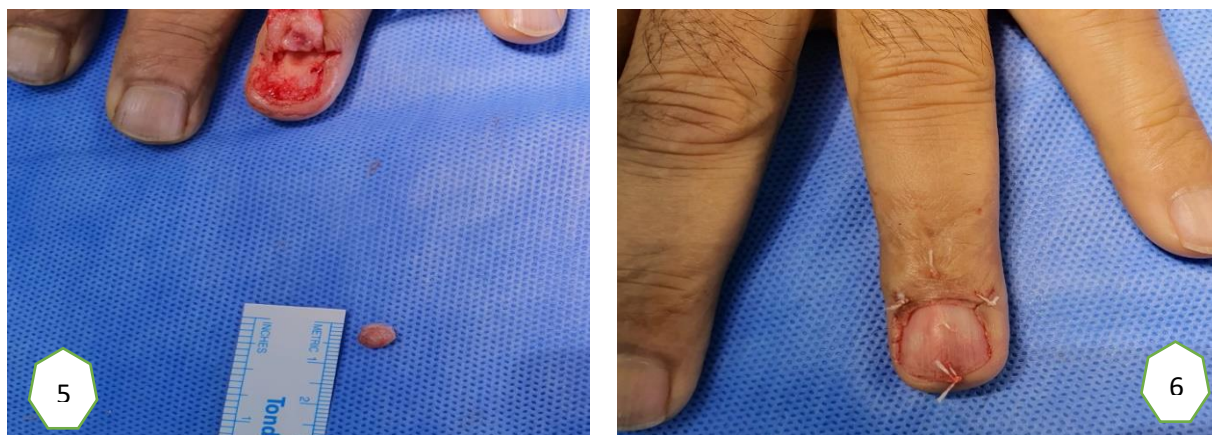




Figure 4: Step-wise subungual surgical resection of the glomus tumor (1 & 2) Two small incisions were made for uprooting nail. (3) Small incision made to the nail bed. (4) The underlying periosteal and nail matrix are raised as a proximally based flap, exposing the underlying tumor. (5) Tumor was removed (excised tumor is pointed with an arrow). (6) Uprooted nail is repaired and patched over the bone indentation using the absorbable suture.

Discussion

According to our experiences, a thorough physical examination and medical history may be sufficient for making a diagnosis. However, early diagnosis and treatment of the disease depend on an understanding of the rare disease among both patients and doctors. Delay in diagnosis may result in complications. (5, 6) Diagnosis of the glomus tumor should be emphasized if the typical triad of symptoms is present. However, the diagnosis on clinical examination becomes challenging when the patient exhibits hazy symptoms or the objective findings are ambiguous. (6, 7) In such a case, medical imaging or a radiological examination might be helpful to provide us with helpful clues in detecting and making a precise diagnosis of the glomus tumor. Apart from the x-ray findings, some authors also reported that ultrasound can be used for detecting this lesion but its accuracy is highly operator-dependent. (8) On the other hand MRI more appropriate and suitable method for detecting and demonstrating the tumor directly. In the present case, the glomus tumor was detected on MRI.

Complete surgical excision is the only effective treatment for subungual glomus tumors of the finger. Many other surgical techniques for the excision of this tumor have been reported. The standard approach is a direct transungual excision. (8, 9) Recurrence rates of these tumors vary depending on the technique used and the extent of the tumor's excision. Following complete resection, symptoms typically disappear for patients utterly. While incomplete excision results in the risk of recurrence.

Symptoms that appear days to weeks after surgical excision may be due to incomplete excision, whereas symptoms that appear 2 to 3 years after surgery may indicate multiple tumors.

In this case, we performed the subungual resection of the glomus tumor under general anesthesia. During the procedure, the nail was uprooted following two small incisions at the lateral side of the nail and a small incision was given at the nail bed of the left ring finger. The tumor was resected after retracting the nail bed and skin and the nail bed was patched over the bone indentation using the absorbable suture. The outcome was excellent and no pain or other complications were reported after 8 months of surgery.

Conclusion

We conclude this report will create awareness about early diagnosis of subungual Glomus tumor and to avoid unnecessary delay in its proper management.

Reference

1. Kim YJ, Kim DH, Park JS, Baek JH, Kim KJ, Lee JH. Factors affecting surgical outcomes of digital glomus tumour: a multicentre study. *Journal of Hand Surgery (European Volume)*. 2018 Jul;43(6):652-8.
2. Nambi GI, Varanambigai TK. Excision of subungual glomus tumor by subungual approach: A useful yet underutilized technique. *Journal of Cutaneous and Aesthetic Surgery*. 2019 Jul;12(3):187.
3. Senhaji G, Gallouj S, El Jouari O, Lamouaffaq A, Rimani M, Mernissi FZ. Rare tumor in unusual location—glomus tumor of the finger pulp (clinical and dermoscopic features): a case report. *Journal of medical case reports*. 2018 Dec; 12(1):1-5.
4. Chou T, Pan SC, Shieh SJ, Lee JW, Chiu HY, Ho CL. Glomus tumor: twenty-year experience and literature review. *Annals of plastic surgery*. 2016 Mar 1;76:S35-40.
5. Madhar M, Bouslous J, Saidi H, Fikry T, Schuind F. Which approach is best for subungual glomus tumors? Transungual with microsurgical dissection of the nail bed or periungual? *Chir Main*. 2015;34:39–43
6. Bordianu A, Zamfirescu D. The hidden cause of chronic finger pain: Glomus Tumor—A Case Report. *Journal of Medicine and Life*. 2019 Jan;12(1):30.

7. Lu H, Chen LF, Chen Q. Rupture of a subungual glomus tumor of the finger. BMC cancer. 2018 Dec;18(1):1-5.
8. Cha SM, Shin HD, Park YC. Surgical resection of occult subungual glomus tumors: Cold sensitivity and sonographic findings. Annals of Plastic Surgery. 2018 Oct 1;81(4):411-5.
9. Thakur BK, Verma S, Jitani A. Subungual glomus tumour excision with transungual approach with partial proximal nail avulsion. Journal of cutaneous and aesthetic surgery. 2016 Jul;9(3):207.