



Proliferative Diabetic Retinopathy- a Case Review

Dr. Mohammed Atif Makdum ¹, Dr Sarah Singh ², Dr Firdaus Sukhi ^{*3}

1. *Department of Ophthalmology, University hospital Sharjah, UAE.*

2. *UNISR, Milan Italy.*

3. *Department ophthalmology, SKMC Ajman, UAE.*

***Correspondence to:** Dr Firdaus Sukhi, Department ophthalmology, SKMC Ajman, UAE.

Copyright

© 2026 **Dr Firdaus Sukhi** This is an open access article distributed under the Creative Commons Attribution License, which permits unrestricted use, distribution, and reproduction in any medium, provided the original work is properly cited.

Received: 16 December 2025

Published: 01 January 2026

DOI: <https://doi.org/10.5281/zenodo.18086558>

Abstract

The most common cause of severe preventable blindness in diabetics in today's world is proliferative diabetic retinopathy. It is one of the major cause of disability in working adults in the world. The common causes of visual loss due to the complications are vitreous haemorrhage, tractional retinal detachment and neovascular glaucoma. There are several treatment options including laser pan retinal photocoagulation, anti-vascular endothelial growth factor injection and surgeries like vitrectomy.

The case of 30 years old Arab woman with proliferative diabetic retinopathy and its complications are mentioned along with the management

Introduction

As per WHO -2019 report DR is one of the major cause of blindness and leading cause of blindness in working age people. As per Wisconsin epidemiologic study of DR 42 percent of type 1 diabetics progressed to severe PDR in 25 years. With complications like neovascularisations and retinal and vitreous haemorrhages. There are 2 types of diabetic retinopathy. Non proliferative categorised by retinal vessels abnormalities, leakage of lipids and accumulation of fluid in the macula (macular oedema). Proliferative diabetic retinopathy is diagnosed with new vessels, bleeding retinal and vitreous and tractional retinal detachment. The severe devastating end stage as neovascular glaucoma is also a difficult entity to manage. We present an interesting case of proliferative diabetic retinopathy and its management in the article.

Case Presentation

A 30 years old alert active arab female reported in the retina clinic for follow up for her retina status. She has visited only once for eye check during past 10 years. She was treated for laser photocoagulation in her left eye 6 months back diagnosed as proliferative diabetic retinopathy. She was advised and counselled for follow ups as her retina was stable and treated. She was informed that her other eye was pretty good and needed only follow ups in the retina clinic. She had no particular visual symptoms. The patient's medical history was significant as type 1 childhood onset T1 DM since 16 years. She was on insulin and her recent HbA1c was 10 her HbA1c levels have been raised more than 12 in the past.

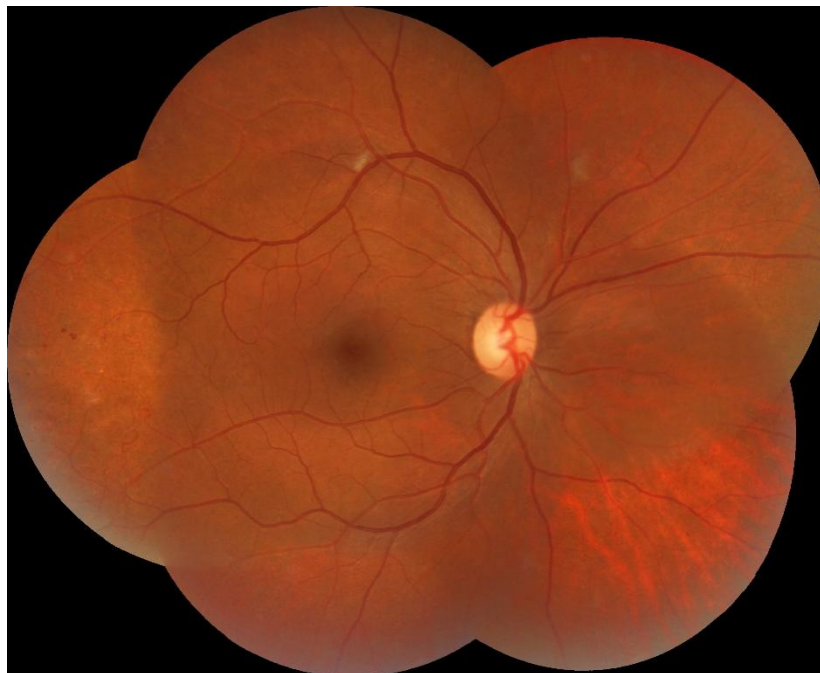

Figure 1

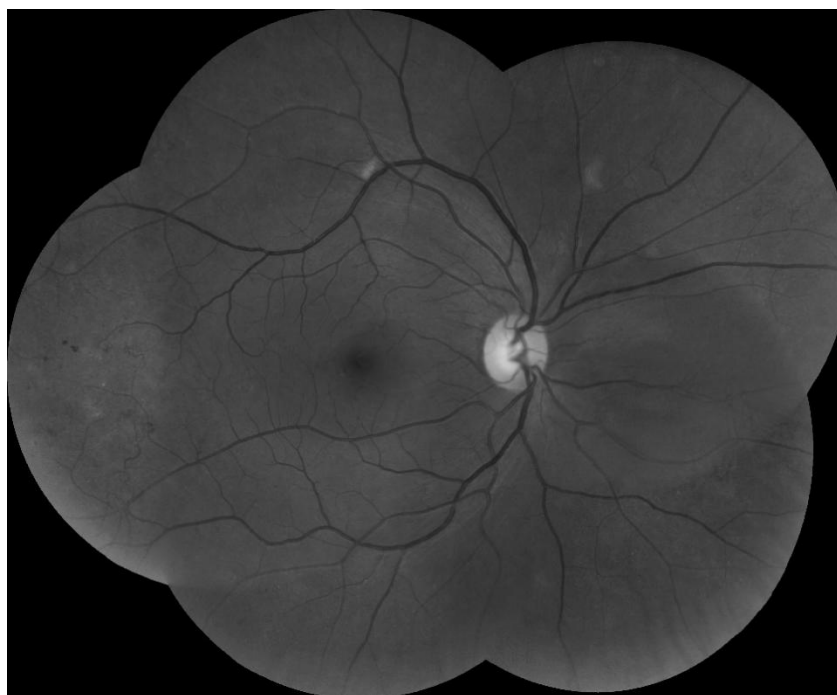


Figure 2

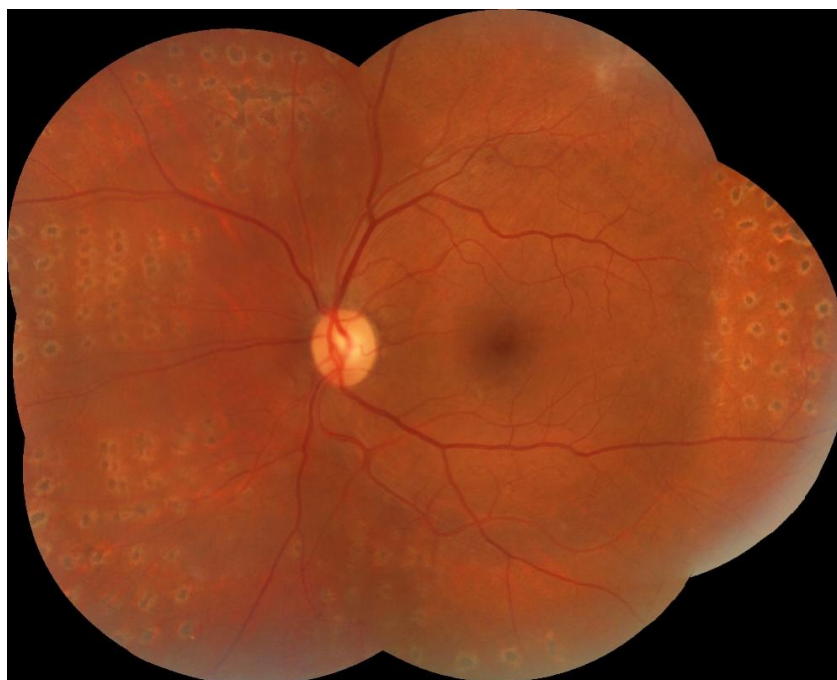

Figure 3

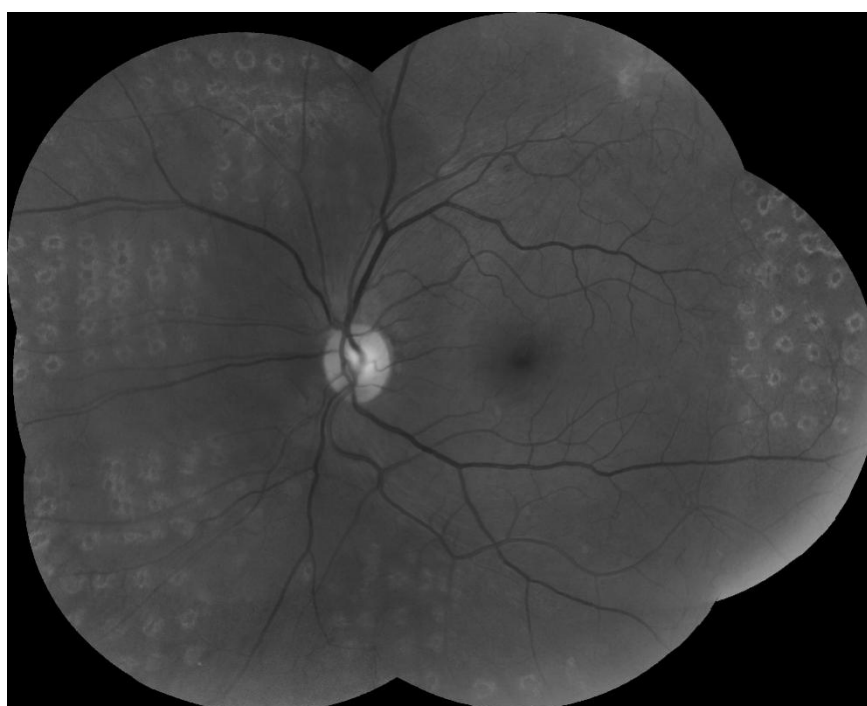

Figure 4

She was diagnosed as premature ovarian failure and PCOS in the past 3 years and history of amenorrhea since past 3 years.

Her medications included Insulin 18 units bid Semaglutide 0.5 And statins 10 mg due to her altered lipid profile.

On examination, his best-corrected visual acuity was 20/20 in both the eyes Field testing as confrontation was present all quadrants Normal set eyes with normal ocular movements Her pupils were central circular reacting to direct and consensual light testing Her Anterior segment examination were unremarkable with clear iris and no iris vascularisation on slit lamp.

On dilatation with mydriatics tropic amide 1 percent the posterior segment examination was as follows.

Normal optic nerve heads both eyes. Her left eye showed patterned regular laser shots scattered all over posterior pole There was an island of fibro vascular flat lesion super temporally almost 5-6 dd from the disc. There were large bare areas of laser in the periphery Right eye was not lasered and showed few microaneurysms and retinal vascular changes as looping beading and few flat IRMA Color free images were obtained the same day which revealed new vessels in both eyes There was no vitreous haemorrhage or tractional retinal detachment in both eyes Optical coherence tomography was done swept source machine and revealed dry macula with no oedema or leak or epiretinal membrane formation.

The patient was diagnosed as proliferative diabetic retinopathy both eyes and posted for fundus fluorescein angiography both eyes. Fluorescein angiography (FA) was performed. In the midphase in the right eye there was hyper fluorescence in the mid phase and profuse leakage in the late phase all over the posterior pole from the undetected new vessels and no perfusion in the periphery suggesting a vast area of capillary non perfusion The left eye which was lasered showed hyper fluorescence in mid phase from the disc and from multiple new vessels all over. The late phase confirmed the leakage from all the new vessels especially in the temporal retina There were large unlasered areas in the left eye with lot of capillary dropouts in the periphery.

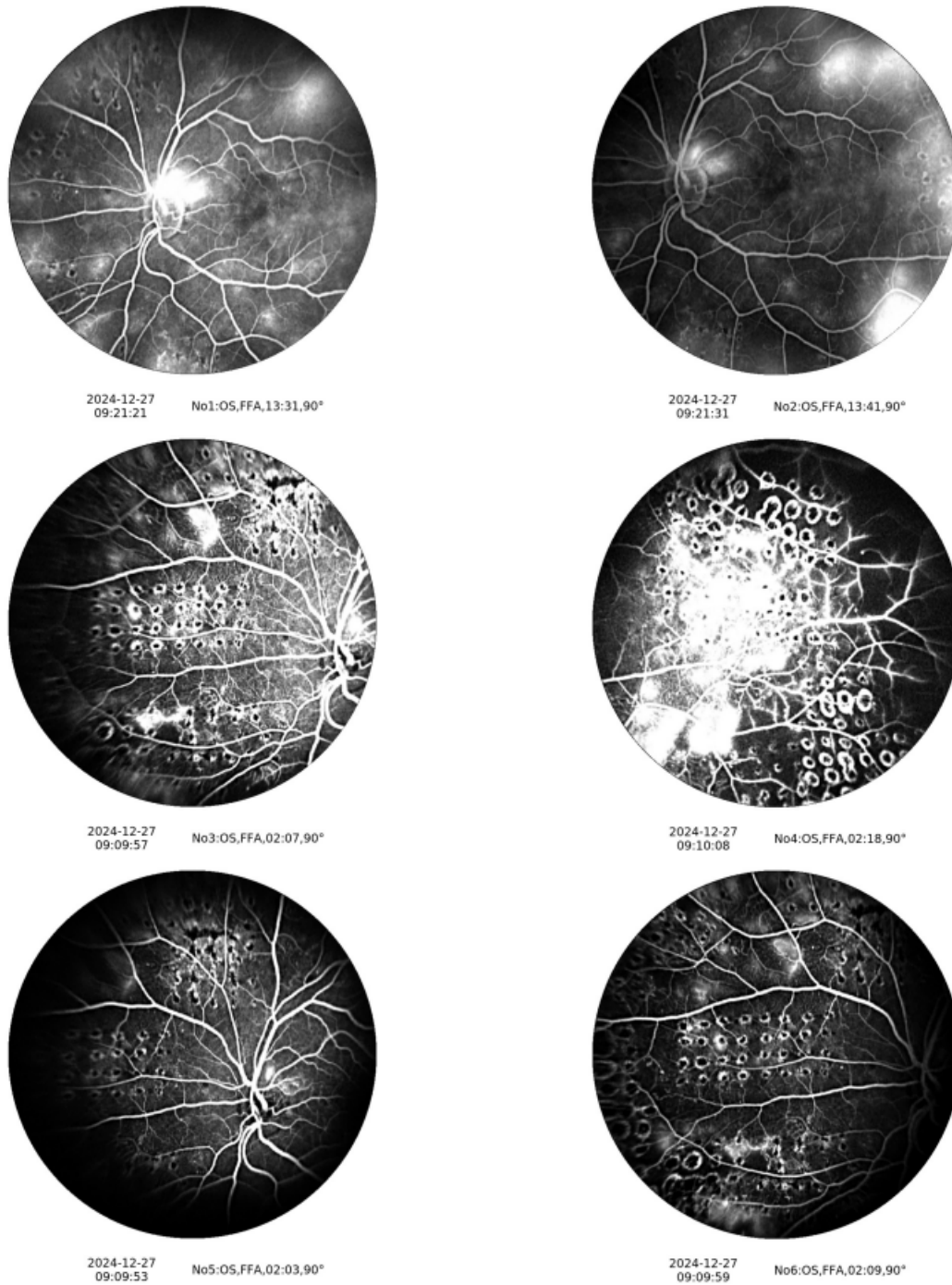


Figure 5

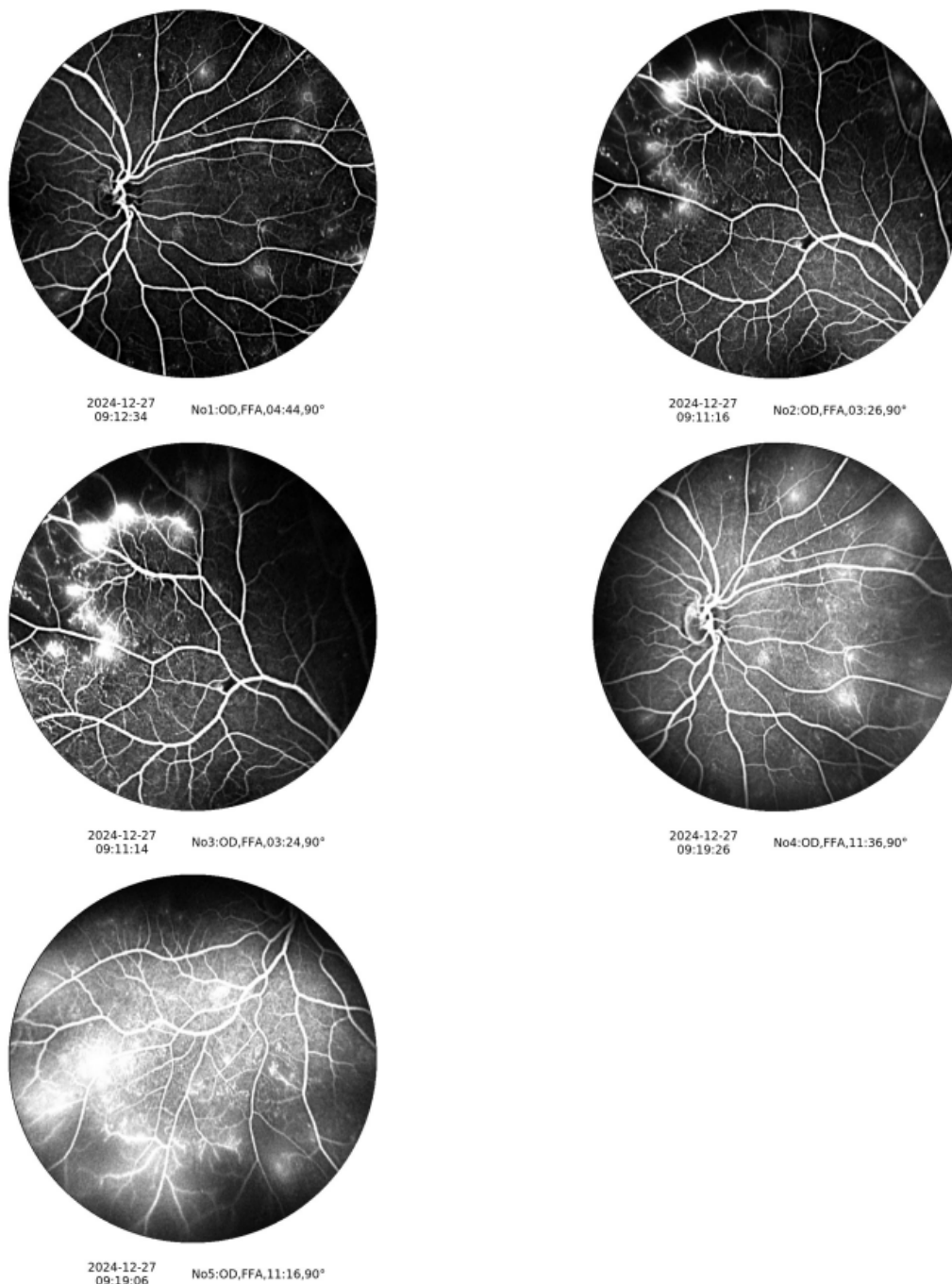


Figure 6

The treatment plan for the patient's PDR consisted of laser supplication to completely cover the bare areas in the left eye and initiate laser in the right eye .Due to her irregular visits history and poor metabolic control she was deferred intravitreal anti VEGF injections and counselled for laser PRP both eyes .

The diabteologist was consulted for regulated control of HBA1C

Discussion

Etilogy

Poorly controlled diabetes, elevated hba1c and chronic hyperglycaemia cause progression of NPDR to PDR by combination of one or all mechanism mentioned below

1. Hyperglycemia induced microangopathy and pericyte loss.
2. Retinal inflammation induced by increased secretion of TNF- α , IL-6, MCP-1 and VEGF and late involvement of Müller cells and astrocytes is also associated with the amplification of inflammation responses by producing proinflammatory cytokines.
3. Retinal neurodegeneration is an early event during the progression of DR. Apoptosis of retinal neurons can be observed in diabetic AND Upregulation of pro-apoptotic molecules such as cleaved caspase-3, Bax and Fas has been detected causing mitochondrial dysfunction in progressed cases.

The symptoms of PDR are often unnoticed until retinal vessels leak and cause visual loss or floaters If associated with macular oedema patient might complain of blurring of vision.

Diagnostic Testing

Fundus photography is an extremely useful for to detect diagnose and monitor the retinopathy. Black and white images sometimes capture the retinal vessels abnormalities which are missed on colour photography.

Fluorescein Angiography Is an invasive yet an indispensable aid in locating areas of retinal ischemia, differentiating IRMA and collaterals from NV, and detecting hidden or subclinical newvssles.

Optical Coherence Tomography (OCT) is needed to detect, classify and monitor the macular oedema. The response to treatment by anti vegf is best reported with OCT.

Optical Coherence Tomography Angiography (OCT-A) is extremely helpful in patient allergic to fluorescein dye and in patients with kidney failure.

B-scan ultrasonography is helpful to evaluate the posterior segment when the media is hazy secondary to VH and/or TRD.

Treatment

Good regulated control of diabetes mellitus and co morbidities, healthy lifestyle along with the treatment provided in the eye clinic should be initiated immediately. Counselling regarding systemic control, regular visits and frequent eye check-ups should be done promptly. Urgent treatment and guidelines, multiple treatment sessions, combinations of treatment modalities should be explained and discusses with the patient and family. Pan retinal photocoagulation is an important treatment of PDR.

Retinal laser in few or more session involves coagulation of retina leading to reduce oxygen demand and regression of new vessels of retina . Risks of PRP include worsening of visual acuity, loss of peripheral vision, DME, vascular occlusion, choroidal detachment, exudative retinal detachment, and formation of choroidal neovascular membrane.

The addition of intravitreal anti-VEGF therapy or intravitreal steroid therapy can aid in regressing active neovascularization, reducing preretinal and vitreous haemorrhages, and may lead to conservation of the visual potential compared to PRP alone.

Surgical options like vitrectomy and endolaser photocoagulation are suitable for patients having non resolving vitreous haemorrhage, dense premacular haemorrhage and tractional retinal detachment. Prompt surgery is needed to prevent severe visual loss in such cases.

Control of Systemic Disease

Good regulated control of diabetes mellitus and co morbidities, healthy lifestyle along with the treatment provided in the eye clinic should be initiated immediately. Counselling regarding systemic control, regular visits and frequent eye check-ups should be done promptly. Urgent treatment and guidelines, multiple treatment sessions, combinations of treatment modalities should be explained and discusses with the patient and family Collaboration of patient care between eyecare providers, primary care, and endocrinology are key to PDR prevention and management.

Visual Outcome

PRP when greatly extensive can result in restricted visual fields, nyctalopia and poor light and dark adaptation, which can potentially cause difficulty with driving, orientation and mobility. Referral for vision rehabilitation may be greatly beneficial in these instances and should be initiated as soon as possible after extensive therapy to aid in adaptation to decreased visual efficiency. Occupational therapy may involve instruction in orientation and mobility, activities of daily living, occupational training, insulin management and self-care.

Conclusion

Proliferative diabetic retinopathy is a sight threatening disease and is a leading cause of vision loss in the US. Regular dilated fundus examinations in conjunction with the judicious use of diagnostic imaging can lead to prompt diagnosis and treatment. Improved control of diabetes mellitus and systemic comorbidities along with anti-VEGF and/or PRP, can prevent long term vision impairing complications such as NVG, VH, and TRD can be prevented.



Medtronic