



MAR Oncology and Hematology (2026) 6:1

Case Report

Lower Lip Squamous Cell Carcinoma: Surgical Management and Reconstruction Using Bilateral Bernard-Webster Flap

Nikita Chandak^{1*}, Hemkant Verma², Sparsh Sharma¹, Akhilesh Dalal²

1. Department of General Surgery
2. Department of Surgical Oncology

***Correspondence to:** Dr. Nikita Chandak, Email: niki.nikichandak@gmail.com

Copyright.

© 2026 **Dr Nikita Chandak**, This is an open access article distributed under the Creative Commons Attribution License, which permits unrestricted use, distribution, and reproduction in any medium, provided the original work is properly cited.

Received: 05 December 2025

Published: 01 February 2026

DOI: <https://doi.org/10.5281/zenodo.18385082>



Abstract

Squamous cell carcinoma (SCC) of the lower lip is a common oral malignancy, strongly linked to environmental and lifestyle factors such as ultraviolet radiation and tobacco use. Early diagnosis and surgical excision remain the cornerstone of management. Reconstruction after wide excision is crucial to restore aesthetics and function. The Bernard-Webster flap provides a reliable single-stage solution for large central lower lip defects.

A 61-year-old Nepalese female presented with a painless, progressive ulcer on the lower lip for five months. She had no history of tobacco use or significant sun exposure. Biopsy confirmed squamous cell carcinoma. Contrast-enhanced CT revealed a $2.2 \times 1.4 \times 1.8$ cm lesion without deep invasion or significant nodal involvement, staged as T2N0M0. The patient underwent wide local excision with right modified radical neck dissection (MRND type III). The resulting defect was reconstructed using a bilateral Bernard-Webster flap.

Postoperative recovery was uneventful. The patient resumed oral intake on day one, and the surgical site healed without infection, hematoma, or wound dehiscence. She was discharged on postoperative day three. Sutures were removed on day 14, with healthy scar formation and no gaping. At one-month follow-up, the patient demonstrated good lip competence, intact oral continence, and clear speech. By the third postoperative month, scar maturation was satisfactory, cosmetic appearance was acceptable, and functional outcomes including mastication, swallowing, and articulation were preserved. No local recurrence, nodal disease, or distant metastasis were detected during this follow-up period.

This case demonstrates that wide excision with MRND and bilateral Bernard-Webster flap reconstruction is an effective approach for lower lip SCC, offering oncological safety, functional restoration, and satisfactory aesthetics. Long-term follow-up remains essential.

Introduction

Lip carcinoma represents a distinct subset of oral cavity cancers, with squamous cell carcinoma (SCC) being the predominant histological type. SCCs occur more frequently in elderly white men (male-to-female ratio, 28.5:4.3), has a peak incidence in the sixth and seventh decades, and is more common in the lower lip (>95% of cases). Over 95% of lip cancers occur on the lower lip, with a peak incidence in the sixth to seventh decade of life and a male predominance [1]. Recognized risk factors include prolonged sun exposure, tobacco use, alcohol consumption, and infection with oncogenic strains of human papillomavirus (HPV) [2]. India bears a high burden of lip and oral cavity cancers, accounting for more than 100,000 new cases annually [3]. According to NCCN and ESMO guidelines, surgical excision with adequate margins remains the treatment of choice for localized lip SCC [4]. Reconstruction is equally important to restore speech, oral competence, and cosmesis. Among available techniques, the Bernard-Webster flap is well-suited for extensive central lower lip defects, providing good functional and aesthetic results [5,6]. This case report highlights the surgical management of a lower lip SCC with reconstruction using a bilateral Bernard-Webster flap.

Case Presentation

A 61-year-old Nepalese female presented with a non-healing ulcer on her lower lip for five months. The lesion was painless and progressively enlarged. She denied bleeding, dysphagia, or significant risk factors such as smoking or prolonged sun exposure. Her medical history was unremarkable.

Examination: A well-defined, ulcero-proliferative growth measuring 3 × 2 cm was seen on the right lower lip, extending toward the midline without commissure involvement. [figure 1] The lesion was firm, non-tender, and non-mobile. Few sub centimetric cervical lymphadenopathy was detected. Intraoral examination was otherwise normal.

Investigations: Biopsy confirmed moderately differentiated SCC. Contrast-enhanced CT of the face and neck [figure 2 -3] showed a localized iso-to-hypodense lesion (2.8 × 1.4 × 2 cm) with peripheral enhancement, extending toward the buccal mucosa without deeper invasion. Subcentimetric lymph nodes were noted in the submental and level IIa regions without necrosis. The tumor was staged as T2N0M0.

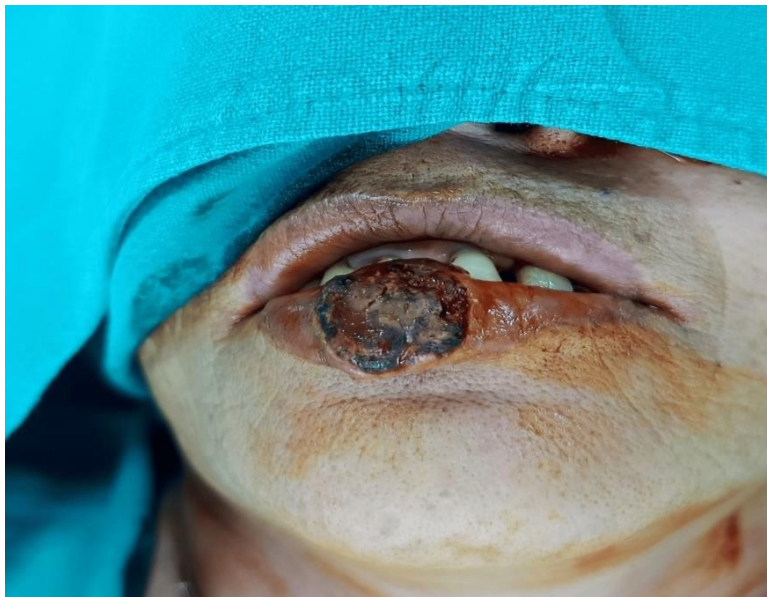

Figure 1: Preoperative view showing lip carcinoma

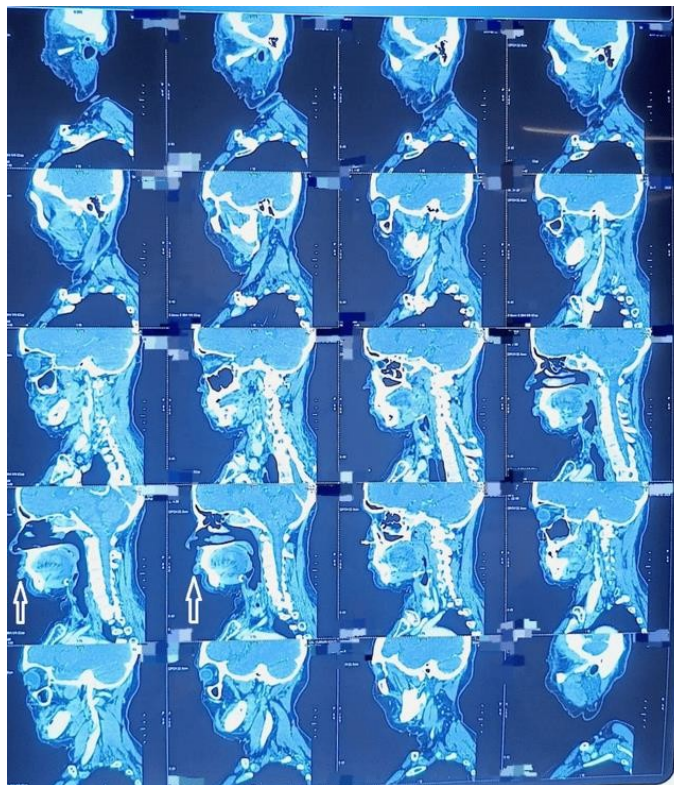


Figure 2: CT scan-sagittal section showing lip carcinoma [yellow arrow]

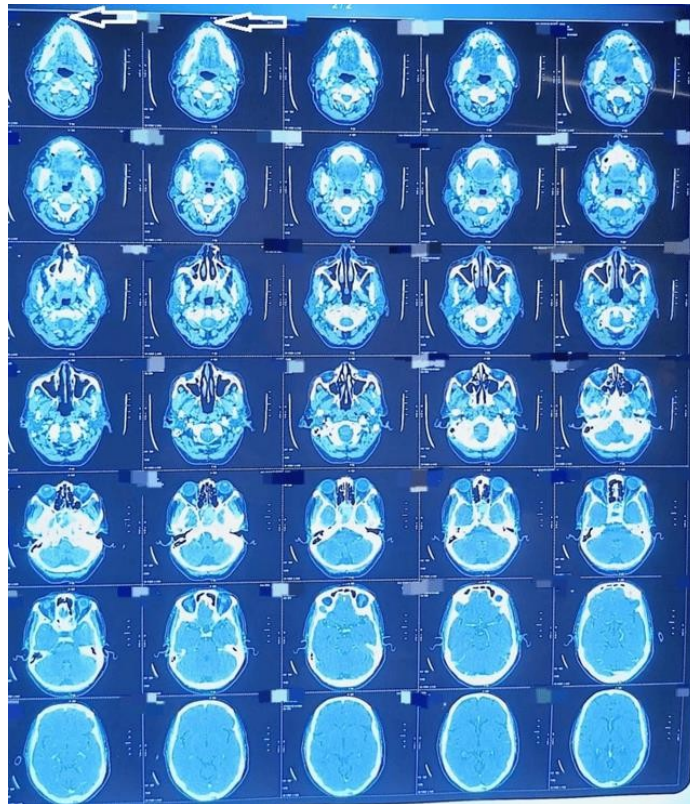


Figure 3: CT scan -axial section showing lip carcinoma [yellow arrow]

Management: The patient underwent wide local excision with 1 cm margins [figure 4] and right MRND type III and left SOHND, given the suspicious lymphadenopathy. The resultant defect, involving $>2/3$ of the lower lip, was reconstructed with a bilateral Bernard-Webster flap.

OPERATIVE TECHNIQUE:

The reconstructive procedure began with careful marking of inverted U-shaped bilateral cheek advancement flaps along the natural nasolabial folds to ensure optimal symmetry and scar concealment. This design allowed the flaps to provide adequate tissue for central lip reconstruction while maintaining an aesthetic contour consistent with facial lines.

Instead of excising Burrow's triangles, modified V-Y advancement flaps were planned to facilitate additional advancement and minimize the risk of postoperative microstomia. This modification also preserved the natural oral commissure and enhanced mouth opening.

Following the marking, flap elevation was carried out in the full thickness, including skin, subcutaneous tissue, and the orbicularis oris muscle, ensuring adequate vascularity and tissue bulk [Figure 5]. The inclusion of the orbicularis oris was essential for re-establishing dynamic sphincteric function.

The flaps were then mobilized medially and advanced toward the midline to reconstruct the lower lip. Careful inseting was performed to achieve accurate alignment of the vermilion border and restoration of lip continuity, thereby maintaining oral competence and symmetry.

Layered closure was performed meticulously in three planes-mucosa, muscle, and skin-to ensure watertight sealing, optimal healing, and minimal tension on the suture line [Figure 6]. Finally, neck dissection

encompassing lymph node levels Ia to IV was undertaken as part of oncological clearance to address potential regional metastasis.

The procedure was complication-free. The patient was extubated and resumed oral intake on postoperative day one. She was discharged on day three. Sutures were removed on day 14. At 3-month follow-up, she exhibited excellent lip competence, normal speech, and good cosmesis [figure 7].

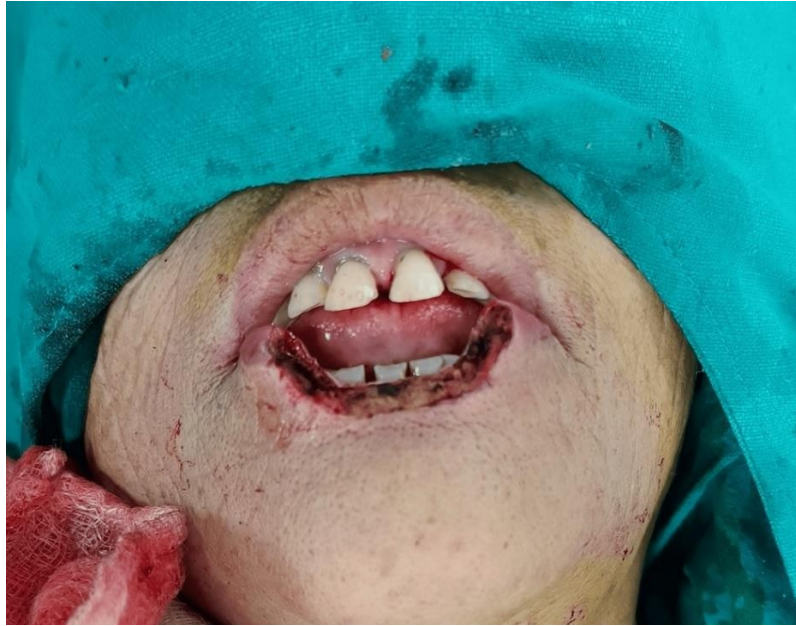

Figure 4: Intraoperative view showing wide local excision of lower lip lesion

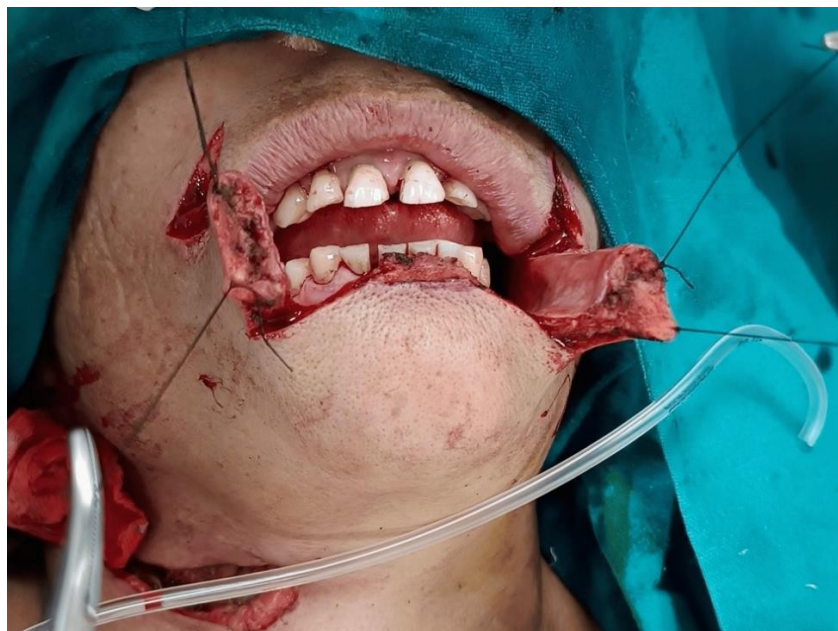

Figure 5: Intraoperative view showing Bernard flap reconstruction

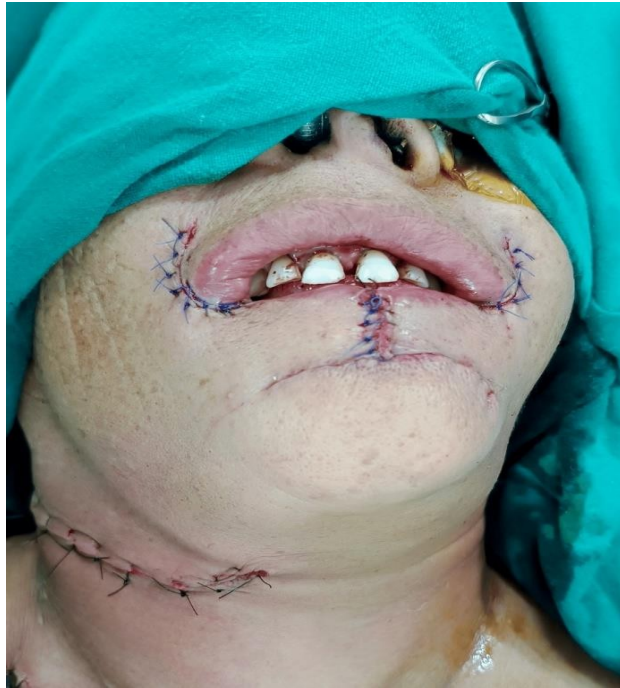

Figure 6: Postoperative view (POD0) after bilateral Bernard-Webster flap reconstruction.

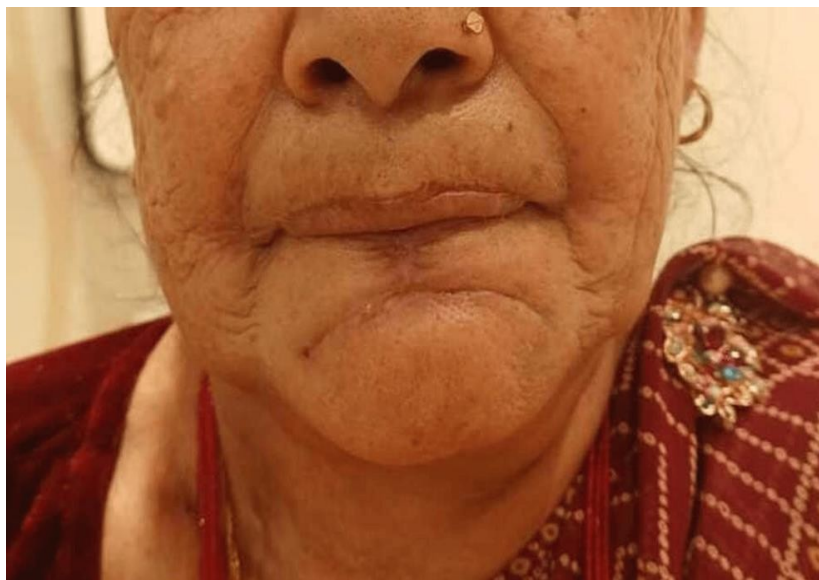


Figure 7: Postoperative view (POD90) after bilateral Bernard-Webster flap reconstruction.

Discussion

Squamous cell carcinoma (SCC) of the lip represents one of the most frequent malignancies of the oral cavity, with the lower lip involved in approximately 90-95% of cases due to increased exposure to ultraviolet radiation and other environmental carcinogens [6-7]. Although more common in older males, recent demographics show a rising incidence in females as well [6]. Surgical excision with appropriate margins continues to be the primary treatment modality, given the risk of local invasion or cervical spread if left untreated [6-7]. In this case, wide local excision with modified radical neck dissection (MRND type III) was selected based on imaging findings and is supported by NCCN/ESMO recommendations for T2 lesions with suspicious lymph nodes.

Reconstructive Considerations.

Lower lip reconstruction must preserve critical functions such as oral competence, articulation, salivary continence, mastication, and acceptable aesthetics. The technique chosen varies by size, anatomical site, and depth of the surgical defect [8-11] [Table No. 1]

| Technique | Indication | Advantages | Limitations |
|----------------------|-------------------------------------|---|------------------------------------|
| Primary closure | Defects <30% of lip | Simple, single stage | Distortion if >30% of lip resected |
| Abbe flap | Central defects up to 60% | Good aesthetics, maintains orbicularis continuity | Requires 2 stages, donor site scar |
| Karapandzic flap | Defects up to two-thirds | Preserves neurovascular supply, good competence | Risk of microstomia |
| Estlander flap | Commissure involvement | Useful for lateral/commissure defects | May distort oral commissure |
| Bernard-Webster flap | Central defects >2/3 of lip | Single stage, robust, reliable, good aesthetics | May shorten lip, risk of scarring |
| Free flaps | Very large/composite defects (>2/3) | Restores bulk, versatile | Technically demanding, 2-stage |

Table 1: Various reconstruction technique

The Bernard-Webster flap, established in 1845 and later modified, remains an excellent option for reconstruction of large central lip defects due to its reliable vascularity and local tissue compatibility [9-10]. The use of Burrow's triangles as V-Y advancement flaps in modified approaches reduces microstomia, preserves oral aperture, and improves overall aesthetics [12-14]. Denadai et al. demonstrated 92% patient satisfaction with functional and cosmetic outcomes using this modification [12]. In the present case, we observed similar favorable results.

Functional and dynamic restoration of the lip is of paramount importance because the orbicularis oris muscle acts as the sphincter of the mouth and is essential for speech, mastication, and saliva control. Therefore, reconstruction should aim not only to close the defect but also to restore dynamic muscle continuity. The Bernard-Webster flap achieves this by preserving muscular integrity and neurovascular continuity, thereby maintaining oral competence [8,11]. Local flap techniques, such as those of Bernard-Webster and Karapandzic, have demonstrated comparable functional outcomes to microsurgical free flaps but with lower morbidity and shorter operative time [11]. Rena et al. emphasized that local flaps, when properly executed, provide both oncological safety and excellent functional recovery in patients with lower lip SCC [6]. For very extensive or composite defects, dynamic muscle flaps such as the neurotized gracilis flap can be considered;

however, these are reserved for more complex cases due to the need for microsurgical expertise [15]. A recent systematic review showed that muscle-based reconstructions achieved better oral competence rates (98%) compared with fasciocutaneous methods (83%), underscoring the importance of dynamic reconstruction in functional restoration [16].

The decision to perform MRND type III in this case was justified, as nodal metastasis occurs in approximately 10-15% of moderately differentiated T2 SCCs of the lower lip [6,7]. Prophylactic neck dissection in such cases improves local control and survival outcomes. Postoperative care plays an equally vital role in optimizing recovery. Maintenance of oral hygiene, antiseptic mouth rinses, early resumption of oral feeding, and dedicated physiotherapy help prevent flap contracture and maintain perioral muscle tone. Baumann and Robb also highlighted the necessity for long-term follow-up to detect local recurrences or secondary primaries, which are not uncommon in high-risk patients [8].

From an aesthetic standpoint, the Bernard-Webster flap remains one of the most dependable options for central lip reconstruction. The strategic placement of incisions along natural nasolabial creases ensures scar camouflage, while V-Y advancement of the flap helps maintain vertical lip height and vermilion contour [10,12,14]. Brinca et al. observed that the Bernard-Webster flap offers superior midline projection and symmetry compared with the Karapandzic flap, particularly in large central defects where commissures are spared [9]. Recent literature further supports this technique as a versatile and robust option for extensive lower lip defects without necessitating microvascular transfer [10].

While this case demonstrates excellent oncological and reconstructive outcomes, it represents a single clinical experience. Larger multicentric studies with standardized outcome measures are needed to further validate the long-term oncologic safety, functional success, and aesthetic satisfaction associated with this approach. The incorporation of modern tools such as three-dimensional digital imaging and flap simulation software may enhance preoperative planning and improve postoperative symmetry and contour in future reconstructions [16]. Additionally, employing validated functional assessment scales such as the Oral Function Scale and FACE-Q questionnaire would allow for more objective evaluation of patient-reported outcomes.

Conclusions

This case underscores the importance of comprehensive surgical management of lower lip SCC, combining wide local excision, appropriate neck dissection, and robust reconstruction. The bilateral Bernard-Webster flap proved effective in restoring oral competence, speech, and aesthetics. Long-term follow-up remains essential given the risk of recurrence and secondary head and neck malignancies.

References

1. Tali TA, Amin F, Khan NA, et al.: [Clinico-epidemiological profile and treatment outcome of lip cancer: a retrospective study from north India](#). Int J Res Med Sci. 2023;11, 2145:8. [10.18203/2320-6012.ijrms20231633](#)
2. [Cleveland Clinic. Lip Cancer: Symptoms, Stages & Treatment](#). <https://my.clevelandclinic.org/health/diseases/21933-lip-cancer>.
3. Mathunny MM, Sivakumar R, Padmakumar SK: [Burden of lip and oral cavity cancers in the Indian subcontinent: a comparative analysis](#). J Oral Maxillofac Pathol. 2024, 28:565-569. [10.4103/jomfp.jomfp_109_24](#)
4. [National Comprehensive Cancer Network \(NCCN\). Head and Neck Cancers Guidelines](#). Version. 2025, [10.6004/jnccn.2025.0007](#)
5. Denadai R., Sarmento G., Buzzo C.L., et al.: [Use of Bernard-Webster flap for lower lip reconstruction after excision of squamous cell carcinoma: analysis of functional results](#). 10:5935/2177. [10.5935/2177-1235.2015RBCP0110](#)
6. Rena W., Lia Y., Liua C., et al.: [Surgical management of squamous cell carcinoma of the lower lip: an experience of 109 cases](#). 398-402. [10.4317/medoral.19595](#)
7. Babu G., Ravikumar R., Rafi M., et al.: [Treatment outcomes of squamous cell carcinoma of the lip: A retrospective study](#). Oncology letters, 25, 8. [10.3892/ol.2022.13594](#)
8. Baumann, D., & Robb, G. (2008): [Lip reconstruction](#). Seminars in plastic surgery. 22:269-280. [10.1055/s-0028-1095886](#)
9. Brinca A., Andrade P., Vieira R., et al.: [\(2011\): Karapandzic flap and Bernard-Burrow-Webster flap for reconstruction of the lower lip](#). Anais brasileiros de dermatologia, 86(4 Suppl. 1):156-159. [10.1590/s0365-05962011000700041](#)
10. Winston R. Owens , Diego M. Quirarte , Srinithya R. Gillipelli , et al.: [Lip Reconstruction](#). Seminars in Plastic Surgery. (Thieme) (online version. 2024, [10.1055/s-0044-1792107](#)
11. Shukla Aishwarya; Loy Kelsey; Lu G. Nina.: [Total lower lip reconstruction: a review of recent advances](#). Current Opinion in Otolaryngology & Head and Neck Surgery 31(6): p 441-451, December. 2023, [10.1097/MOO.0000000000000926](#)
12. Denadai R., Raposo-Amaral C. E., Buzzo C. L., et al.: [Functional lower lip reconstruction with the modified Bernard-Webster flap](#). Journal of plastic, reconstructive & aesthetic surgery : JPRAS. 68:1522-1528.

13. Colevas A. D., Cmelak A. J., Pfister D: [G., et al. NCCN Guidelines® Insights: Head and Neck Cancers, Version 2.2025. J Natl Compr Canc Netw. 23:2-11.](#)
14. Denadai R., Raposo-Amaral C. E., Buzzo C: [L., et al. Functional lower lip reconstruction with the modified Bernard-Webster flap. Journal of plastic, reconstructive & aesthetic surgery : JPRAS. 68:1522-1528.](#)
15. Krakowczyk Ł., Opyrchał J., Bula D., et al.: [Dynamic Reconstruction of the Lower Lip With Free Functioning Gracilis Muscle Transfer. The Journal of craniofacial surgery, 33, 1655-1658.](#)
16. Murray-Douglass, A., Romeo: [P., Fox, C. Free Flap Reconstruction of the Lower Lip: A Systematic Review and Meta-Analysis. Journal of reconstructive microsurgery. 41:302-311. 10.1055/s-0044-1788543](#)



Medtronic