



Ameloblastoma: Reconstruction Using Titanium Plates. Case Report

**Juan Carlos Quintana Díaz ^{*1}, Carlos Alberto Botella Suarez ², Evis Johnson Montero ³,
Odalys Pacheco Sasplugas ⁴, Lilianne Marcel Johnson ⁵**

1. *Maxillofacial Surgeon. Associated Professor, Princess Marina Hospital, Gaborone, Botswana. Orcid: 0000-0002-8629.*
2. *Maxillofacial Surgeon, Princess Marina Hospital, Gaborone, Botswana. Orcid: 0000-0002-7025-0588.*
3. *Pediatrician, Associated Professor, Princess Marina Hospital. Gaborone, Botswana. Orcid: 0000-0002-7721-3800.*
4. *Pathology Anatomy Specialist, Princess Marina Hospital, Gaborone, Botswana, 0000 0001-9301-7028.*
5. *General Dentist, Princess Marina Hospital, Gaborone, Botswana, Orcid 0009-0002-4859-479.*

***Correspondence to: Juan Carlos Quintana Díaz.** Maxillofacial Surgeon. Associated Professor, Princess Marina Hospital, Gaborone, Gaborone, Botswana. Orcid: 0000-0002-8629.

Copyright.

© 2026 **Juan Carlos Quintana Díaz**, This is an open access article distributed under the Creative Commons Attribution License, which permits unrestricted use, distribution, and reproduction in any medium, provided the original work is properly cited.

Received: 21 April 2026

Published: 01 June 2026

DOI: <https://doi.org/10.5281/zenodo.20473618>

Abstract

Introduction: *Ameloblastoma is a locally invasive tumor that grows slowly and attacks the maxillofacial area. There are various histological variants of ameloblastoma. The most common is follicular ameloblastoma. They are characterized by slow growth and are relatively aggressive locally, with the primary site of origin being the mandible. Late recurrence after surgical management is relatively common and is related to the histologic type, site of origin, and initial treatment modality. The mandibular bone is also a relatively common location for this tumor. Optimal surgical treatment of ameloblastoma should minimize recurrence, restore function and aesthetics, and minimize morbidity at the donor site. Segmental mandibular resection surgery is tumor surgery by removing part of the mandible.*

Case report: *A 25-year-old female patient came with complaints of a mass in the mandible area. The surgical intervention performed on this patient was a mandibulectomy operation and reconstruction with a Titanium plate. From the results of the Anatomic Pathology (AP) examination, follicular ameloblastoma was found in the mandibular.*

Conclusion: *The patient's age and histopathological pattern of the tumor influence the treatment plan, result was satisfactory clinically and radiographic.*

Keywords: *Follicular Ameloblastoma, Benign, Segmental resection surgery*

Introduction

Ameloblastoma is the most common odontogenic tumor, based on research by Nalabolu et al.[1] in 2016 showed that ameloblastoma occurred in 49% of odontogenic tumor cases. Ameloblastoma was first introduced under the name Adamantinoma by a French doctor named Louis-Charles Malassez in 1885, but had previously been discovered by Cusack in 1827. It was finally given the modern name, namely ameloblastoma, in 1933 by Ivey and Churchill. Most ameloblastoma are unilateral (95%) and occur in the posterior region of the jaw (85%). Pinborg and Clausen classified odontogenic tumors based on their clinical and histological features into benign, malignant, and intermediate (borderline) tumors. These tumors are more commonly found in the mandible than in the maxilla and show a predilection for different sites of the mandible in different racial groups.[1-4] Based on its nature, ameloblastoma is an intermediate (borderline) tumor because ameloblastoma is benign but locally invasive with a high recurrence rate if excision is not complete.

Rausyanfikir et al. [6] this tumor theoretically originates from the remaining cells of the enamel organ, from the development of the epithelium of odontogenic cysts, and the basal cells of the oral mucosa. The trigger or stimulus for the neoplastic transformation of the epithelial structure has yet to be discovered with certainty. Radiologically, it can be monocytic or polycystic, and histopathologically, it shows different images, with the highest incidence being the follicular type. The relative frequency of ameloblastoma of the mandible compared to the maxilla varies from 8-20% to 99%.2, [4-6] Lu et al. studied a Chinese population and showed a mean age of 31.4 years with a 1.5:1 male:female ratio, and 90.8% of tumors were in the mandible. A study by Hatada et Al. on the Japanese population showed a mean age of 34.7 years with a ratio of 1.6:1 male:female and 92.6% located in the mandible.[2.4] Ruslin et al. researching in Eastern Indonesia, of 84 patients diagnosed with ameloblastoma, it was found that 14 patients were diagnosed with unicystic ameloblastoma (25%), 60 patients with follicular ameloblastoma (57%) and 10 patients with multicystic ameloblastoma (18%). Reichart and Philipsen stated that the recurrence rate of the follicular type (29.5%) was higher than that of the plexiform type (16.7%) and also that of the acantomatous type (4.5%).[4] The principle of therapy for follicular-type ameloblastoma of the jaw is to remove the entire tumor. Many clinicians prefer radical therapy because of its relapsing nature. Treatment with radical methods can reduce the recurrence rate. The recurrence rate with this method is around 15% compared to conservative treatment methods, which have a recurrence rate of more than 50%.3

Case Report

A 25-year-old female patient came to Maxillofacial Department at Princess Marina Hospital with complaints of a big mass in the middle lower jaw. Also complain difficult to chewing and weight loss (+) 10 kg over 3 months.

Since 10 years ago, the patient was assisted in other hospital, it was removed a dentigerous cyst on the left lower canine. Then, 3 months ago, the patient's mass got bigger, and the patient was referred from her local dental clinic to our hospital.

Incisional biopsy was made under local anesthesia and confirmed our diagnosis Follicular Ameloblastoma. Then, the patient was admitted at the hospital, we made an ECG, blood lab includes blood group, and chest x-ray to prepare for segmental resection surgery. Systemic history (-), Drug and food allergies (-).

On extra oral examination, a mass was found on the middle lower jaw measuring 5x4x3 cm (figure 1 ,A,B). On intra-oral examination, a lump was found on the gingiva of teeth 38-48 with a size of 8x4x3 cm, did not bleed easily, was the same color as the surrounding tissue, had a hard consistency, fix, bone expansion from buccal and lingual area, also severe tooth mobility (figure 2).

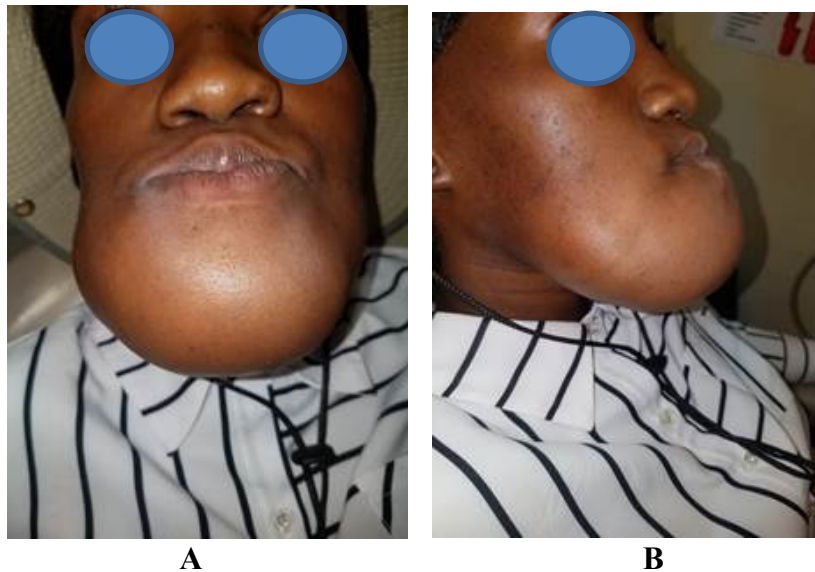


Figure 1. Extra oral examination

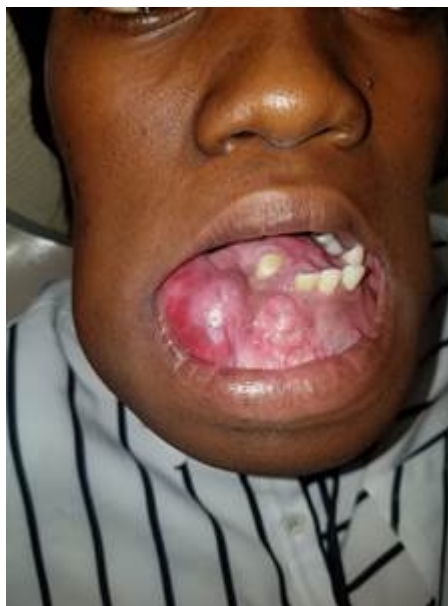

Figure 2. Intra Oral examination

X-ray examination showed extensive multilocular radiolucent image, similar to honey comb or soap bubbles, with a severe teeth root resorption, characteristic in this tumor (Figure 3). The treatment plan, in this case, was mandibulectomy and plate reconstruction at the same time. Under general anesthesia (nasal intubation) was manage satisfactory, and avoid to do a tracheostomy (Figure 4 A, B).

The incision is carried out extra orally; then, the tumor tissue and jaw bone are separated from the soft tissue and muscles attached to it, the entire tumor tissue and jaw bone are removed together with the teeth involved.

The bone defect was repaired and reconstruction was made with Titanium plate (Figure 5 A,B,C)

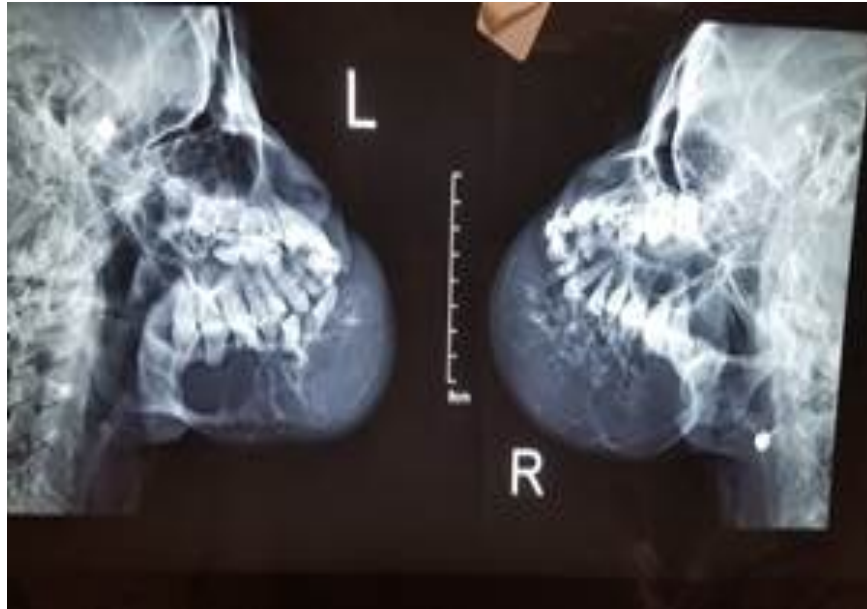

Figure 3. X- Rays examination preoperative

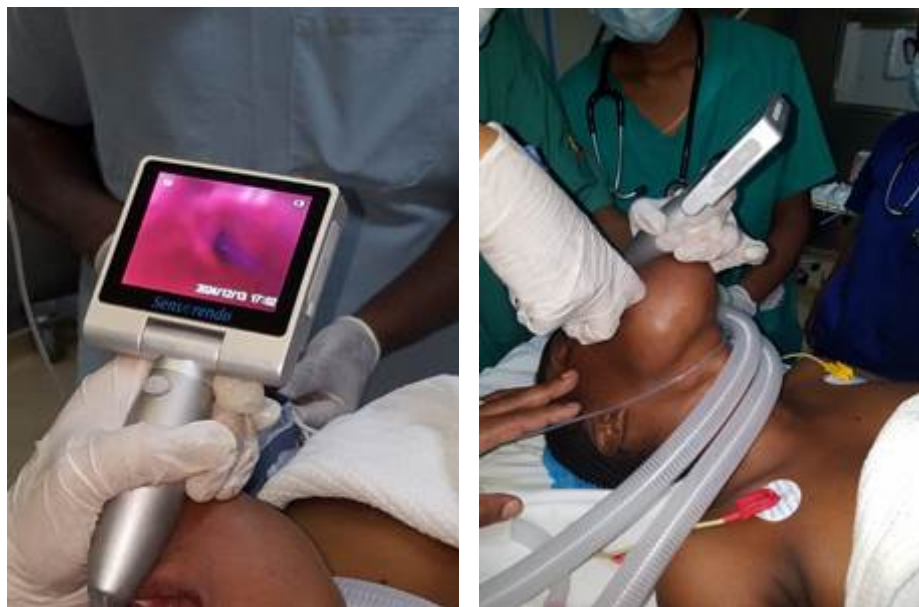

Figure 4. Nasal intubation, general anesthesia

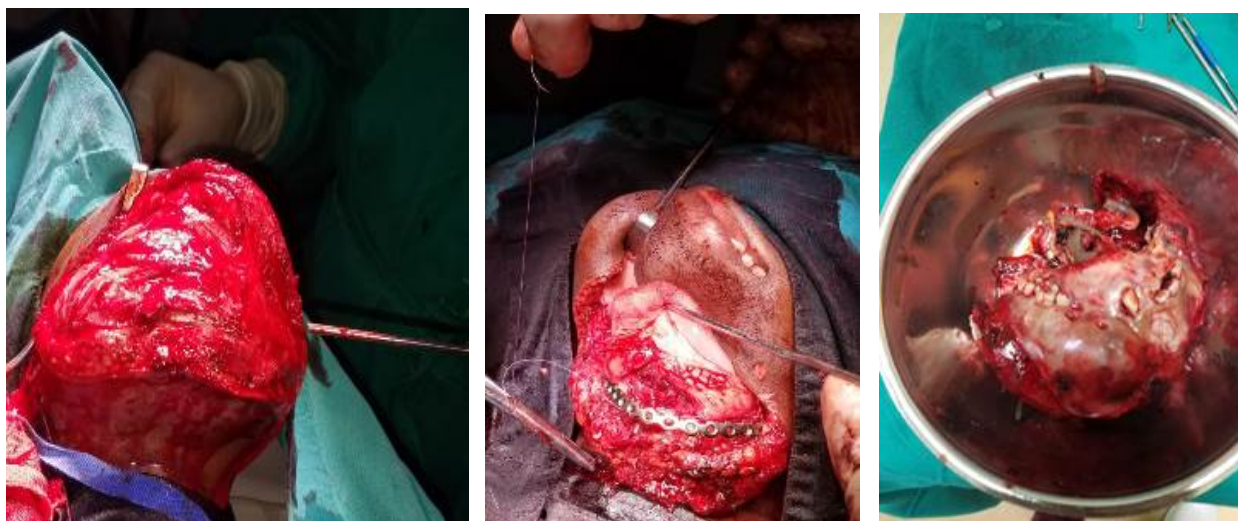

Figure 5. Surgical management and reconstruction

The surgical specimen was again submitted to histopathological analysis, which verified that the margins were tumor-free. This patient remains free of any signs of recurrence following clinical and imaging examinations periodically and she has received prosthetic rehabilitation with functional and aesthetic satisfaction. Clinically and radiographic examination (figure 6) were made to verified post-operative result.

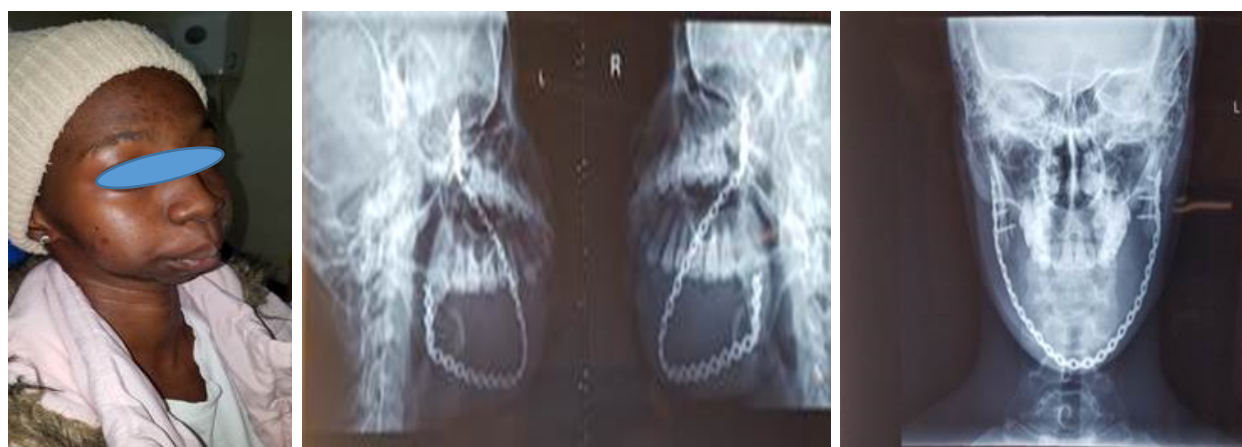

Figure 6. Post-operative results

Discussion

Ameloblastoma is the most common odontogenic epithelial neoplasm. Ameloblastoma growth is slow but locally invasive. It does not cause pain, so it is usually found at an advanced stage, and there has been swelling and bone destruction. [1, 2, 7] Ameloblastomas can occur at any location in the mandible or maxilla, but the regions of the inferior molars and mandibular ramus are the most prevalent anatomical locations (80%) [2,3,4] The literature reveals that follicular ameloblastoma is the most common histological variant (64.9%), followed by plexiform (13.0%), desmoplastic (5.2%) and acanthomatous (3.9%) types. The histological picture of the follicular type shows small islands, at the edges of which are composed of cuboidal or columnar cells whose core is arranged like a fence (palisading). The central part of the island consists of stellate cells similar to the stellate reticulum. Cystic degeneration of epithelial cells often occurs, resulting in cyst cavities appearing in the tumor mass. The follicular type has a histopathological picture that is almost the same as the acanthomatous type. In addition, recurrent tumors of this type are more aggressive and anaplastic than primary tumors.[4] From the literature review, there are various cases where ameloblastoma did not receive early surgical intervention due to reasons including financial conditions, fear of surgery, lack of information, and undetected lesions. Several factors influence growth and prognosis, namely the solid multicystic histological type, young age, and previous therapy.[8]

In general, ameloblastoma shows a lump with a hard or soft consistency depending on the type, namely the solid type or cystic type; it can cause loose teeth, malocclusion, and facial deformity. In certain conditions, the histopathological picture of the ameloblastoma variant is also found, as in this case, it shows the characteristics of the follicular type. Judging from the histopathological picture of the follicular type, it shows small islands, at the edges of which are composed of cuboidal or columnar cells whose core is arranged like a fence. In this case, the central part of the island consists of stellate cells similar to the stellate reticulum. This occurs due to cystic degeneration of the epithelial cells so that cyst cavities arise in the tumor mass. [2, 6, 9] Based on WHO provisions, it is recommended to apply the same treatment modality as for solid ameloblastoma, namely surgical resection therapy, because recurrence is quite high in enucleation or curettage. However, small lesions can be treated with enucleation. Treatment with radical methods can reduce the recurrence rate. According to Muller 1985, the recurrence rate with this method is around 15% compared to treatment with conservative methods, which has a recurrence rate of more than 50%. Treatment in this case was carried out using a radical method, namely segmental resection for ameloblastoma in the right mandible, with the hope that recurrence would not occur in this patient, considering the patient's young age. [2, 3, 8]

One of the complications of ameloblastoma treatment is a defect in the area where tissue is removed, either soft tissue or hard tissue, which can cause a decrease in speech function, mastication and facial asymmetry. However, post-operative care plays an important role in determining the success of surgical therapy, especially in avoiding the recurrence of ameloblastoma cases in these patients. [10]

Conclusion

Summarizing, ameloblastoma are uncommon benign odontogenic neoplasms that rarely become malignant. In most cases, radical surgery is the treatment of choice for solid or multicystic ameloblastoma. Although several articles have been published on the subject, little is known regarding the biological behavior of this tumor, and a careful clinical examination combined with a thorough imaging investigation to evaluate the general aspects of the lesions and its margins, as well as its internal architecture and its relationship to adjacent anatomical structures, can assist in treatment planning. These informations coupled with the histopathological confirmation of the diagnosis will allow for the selection of the best individual therapeutic approaches, increasing the treatment efficacy in patients diagnosed with this tumor.

Competing Interests: The authors declare no conflict of interest.

References

1. Nalabolu GR, Mohiddin A, Hiremath SK, Manyam R, Bharath TS, Raju PR. Epidemiological study of odontogenic tumors: An institutional experience. *Journal of Infection and Public Health*. 2017;10(3):324-30.
2. Andersson L, Kahnberg K-E, Pogrel MA. *Oral and Maxillofacial Surgery*: John Wiley & Sons; 2012.
3. Fonseca RJ. *Oral and Maxillofacial Surgery-E-Book*: 3-Volume Set: Elsevier Health Sciences; 2017.
4. Ruslin M, Hendra FN, Vojdani A, Hardjosantoso D, Gazali M, Tajrin A, et al. The Epidemiology, treatment, and complication of ameloblastoma in East-Indonesia: 6 years retrospective study. *Medicina Oral, Patología Oral y Cirugía Bucal*. 2018;23(1):e54.
5. Lumerman HS, Bowie RB. *Atlas of Oral and Maxillofacial Histopathology*: Lippincott Williams & Wilkins; 2012.

-
6. Aramanadka C, Kamath AT, Kudva A. Recurrent ameloblastoma: a surgical challenge. Case reports in dentistry. 2018;2018.
 7. McClary AC, West RB, McClary AC, Pollack JR, Fischbein NJ, Holsinger CF, et al. Ameloblastoma: a clinical review and trends in management. *European Archives of Oto-Rhino-Laryngology*. 2016;273(7):1649-61.
 8. Effiom O, Ogundana O, Akinshipo A, Akintoye S. Ameloblastoma: current etiopathological concepts and management. *Oral diseases*. 2018;24(3):307-16.
 9. Koong B. *Atlas of oral and maxillofacial radiology*: John Wiley & Sons; 2017.
 10. Au S, Li K, Choi W, Su Y. Risk factors for recurrence of ameloblastoma: a long-term follow-up retrospective study. *International journal of oral and maxillofacial surgery*. 2019;48(10):1300-6