



Post-Acute-COVID-19-Illness Dermatological Sequelae

Ruangrong Cheepsattayakorn¹, Attapon Cheepsattayakorn^{2,3*}, Porntep Siriwanarangsun³

1. Department of Pathology, Faculty of Medicine, Chiang Mai University, Chiang Mai, Thailand.

2. 10th Zonal Tuberculosis and Chest Disease Center, Chiang Mai, Thailand.

3. Faculty of Medicine, Western University, Pathumtani Province, Thailand.

Corresponding Author: Attapon Cheepsattayakorn, 10th Zonal Tuberculosis and Chest Disease Center, 143 Sridornchai Road Changklan Muang Chiang Mai 50100 Thailand.

Copy Right: © 2021 Attapon Cheepsattayakorn. This is an open access article distributed under the Creative Commons Attribution License, which permits unrestricted use, distribution, and reproduction in any medium, provided the original work is properly cited.

Received Date: July 06, 2021

Published date: August 01, 2021

A previous study of 716 COVID-19 patients revealed that 64 % and 15 % of them demonstrated dermatological features after or concurrent to other acute COVID-19 symptoms, respectively [1]. In adult COVID-19 patients, the average latency from the time of upper respiratory symptoms to dermatological manifestations was 7.9 days [2]. At 6-month-follow-up in the post-COVID-19 Chinese study, only 3 % of patients were identified a skin rash [3], whereas hair loss was the predominant dermatological feature, approximately 20 % of the patients [3-5]. *Telogen effluvium* resulting from SARS-CoV-2 (COVID-19) or a stress response can be the causes of hair loss [3]. Dermatological sequelae may be from the significant role of the potential immune or inflammatory mechanisms of COVID-19 [6]. The skin rash manifestations include urticarial rash (treated with low-dose systemic corticosteroids combined with non-sedating antihistamines), purpuric “vasculitic” pattern (treated with topical corticosteroids for mild cases; systemic corticosteroids for severe cases), livedo reticularis/racemose-like pattern (wait and see), chilblain-like acral pattern (wait and see), papulovesicular exanthem (wait and see), confluent

erythematous/maculopapular/morbilliform rash (treated with topical corticosteroids for mild cases; systemic corticosteroids for severe cases) [1, Figure 1, 2], in addition to erythema multiforme-like eruption [7], pityriasis rosea-like rash [8], multi-system inflammatory syndrome in children [9], anagen effluvium [10], and a pseudoherpetic variant of Grover disease [11].

In conclusion, further pathophysiologically and clinically fascinating studies originated from large case series are urgently needed to explore this topic.

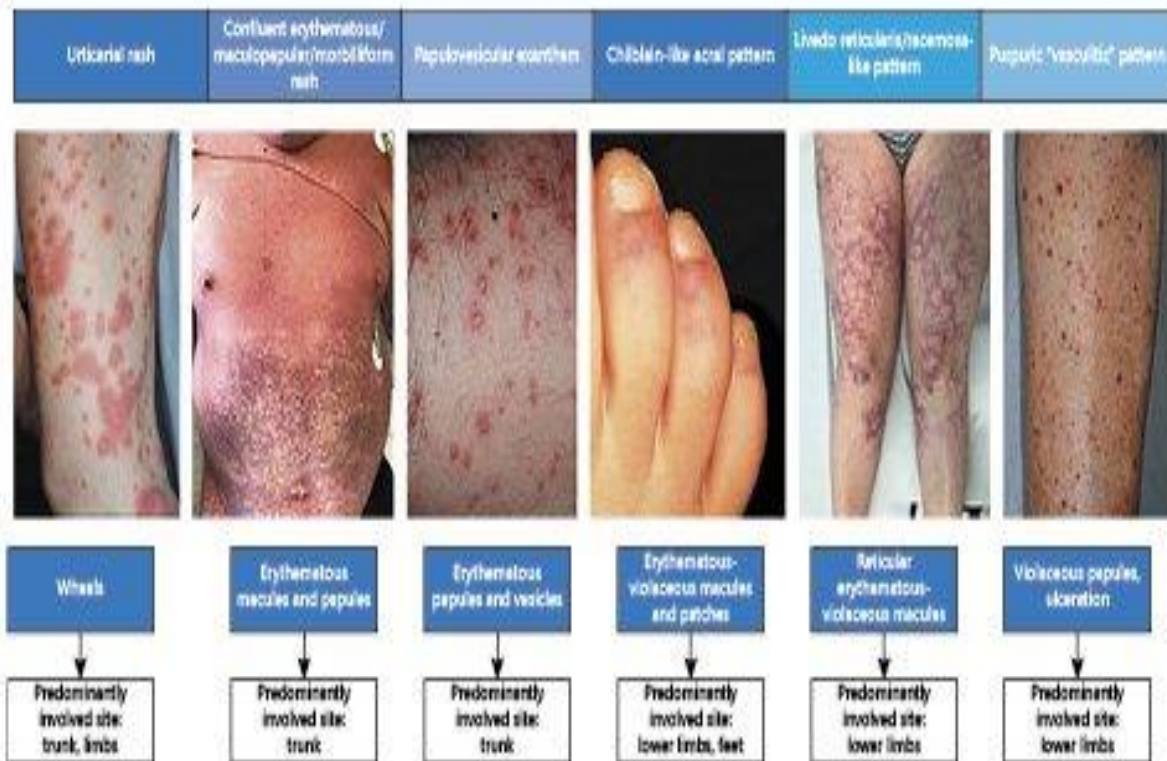


Figure 1 : Demonstrating various dermatological manifestations in acute COVID-19 and post-acute-COVID-19 patients

(Source : Genovese G, Moltrasio C, Berti E, Valerio-Marzano A. Skin manifestations associated with COVID-19 : current knowledge and future perspectives. *Dermatology* 2021; 237 : 1-12. Published Online : November 24, 2020. DOI : 10.1159/000512932)

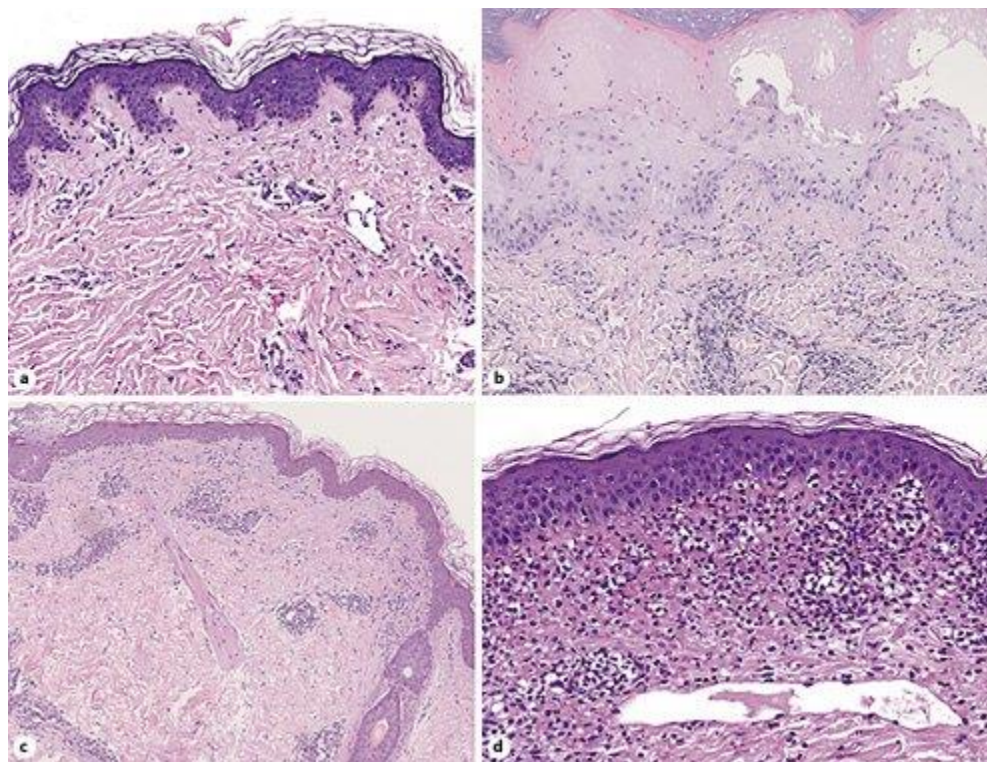


Figure 2 : Demonstrating histopathological features of the main cutaneous patterns associated with COVID-19. a Urticarial rash. b Confluent erythematous maculopapular/morbilliform rash. c Chilblain-like acral lesions. d Purpuric “vasculitic” pattern.

(Source : Genovese G, Moltrasio C, Berti E, Valerio-Marzano A. Skin manifestations associated with COVID-19 : current knowledge and future perspectives. *Dermatology* 2021; 237 : 1-12. Published Online : November 24, 2020. DOI : 10.1159/000512932)

References

- 1.Freeman EE, et al. “The spectrum of COVID-19-associated dermatologic manifestations : an international registry of 716 patients from 31 countries”. *J Am Acad Dermatol* 2020; 83 : 1118-1129.
- 2.Mirza FN, Malik AA, Omer SB, Sethi A. “Dermatologic manifestations of COVID-19 : a comprehensive systematic review”. *Int J Dermatol* 2020. DOI : <https://doi.org/10.1111/ijd.15168>
- 3.Huang C, et al. “6-month consequences of COVID-19 in patients discharged from hospital : a cohort study”. *Lancet* 2021; 397 : 220-232.

4. Garrigues E, Janvier P, Kherabi Y, et al. "Post-discharge persistent symptoms and health-related quality of life after hospitalization for COVID-19". *J Infect* 2020; 81 (6) : e4-e6. DOI : 10.1016/j.jinf.2020.08.029
5. Montani D, Savale L, Beurnier A, Colle R, Noël N, Pham T, et al. "Multidisciplinary approach for post-acute COVID-19 syndrome : time to break down the walls". *Eur Respir J* 2021; in press. DOI : <https://doi.org/10.1183/13993003.01090-2021>
6. Genovese G, Moltrasio C, Berti E, Marzano A. "Skin manifestations associated with COVID-19 : current knowledge and future perspectives". *Dermatology* 2020; 237 : 1-12.
7. Jimenez-Cauhe J, Ortega-Quijano D, Carretero-Barrio I, Suarez-Valle A, Saceda-Corralo D, Moreno-Garcia Del Real C, et al. "Erythema multiforme-like eruption in patients with COVID-19 infection : clinical and histological findings". *Clin Exp Dermatol* 2020; 45 (7) : 892-895.
8. Ehsani H, Nasimi M, Bigdelo Z. "Pityriasis rosea as a cutaneous manifestation of COVID-19 infection". *J Eur Acad Dermatol Venereol* 2020; 34 (9). DOI : <https://doi.org/10.1111/jdv.16579>
9. Gupta A, Gill A, Sharma M, Garg M. "Multi-System Inflammatory Syndrome in a child mimicking Kawasaki Disease". *J Trop Pediatr* 2020 Aug; fmaa060.
10. Shanshal M. "COVID-19 related anagen effluvium". *J Dermatol Treat* 2020; 16 : 1-2. DOI : 10.1080/09546634.2020.1792400
11. Llamas-Velasco M, Chicharro P, Rodríguez-Jiménez P, Martos-Cabrera L, De Argila D, Fernández-Figueras M, et al. Comment on "Clinical and histological characterization of vesicular COVID-19 rashes : a prospective study in tertiary care hospital". Pseudoherpetic Grover disease seems to occur in patients with COVID-19 infection. *Clin Exp Dermatol* 2020; 45 (7) : 896-898.