



## **The Effectiveness of Multiple Metallic Clips in Terms of Margin Safety in Breast Conservation Surgery after Neoadjuvant Systemic Therapy**

Dr. Rabia Ikram <sup>\*1</sup>, Dr. Huma Majeed Khan <sup>2</sup>, Dr. Eisha Tahir <sup>3</sup>, Dr. Anam Waseem <sup>4</sup>,

Dr. Bushra Rehman <sup>5</sup>

**Corresponding Author: Dr. Rabia Ikram**, Fellow Breast Surgery, Ittefaq Hospital Trust, Lahore.

**Copy Right:** © 2023 Dr. Rabia Ikram, This is an open access article distributed under the Creative Commons Attribution License, which permits unrestricted use, distribution, and reproduction in any medium, provided the original work is properly cited.

**Received Date: February 15, 2023**

**Published Date: April 01, 2023**

**DOI:** [10.1027/maroy.2023.0247](https://doi.org/10.1027/maroy.2023.0247)

**Abstract**

**Introduction:** *In resource-limited countries like Pakistan breast conservation therapy (BCT) is a challenge because there are higher numbers of patients presenting with T2-T4 lesions. The identification of tumor bed after neoadjuvant systemic therapy (NAST), especially with complete clinical response (cPR) is challenging in these patients but still possible with the help of using metallic markers. The objective of this prospective single-institute study with a short-term aim is to evaluate the effectiveness of parking multiple metallic clips in patients undergoing NAST and BCT in terms of margin safety.*

**Method:** *We observed 81 patients who fulfilled the inclusion criteria and were operated at the Ittefaq Hospital Trust, Lahore from January 2021 to July 2022. After clinical assessment and radiological adjuncts, multiple metallic clips were parked at the widest dimension of the tumor before NAST. These multiple metallic clips (MMC) were later used as a tumor bed marker for adequate surgical excision and margin safety.*

**Results:** *Our re-do surgery rates were 1.23%. Of 81 patients, we had 6 patients with focal positive margin and two patients with positive margin, of which only one patient has been offered re-excision surgery as per the American Society of Breast Surgeons (ASBrS) guidelines.*

**Conclusion:** *Our study shows oncological margin safety with MMC placement in BCT candidates undergoing NAST.*

**Key Words:** *Breast conservation therapy, Clips, Margins, Neoadjuvant therapy.*

## Introduction

The rising incidence of breast cancer in a resource-limited country like Pakistan poses a great challenge to patient's diagnosis and survival outcomes. One of the cancer registry programs of Pakistan covering 19 hospitals, shows a rising trend with 9584 new cases of breast cancer in 2019 as compared to 8816 in 2018. [1] For 2018, the cancer registry reported 327 cases for stage I, 2049 cases for stage II, 3886 and 1818 cases for stage III and IV respectively. [1] According to 2021 statistics, every 1 in 9 Pakistani women is at the risk of developing breast cancer in their lifetime, with the maximum burden of the disease being in women aged 40-44 years. [2-4] The standard of care for patients undergoing breast conservation therapy (BCT) for T2 or larger breast mass is neoadjuvant systemic therapy (NAST) followed by surgery and radiation therapy. [5-7] The aim of the treatment is to ensure maximum disease-free survival (DFS) along with prevention of distant and loco-regional recurrence (LRR) with all the current resources available. [8-9]

The BCT requires clipping of the breast masses before systemic therapy for optimal surgical outcomes. Pre-NAST clipping of the malignant breast mass with radiopaque/metallic markers has been in practice for the past two decades and was endorsed by international breast cancer specialist panels in 2006 and 2010. [10-12] Tumor response to NAST is variable, some remain palpable throughout treatment, while others disappear completely and are identifiable only by radiopaque clips in the tumor site. [13,14] After completion of NAST with the complete clinical and radiological response, it is challenging in these cases to ensure that the tumor bed is completely excised in BCT. [15-17]

Adequate margin clearance during surgery is essential for patient survival. 1 in 4 lives can be saved by obtaining a clear margin during BCT. [18] Limited data is available on the potential of using multiple clips for adequate margin clearance. Therefore, we are proposing that a single clip in smaller tumors is good enough for that purpose, but in 2.5cm or larger tumors, at least 2 or more clips should be placed at the widest margin in the coronal plane so that adequate resection margin clearance may be obtained. We also propose to place multiple clips in multifocal tumors and bracket microcalcification.

**Objective:** Effectiveness of multiple clips to ensure oncological margin safety in breast cancer patients, undergoing neoadjuvant systemic therapy and breast conservation surgery.

## Material & Method

This is a single-center, prospective cohort study, from January 2021 to July 2022. All cases are operated on or supervised by a single surgeon and all clips are parked in breast tumors by a single radiologist.

**Inclusion criteria:** The inclusion criteria were all patients between the age of 18 and 80 years, who were candidates for NAST and BCT

**Exclusion criteria:** Patients with early breast cancer needing upfront surgery, patients with the multicentric disease, locally advanced or inflammatory breast cancer, patients opting for mastectomy and patients presented after excision biopsy elsewhere were excluded.

After the institute's ethical board approval, data of the patients who have fulfilled the inclusion criteria was collected by a standard performa after their consent. This included patient demographics, primary disease, focality of tumor masses, number of clips inserted, radiological and histopathological margin clearance, and any complication; hematoma, clip migration, etc. The data was analyzed using Stata 17.0. We had both continuous and categorical variables in our data. Age, tumor size, DCIS, and post-NACT tumor size were continuous variables. Categorical variables included the focality of the tumor, presence, and absence of DCIS, margin status, and receptor status. Univariate analysis of age, tumor size, and DCIS was performed. The comparison of the categorical variables is done using bar charts and pie charts.

### Pre- NACT Treatment Protocol:

All patients were clinically assessed followed by imaging, biopsy, and a multidisciplinary decision for BCT after neoadjuvant systemic therapy was made and this information is documented.

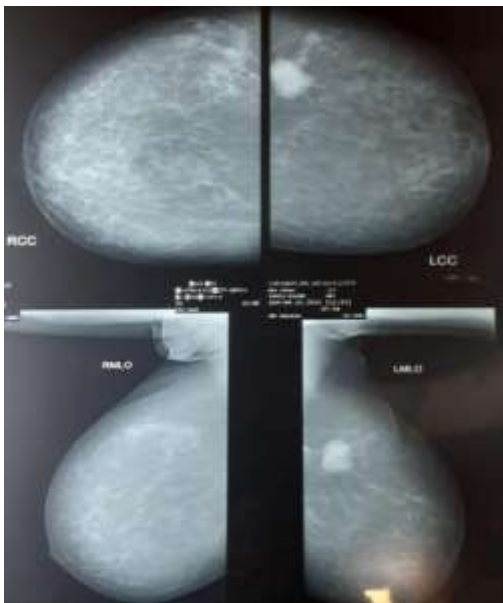
After the final decision of BCT in MDT the patient was booked for clipping. We used 1-1.5 cm cut pieces of a 5-cc disposable syringe needle; the bevel end of the needle is discarded. These pieces are inserted into the breast tissue via a lumbar puncture (LP) needle under aseptic measures and local anesthesia. It is not only confirmed on ultrasonogram (USG) that the clips are hyperechoic linear structures but also on the post-procedural mammogram (MG) that they are located appropriately. In lesions 2.5cm or > in size, we inserted clips at the widest dimension in the coronal plane.

### Post NACT Treatment Protocol: Or Pre-Operative assessment:

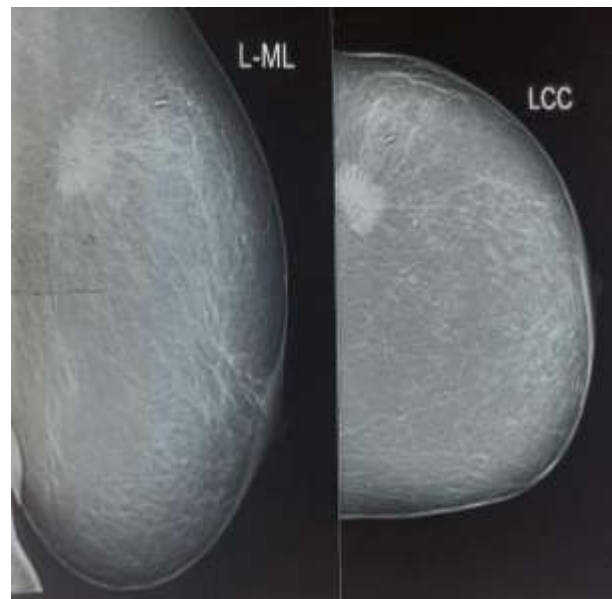
Patients were assessed clinically and radiologically after the completion of neoadjuvant therapy to assess the tumor response and pre-operative planning. For patients with complete clinical response (cCR) after NAST, pre surgery mammogram; true lateral and CC views of the concerned side are taken to see the residual mass as well as the position of the clips. Additionally, ultrasound guided marking scan was also performed a day before surgery for any residual disease and clips, and the area is marked on the skin, while the patient was lying supine with the concerned arm extended at the right angle (surgical position).

### Surgical Protocol: Or Intra-Operative Protocols

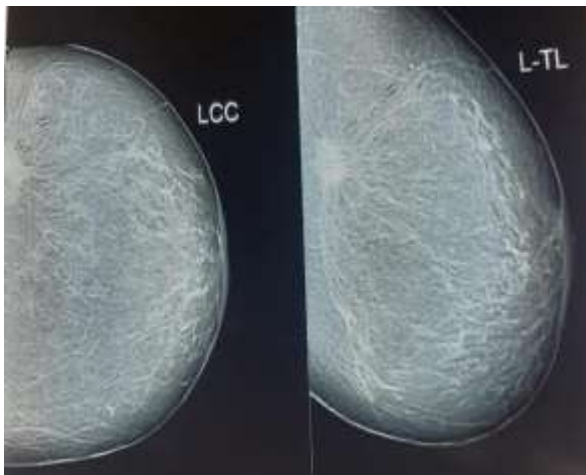
A suitable incision was made on the breast and the area of concern was excised with a rim of surrounding normal tissue. Excised specimen was checked under C- arm for clip presence and adequacy of excision. The specimen is oriented with a suture for histopathological evaluation. Histopathologically tumor-free margins remain the gold standard.



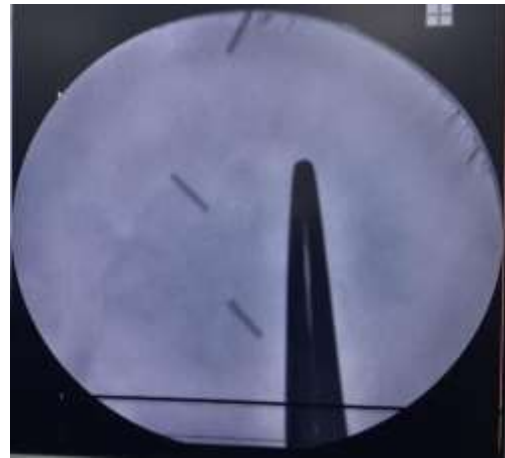
**Fig 1.1:** Left MG shows multifocal breast carcinoma.



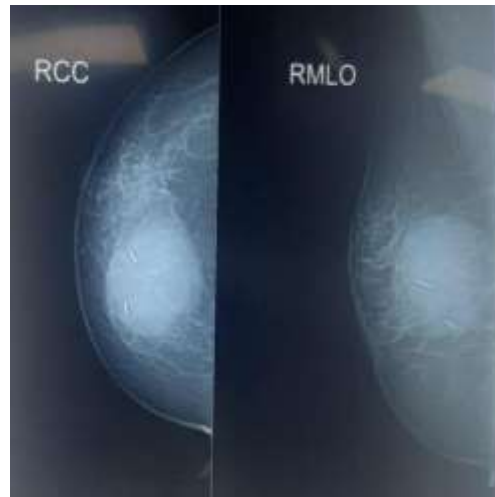
**Fig 1.2:** Post clip MG shows three metallic clips, two of which were parked at the farthest edges of the main mass and one parked in the satellite.



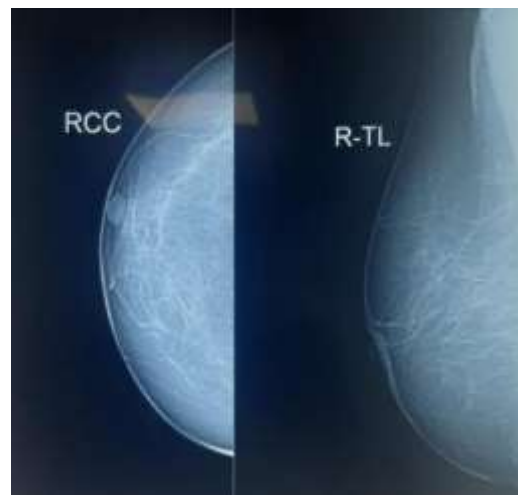
**Fig 1.3:** Post NAST MG demonstrates partial radiological response with metallic clips marking the tumor bed.



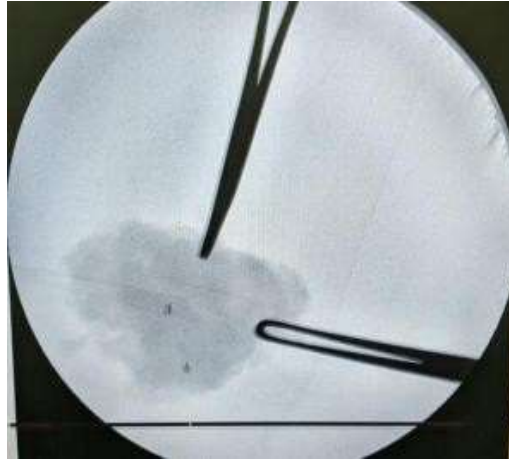**Fig 1.4** Specimen shows satisfactory removal of the tumor bed manifested by all three metallic clips seen on the image intensifier. 2 clips are well within the index lesion, while the clip in the satellite lesion is also seen in the image. On histopathology all margins are clear.



**Fig 2.1.** MG of the right breast shows 2 metallic clips placed in the mass, at the widest margin in the coronal plane.



**Figure 2.2.** Post NAST MG demonstrates complete radiological response with shrinkage of tumor bed as manifested by approximation of the metallic clips.



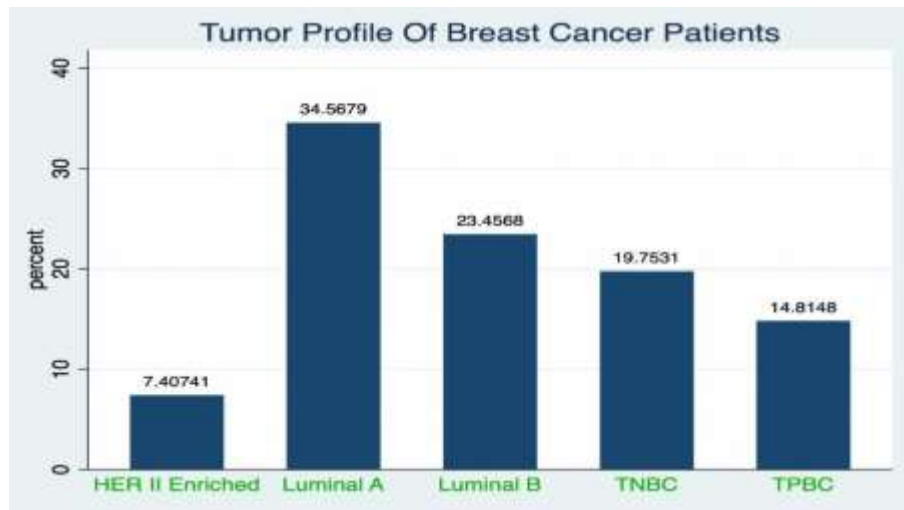
**Fig 2.3.** Clips with adequate margins confirmed in excised specimen images under image intensifier.

## Results

It is an ongoing study, with initially 105 patients that were selected for clipping. Among those 105, 24 either lost the follow-up or didn't give consent and a total of 81 patients participated in the study. The mean age of the patients is 50.12, with the youngest being 24 and the eldest being 80 years old. About 82.72% of our patients had unifocal disease while 17.28% had multifocal disease.

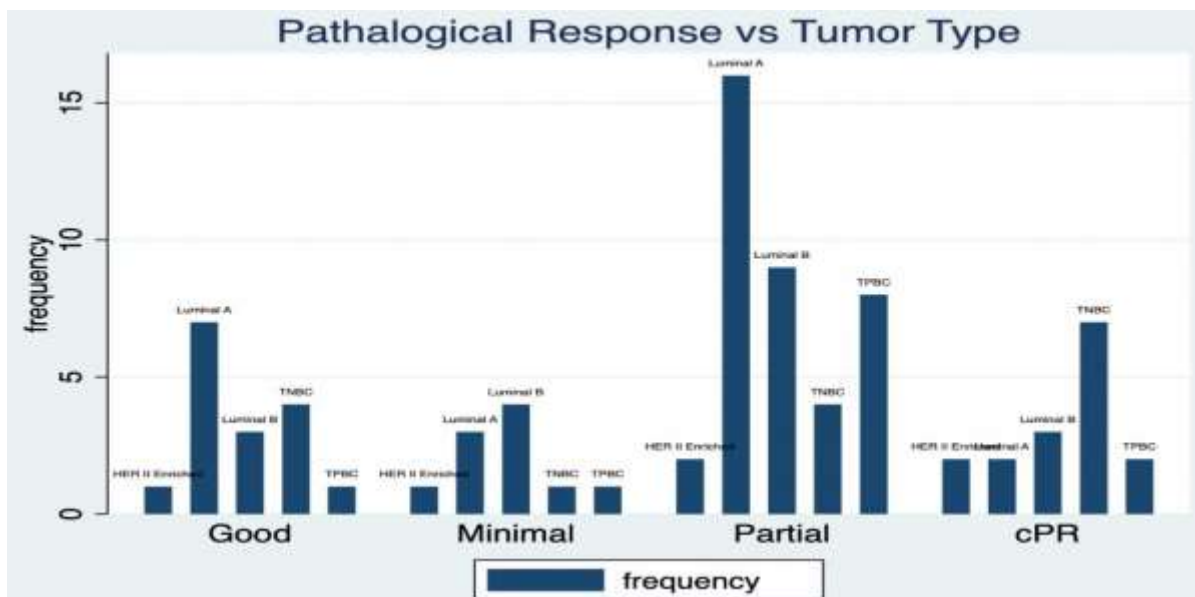
Our study shows 78 patients with invasive ductal carcinoma (IDC), 2 with invasive lobular (ILC) carcinoma, and one with invasive papillary neoplasm. Only 15 patients among the total exhibited concomitant ductal carcinoma in situ (DCIS) on histopathology with a size ranging from 3mm to 50mm. When we analyzed the patients according to tumor profile, 34.57% were luminal A, 23.46% luminal B, 7.4% HER-II enriched, 19.75% triple negative breast cancer (TNBC), and 14.81% triple positive breast cancer (TPBC) (Chart 1). [19-21] The mean tumor size was 42.48mm and the post-NAST histopathological tumor size varied from 0 to 55mm.





**Chart 1:** Tumor profile of the cases in the study

We have 80.25% T2 and 18.25% T3 tumors. One patient with a T1 lesion and TPBC included in the study has multifocal lesions. Of 81 patients 73 were on neoadjuvant systemic and 8 on neoadjuvant hormonal treatment. Tumor response to neoadjuvant treatment was categorized into cPR, good, partial and minimal and it was 19.8%, 19.8%, 48.1% and 12.3% respectively. [38] On further analysis we see that cPR was highest in TNBC, good response in luminal A, partial response again in luminal A, while minimal response ratio was highest in luminal B type of breast cancer in this cohort group (Chart 2). Of interest are 3 patients in our study who have residual microscopic foci of tumour scattered throughout the tumour bed, 2 of which were seen in luminal A and one in luminal B tumour type.



**Chart 2:** Tumor response to neoadjuvant treatment in different tumor profiles.

Out of 81 patients, 72 patients had clear margins on the final histopathology report. Among the remaining 8 patients, 2 patients had positive margins and 6 had unifocal involvement of margins. [22] The uni-focally involved margins don't need re-excision. [23] The one patient with a positive margin was not offered re-excision because according to American Society of Breast Surgeons (ASBrS) 2018 guidelines it may not be necessary for the involved anterior and posterior margins if underlying muscle fascia or overlying skin is removed. [12] In only one patient with ILC, we have positive margins and proceeded with completion mastectomy.

## **Discussion**

In the 1950s Bernard Fisher revolutionized breast cancer management. His concept of breast cancer as a systemic disease changed the entire realm of breast cancer management. [24] Later in 2005, it was proposed that breast cancer is a spectrum of diseases that ranges from locoregional disease to systemic disease. [25] These conceptual advancements in breast cancer understanding opened new horizons not only in systemic management but also in breast conservation therapy (BCT). Many studies demonstrate a significant response of the primary breast lesion to the neoadjuvant therapy with success rates reaching about 80–90%. [26, 27] Even with cCR it is essential to proceed with surgery to see the definitive response of treatment on the tumor. [28]

BCT is a combination of breast-conserving surgery and breast radiation therapy. [29] With every new concept, there are new challenges and with BCT comes the problem of intraoperative localization of tumor bed after the neoadjuvant treatment as well as the oncological margin safety. Metallic clips strategically placed in the tumor bed in the widest dimension not only help the surgeon intra-operatively but also reduce the risks of positive margins and re-excision lumpectomy rates. They help in reducing the ipsilateral breast tumour recurrence (IBTR) and so as overall survival (OS) of the patients. Therefore, placement of clips in the lesions before neoadjuvant treatment is currently the standard of care for post-therapy tumor bed localization and adequate margin resection. [10,30-37]

Tumor response to chemotherapy varies in patients, with high-grade tumors of TNBC and HER II enriched types, a complete clinical and pathological response is achieved quite often. [37]

Tumors regression pattern also varies; some tumors have unifocal regression pattern, while some tumors

show multiple separate foci of residual tumor cells scattered through out the tumor bed after NACT. [38]

Different guidelines, tools, and techniques have been in practice to ensure intra-operative tumor bed localization and excision for better oncological margin safety. [39-41] Royal College of Pathologists recommends sampling the entire tumor bed in three dimensions as residual microscopic tumor foci may be scattered throughout it. [38] So, whether the tumor is palpable or not, the goal of the BCT is the complete excision of the tumor bed with clear surgical resection margins, for which our standard is “no ink on tumor”. [14,17,42-46]

As per consensus guidelines on breast cancer lumpectomy margin by the ASBrS histopathological margin status is a surrogate marker of the residual disease in the breast and IBTR. [14,45] Data suggests that histologically positive margins for both invasive or in situ breast carcinoma (ink positive) after a lumpectomy have increased ipsilateral breast tumor recurrence (IBTR) compared to patients with negative margins. [44,47,48] IBTR and LRR after BCT for invasive cancer can impact patient survival. The Early Breast Cancer Trialists Collaborative Group (EBCTCG) concludes that 1 life is saved at a 15-year follow-up for every 4 local recurrences are prevented at 10 years after lumpectomy.[18]

Quality of margin safety can be indirectly measured by re-excision lumpectomy rates (RELR) by institutes and individual surgeons. RELR is being used as a quality measure (QM) by The European Society of Breast Cancer Specialists (EUSOMA), and the National Consortium of Breast Center (NCBC). [49-55] RELR rates vary greatly from 0% to 70% in the United States, and 12% - 13% in England. [49,56] In other centers use of RELR is controversial and as per ASBrS guidelines; RELR shouldn't be used as a single predictor of QM in BCT. [14]

Positive surgical margin rates (PSM) after BCT for breast cancer are variable. PSM have been reported for palpable and nonpalpable lesions as 38%. In a prospective meta-analysis they have 9.4% positive margins and 17.8% close margins, in another study PSM has improved from 6.54 % in 2004 to 3.91 % in 2013. [57-59] Positive margins in BCT is a cause for high LRR and re-excision surgery is a significant burden on the patient and health care system. [60] Wire localization of the tumor bed is an accepted technique and Lamiaa, et al, has reported clip and wire localization of tumor area with negative margins on a frozen section at 95.5% and negative margins on paraffin blocks at 95%. [12]

Running a breast center in a low-income country isn't easy. [61] We have higher rates of patients presenting with the T2 and T3 lesions, BCT in T3 lesions is tricky but not impossible. [62,63] In our data 80.25% patients were with T2 lesions followed by 18.52% with T3 lesions.

Most of the patients cannot afford commercially available clips and wire localization of these clips. We observed that multiple clips at the margins of the lesion help to achieve negative margins not only in T2 but T3 lesions as well. The technique of placing multiple metallic clips at tumor margins has worked effectively in our center. Our study represents the PSM to be 2.46%, focal positives were 7.4% and re-do surgery rates were 1.23%.

## Conclusion

In the preview of these results, we can suggest that placing multiple metallic clips strategically in the widest dimension of the tumor in the coronal plane is an approach to ensure oncological safe resection margin intraoperatively. Our study shows that the positive margin percentage is lower than the data around the world and it can provide a base for improvisation in BCT. This is an ongoing study but with current data we can ensure patient safety from the surgical point of view with complete tumor resection even with T3 tumors.

## References

1. [https://www.paec.gov.pk/Documents/Medical/PAECCR\\_report\\_2018-19.pdf](https://www.paec.gov.pk/Documents/Medical/PAECCR_report_2018-19.pdf)
2. S. Zaheer, N. Shah, S. A. Maqbool, N.M. Soomro. Estimates of past and future time trends in age-specific breast cancer incidence among women in Karachi, Pakistan: 2004–2025. *BMC Public Health* 19, 1001 (2019). <https://doi.org/10.1186/s12889-019-7330-z>
3. Rufina Soomro, Salman Faridi, Nadeem Khurshaidi, et al. Age and stage of breast cancer in Pakistan: An experience at a tertiary care center. *JPMA*, November 2018, Volume 68, Issue 11
4. Khan NH, Duan SF, Wu DD, Ji XY. Better Reporting and Awareness Campaigns Needed for Breast Cancer in Pakistani Women. *Cancer Manag Res.* 2021; 13:2125-2129. Published 2021 Mar 2. doi:10.2147/CMAR.S270671
5. William Gradishar MD and Kilian E. Salerno MD. NCCN Guidelines Update: Breast Cancer, Volume 14: Issue 5S, Online Publication Date: May 2016 DOI: <https://doi.org/10.6004/jnccn.2016.0181>
6. R. Sarin, S. P. Somsekhar, R. Kumar, et al. Practical consensus recommendations for tumor margins

Citation: Dr. Rabia Ikram, "The Effectiveness of Multiple Metallic Clips in Terms of Margin Safety in Breast Conservation Surgery after Neoadjuvant Systemic Therapy" *MAR Oncology* Volume 5 Issue 4  
[www.medicalandresearch.com](http://www.medicalandresearch.com) (pg. 12)

and breast conservative surgery. *South Asian J Cancer*. 2018 Apr-Jun; 7(2): 72–78. doi: 10.4103/sajc.sajc\_105\_18

7. van Maaren MC, de Munck L, de Bock GH, et al. 10 year survival after breast-conserving surgery plus radiotherapy compared with mastectomy in early breast cancer in the Netherlands: a population-based study. *Lancet Oncol*. 2016;17(8):1158-1170. doi:10.1016/S1470-2045(16)30067-5

8. Del Turco MR, Ponti A, Bick U, et al. Quality indicators in breast cancer care. *Eur J Cancer*. 2010;46(13):2344-2356. doi:10.1016/j.ejca.2010.06.119

9. Smith I. Goals of Treatment for Patients with Metastatic Breast Cancer. *Semin Oncol*. 2006;33(Suppl 2):S2-S5. doi: 10.1053/j.seminoncol.2005.07.030

10. Cardoso F, Loibl S, Pagani O, et al. The European Society of Breast Cancer Specialists recommendations for the management of young women with breast cancer. *Eur J Cancer*. 2012;48(18):3355-3377. doi:10.1016/j.ejca.2012.10.004

11. Masroor I, Zeeshan S, Afzal S, et al. Outcome and Cost Effectiveness of Ultrasonographically Guided Surgical Clip Placement for Tumor Localization in Patients undergoing Neo-adjuvant Chemotherapy for Breast Cancer. *Asian Pac J Cancer Prev*. 2015;16(18):8339-8343. doi:10.7314/apjcp.2015.16.18.8339

12. Shalaby, L.A.S.E.D., Khallaf, E.S.e.d. & Moussa, M.M. Clip and wire localization of locally advanced malignant breast masses in patients undergoing neoadjuvant chemotherapy and breast conservation therapy. *Egypt J Radiol Nucl Med* 50, 96 (2019). <https://doi.org/10.1186/s43055-019-0066-z>

13. Goorts B, van Nijnatten TJ, de Munck L, et al. Clinical tumor stage is the most important predictor of pathological complete response rate after neoadjuvant chemotherapy in breast cancer patients. *Breast Cancer Res Treat*. 2017;163(1):83-91. doi:10.1007/s10549-017-4155-2

14. Consensus Guideline on Breast Cancer Lumpectomy Margins by American Society of Breast Surgeons. <https://www.breastsurgeons.org/docs/statements/Consensus-Guideline-on-Breast-Cancer-Lumpectomy-Margins.pdf>

15. Choi, J., Laws, A., Hu, J. et al. Margins in Breast-Conserving Surgery After Neoadjuvant Therapy. *Ann Surg Oncol* 25, 3541–3547 (2018). <https://doi.org/10.1245/s10434-018-6702-4>

16. Cen, C., Chun, J., Kaplowitz, E. et al. Margin Assessment and Re-excision Rates for Patients Who Have Neoadjuvant Chemotherapy and Breast-Conserving Surgery. *Ann Surg Oncol* 28, 5142–5148 (2021). <https://doi.org/10.1245/s10434-020-09524-0>

17. O'Kelly Priddy CM, Forte VA, Lang JE. The importance of surgical margins in breast cancer. *J Surg Oncol.* 2016;113(3):256-263. doi:10.1002/jso.24047
18. Early Breast Cancer Trialists' Collaborative Group (EBCTCG), Darby S, McGale P, et al. Effect of radiotherapy after breast-conserving surgery on 10-year recurrence and 15-year breast cancer death: meta-analysis of individual patient data for 10,801 women in 17 randomised trials. *Lancet.* 2011;378(9804):1707-1716. doi:10.1016/S0140-6736(11)61629-2
19. Yersal O, Barutca S. Biological subtypes of breast cancer: Prognostic and therapeutic implications. *World J Clin Oncol.* 2014;5(3):412-424. doi:10.5306/wjco.v5.i3.412
20. Patrizia Vici, et al, Triple positive breast cancer: A distinct subtype?, *Cancer Treatment Reviews*, Volume 41, Issue 2, 2015, Pages 69-76, ISSN 0305-7372, <https://doi.org/10.1016/j.ctrv.2014.12.005>. (<https://www.sciencedirect.com/science/article/pii/S0305737214002102>)
21. Iancu G, Vasile D, Iancu RC, DaviȚoiu DV. "Triple positive" breast cancer - a novel category?. *Rom J Morphol Embryol.* 2017;58(1):21-26.
22. Cho SY, Park SY, Bae YK, et al. Standardized Pathology Report for Breast Cancer. *J Breast Cancer.* 2021;24(1):1-21. doi:10.4048/jbc.2021.24.e5
23. Vos EL, Siesling S, Baaijens MHA, et al. Omitting re-excision for focally positive margins after breast-conserving surgery does not impair disease-free and overall survival. *Breast Cancer Res Treat.* 2017;164(1):157-167. doi:10.1007/s10549-017-4232-6
24. Anderson S. A Short History of Bernard Fisher's Contributions to Randomized Clinical Trials. *Clin Trials.* 2022;19(2):127-136. doi:10.1177/17407745211066498
25. Kayar R. The Spectrum Theory in Breast Cancer Is Controversial. *Eur J Breast Health.* 2017;13(4):219-220. Published 2017 Oct 1. doi:10.5152/ejbh.2017.3721
26. Gerber DE. Targeted therapies: a new generation of cancer treatments. *Am Fam Physician.* 2008;77(3):311-319.
27. Abdel-Razeq H, Marei L. Current neoadjuvant treatment options for HER2-positive breast cancer. *Biologics.* 2011;5:87-94. doi:10.2147/BTT.S22917
28. Zhang J, Sun M, Chang E, Lu CY, Chen HM, Wu SY. Pathologic response as predictor of recurrence, metastasis, and survival in breast cancer patients receiving neoadjuvant chemotherapy and total

mastectomy. *Am J Cancer Res.* 2020;10(10):3415-3427.

29. Volders, J.H., Negenborn, V.L., Spronk, P.E. et al. Breast-conserving surgery following neoadjuvant therapy-a systematic review on surgical outcomes. *Breast Cancer Res Treat* 168, 1–12 (2018). <https://doi.org/10.1007/s10549-017-4598-5>

30. Dash N, Chafin SH, Johnson RR, Contractor FM. Usefulness of tissue marker clips in patients undergoing neoadjuvant chemotherapy for breast cancer. *AJR Am J Roentgenol.* 1999;173(4):911-917. doi:10.2214/ajr.173.4.10511147

31. Ahmed H. Soliman, Ahmed M. Osman, Cost-effectiveness of ultrasound-guided surgical clips placement for breast cancer localization prior to neoadjuvant chemotherapy, *The Egyptian Journal of Radiology and Nuclear Medicine*, Volume 49, Issue 4, 2018, Pages 1163-1168, ISSN 0378-603X, <https://doi.org/10.1016/j.ejrm.2018.06.010>.

32. Shahzad R, Masood M, Shahid A, Mirza ZR, Cheema FE, Fatima I. Sonographically guided metallic clip placement for tumour localization in early breast cancer patients undergoing neoadjuvant chemotherapy. *J Pak Med Assoc.* 2019;69(10):1501-1504.

33. Burbank F, Forcier N. Tissue marking clip for stereotactic breast biopsy: initial placement accuracy, long-term stability, and usefulness as a guide for wire localization. *Radiology.* 1997;205(2):407-415. doi:10.1148/radiology.205.2.9356621

34. Oh JL, Nguyen G, Whitman GJ, et al. Placement of radiopaque clips for tumor localization in patients undergoing neoadjuvant chemotherapy and breast conservation therapy. *Cancer.* 2007;110(11):2420-2427. doi:10.1002/cncr.23068

35. Schulz-Wendtland R, Heywang-Köbrunner SH, Aichinger U, Krämer S, Wenkel E, Bautz W. Verbessert die Clipmarkierung im Rahmen der sonographischen oder stereotaktischen Brustbiopsie die Verlaufsbeurteilung kleiner Mammaläsionen und Lokalisation von Tumoren nach Chemotherapie? [Do tissue marker clips after sonographically or stereotactically guided breast biopsy improve follow-up of small breast lesions and localisation of breast cancer after chemotherapy?]. *Rofo.* 2002;174(5):620-624. doi:10.1055/s-2002-28278

36. Landercasper J, Linebarger JH. Contemporary breast imaging and concordance assessment: a surgical perspective. *Surg Clin North Am.* 2011;91(1):33-58. doi:10.1016/j.suc.2010.10.003

37. Wang-Lopez Q, Chalabi N, Abrial C, et al. Can pathologic complete response (pCR) be used as a

surrogate marker of survival after neoadjuvant therapy for breast cancer?. *Crit Rev Oncol Hematol.* 2015;95(1):88-104. doi:10.1016/j.critrevonc.2015.02.011

38. Pathology reporting of breast disease in surgical excision specimens incorporating the dataset for histological reporting of breast cancer by Royal College of Pathologist June 2016.

39. Schwartz GF, Veronesi U, Clough KB, et al. Proceedings of the Consensus Conference on Breast Conservation, April 28 to May 1, 2005, Milan, Italy. *Cancer.* 2006;107(2):242-250. doi:10.1002/cncr.21988

40. Landercasper J, Attai D, Atisha D, et al. Toolbox to Reduce Lumpectomy Reoperations and Improve Cosmetic Outcome in Breast Cancer Patients: The American Society of Breast Surgeons Consensus Conference. *Ann Surg Oncol.* 2015;22(10):3174-3183. doi:10.1245/s10434-015-4759-x

41. McEvoy MP, Landercasper J, Naik HR, Feldman S. Update of the American Society of Breast Surgeons Toolbox to address the lumpectomy reoperation epidemic. *Gland Surg.* 2018;7(6):536-553. doi:10.21037/gs.2018.11.03

42. Azu M, Abrahamse P, Katz SJ, Jagsi R, Morrow M. What is an adequate margin for breast-conserving surgery? Surgeon attitudes and correlates. *Ann Surg Oncol.* 2010;17(2):558-563. doi:10.1245/s10434-009-0765-1

43. Blair SL, Thompson K, Rococco J, Malcarne V, Beitsch PD, Ollila DW. Attaining negative margins in breast-conservation operations: is there a consensus among breast surgeons?. *J Am Coll Surg.* 2009;209(5):608-613. doi:10.1016/j.jamcollsurg.2009.07.026

44. Morrow M, Harris JR, Schnitt SJ. Surgical margins in lumpectomy for breast cancer--bigger is not better. *N Engl J Med.* 2012;367(1):79-82. doi:10.1056/NEJMs1202521

45. Pilewskie M, Morrow M. Margins in breast cancer: How much is enough?. *Cancer.* 2018;124(7):1335-1341. doi:10.1002/cncr.31221

46. Atzori, G.; Gipponi, M.; Cornacchia, C.; Diaz, R.; Sparavigna, M.; Gallo, M.; Ruelle, T.; Murelli, F.; Franchelli, S.; Depaoli, F.; Friedman, D.; Fregatti, P. "No Ink on Tumor" in Breast-Conserving Surgery after Neoadjuvant Chemotherapy. *J. Pers. Med.* 2022, 12, 1031. <https://doi.org/10.3390/jpm12071031>

47. Houssami N, Macaskill P, Marinovich ML, et al. Meta-analysis of the impact of surgical margins on local recurrence in women with early-stage invasive breast cancer treated with breast-conserving therapy.



Eur J Cancer. 2010;46(18):3219-3232. doi:10.1016/j.ejca.2010.07.043

48. Dunne C, Burke JP, Morrow M, Kell MR. Effect of margin status on local recurrence after breast conservation and radiation therapy for ductal carcinoma in situ. *J Clin Oncol*. 2009;27(10):1615-1620. doi:10.1200/JCO.2008.17.5182

49. McCahill LE, Single RM, Aiello Bowles EJ, et al. Variability in Reexcision Following Breast Conservation Surgery. *JAMA*. 2012;307(5):467-475. doi:10.1001/jama.2012.43

50. Dignam JJ, Dukic V, Anderson SJ, Mamounas EP, Wickerham DL, Wolmark N. Hazard of recurrence and adjuvant treatment effects over time in lymph node-negative breast cancer. *Breast Cancer Res Treat*. 2009;116(3):595-602. doi:10.1007/s10549-008-0200-5

51. Aiello Bowles EJ, Feigelson HS, Barney T, et al. Improving quality of breast cancer surgery through development of a national breast cancer surgical outcomes (BRCASO) research database. *BMC Cancer*. 2012;12:136. Published 2012 Apr 3. doi:10.1186/1471-2407-12-136

52. Buchholz TA, Somerfield MR, Griggs JJ, et al. Margins for breast-conserving surgery with whole-breast irradiation in stage I and II invasive breast cancer: American Society of Clinical Oncology endorsement of the Society of Surgical Oncology/American Society for Radiation Oncology consensus guideline. *J Clin Oncol*. 2014;32(14):1502-1506. doi:10.1200/JCO.2014.55.

53. Smith TJ, Landercasper J, Gundrum JD, et al. Perioperative quality metrics for one step breast cancer surgery: a patient-centered approach. *J Surg Oncol*. 2010;102(1):34-38. doi:10.1002/jso.21555

54. L Landercasper, Jeffrey. (2012). Variability in Reexcision Following Breast Conservation Surgery. *Breast Diseases: A Year Book Quarterly*. 23. 385-387. 10.1016/j.breastdis.2012.09.001.

55. Mook J, Klein R, Kobbermann A, et al. Volume of excision and cosmesis with routine cavity shave margins technique. *Ann Surg Oncol*. 2012;19:886-

891. Epub 2011 Aug 12. doi: 10.1245/s10434-011-1982-y.

56. Jeevan R, Cromwell DA, Trivella M. Reoperation rates after breast conserving surgery for breast cancer among women in England: retrospective study of hospital episode statistics.

*BMJ*. 2012; 345:e4505. E pub 2012 Jul 12. doi: <http://dx.doi.org/10.1136/bmj.e4505>

57. Atkins J, Al Mushawah F, Appleton CM, et al. Positive margin rates following breast-conserving surgery for stage I-III breast cancer: palpable versus nonpalpable tumors. *J Surg Res*. 2012;177(1):109-

115. doi:10.1016/j.jss.2012.03.045

58. Bundred JR, Michael S, Stuart B, et al. Margin status and survival outcomes after breast cancer conservation surgery: prospectively registered systematic review and meta-analysis. *BMJ*. 2022;378:e070346. Published 2022 Sep 21. doi:10.1136/bmj-2022-070346

59. Wj H, As E, Js R, C P, Dh B. Rates of margin positive resection with breast conservation for invasive breast cancer using the NCDB. *Breast*. 2021;60:86-89. doi:10.1016/j.breast.2021.08.012

60. National Comprehensive Cancer Network Guidelines Version 2.2022 Invasive Breast Cancer: Margin Status in infiltrating carcinoma. 2022; BINV-F. Available [with login] at: [http://www.nccn.org/professionals/physician\\_gls/pdf/breast.pdf](http://www.nccn.org/professionals/physician_gls/pdf/breast.pdf) .

61. Saeed, S., Asim, M. & Sohail, M.M. Fears and barriers: problems in breast cancer diagnosis and treatment in Pakistan. *BMC Women's Health* 21, 151 (2021). <https://doi.org/10.1186/s12905-021-01293-6>

62. Mazor AM, Mateo AM, Demora L, et al. Breast conservation versus mastectomy in patients with T3 breast cancers (> 5 cm): an analysis of 37,268 patients from the National Cancer Database. *Breast Cancer Res Treat*. 2019;173(2):301-311. doi:10.1007/s10549-018-5007-4

63. Bleicher RJ, Ruth K, Sigurdson ER, et al. Breast conservation versus mastectomy for patients with T3 primary tumors (>5 cm): A review of 5685 medicare patients. *Cancer*. 2016;122(1):42-49. doi:10.1002/cncr.29726